

## Cystic Angiomatous Meningioma: A Rare Case Report and Literature Review

Maick Willen Fernandes Neves<sup>1\*</sup>, Mariana Mazzuia Guimaraes<sup>1</sup>, João Flavio Mattos de Araújo<sup>1</sup>, Wolnei Zeviani Marques<sup>1</sup>, Telmo Augusto Barba Belsuzarri<sup>1</sup>, Renata de Melo Braga Marques<sup>2</sup>, André Monteiro Soares de Araujo<sup>3</sup> and Paulo Henrique Pires de Aguiar<sup>4</sup>

<sup>1</sup>Department of Neurosurgery, Hospital Celso Pierro, Pontifical Catholic University of Campinas, Campinas, São Paulo, Brazil

<sup>2</sup>Centro de Atenção Integral à Saúde da Mulher (Caism), State University of Campinas(Unicamp), Campinas, São Paulo, Brazil

<sup>3</sup>Medical Student, Department of Neurosurgery, Pontifical Catholic University of Campinas, Campinas, São Paulo, Brazil

<sup>4</sup>Department of Neurosurgery, Pontifical Catholic University of Sorocaba, Sorocaba, São Paulo, Brazil

**\*Corresponding Author:** Maick Willen Fernandes Neves, Medical Resident, Department of Neurosurgery, Hospital Celso Pierro, Pontifical Catholic University of Campinas, Campinas, São Paulo, Brazil.

**Received:** December 13, 2017; **Published:** February 15, 2018

**DOI:** 10.31080/ecne.2018.10.00301

### Abstract

**Purpose:** Meningiomas are tumors derived from the arachnoidal cells and constitute about 20% of all intracranial tumors. Angiomatous meningioma is a rare variant of meningioma with few distinctive clinical, radiological and histopathological features and should be considered in the differential diagnosis of highly vascularized brain tumors.

**Case Report:** We report a clinical case of a 75-year-old male who presented with persistent headache and cognitive changes. Imaging showed heterogeneous tumor in the right occipital region with heterogeneous contrast enhancement and a cystic component. Edema and mass effect were also present. The tumor was excised and histologically described as angiomatous meningioma, demonstrating predominance of small and medium-sized vessels in the neoplasm. Postoperatively, there was a fast recovery of neurological level and the patient was discharged from the hospital without neurological deficits.

**Conclusion:** Angiomatous meningioma is a rare variant of meningioma with few distinctive clinical, radiological and histopathological features and should be considered in the differential diagnosis of highly vascularized brain tumors.

**Keywords:** Meningioma; Angiomatous Meningioma; Vascular Brain Tumors; Haemangiopericytoma; Haemangioblastoma

### Introduction

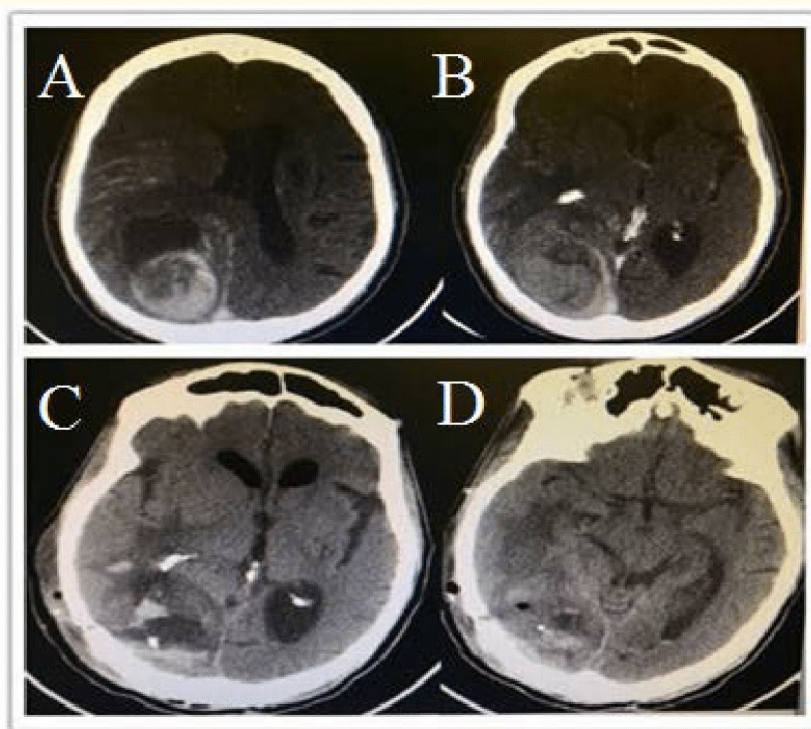
Meningiomas are tumors derived from the arachnoidal, cap cells, which are present in arachnoidal villi, granulations and in the stroma of perivascular spaces and choroid plexus. In adults, it has a predominance of female (3:1) and black non-hispanic ethnicity, annual incidence of about 4,5 per 100000 individuals, clinically evident in a mean age of 65 years old and only rarely occur during childhood [1,2]. They account for approximately 13% to 19% of intracranial tumors and one-fourth of intraspinal tumors, presenting cystic characteristics in 0,7% to 11,7% of cases [3-8]. Numerous variants of meningiomas are described, reflecting the mesenchymal and epithelial histogenetic potential of arachnoidal cells, being the meningothelomatous histology the most common type [7,8]. The angiomatous meningioma is a rare histological type, more common in males (14:13), with a mean age of 51.8 (ranging from 24 to 72), comprising 2,1% of all meningiomas and classified as WHO (World Health Organization) grade I, it presents as cystic meningioma in 14,8% of cases and has a silent tumoral growth, low proliferation and infiltration rate [9,10]. These tumors are composed mainly by vessels and usually have no signs of atypia and anaplasia, maintaining the histological structure, and it has a predilection by the cerebral convexity [5,6,11].

## Case Report

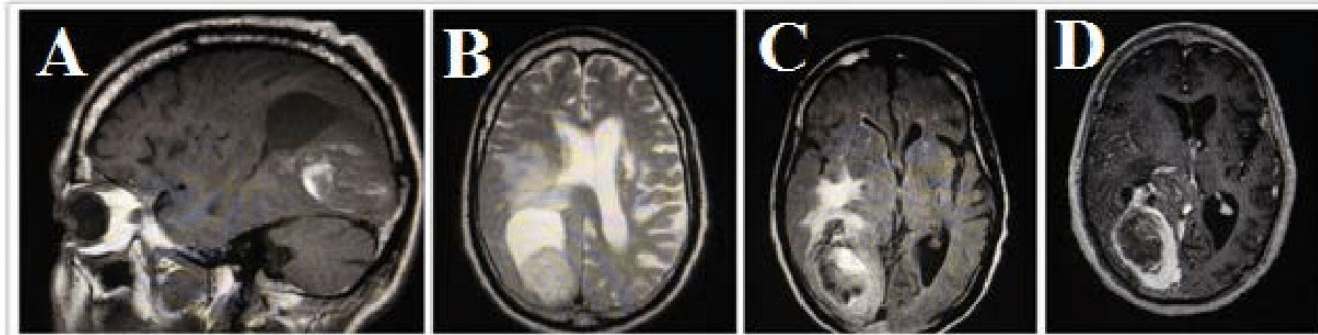
Our patient is a 75-year-old male, who came to our hospital with persistent headache and cognitive changes. His complaints began 15 days earlier with progressive right sided headache and frequent forgetfulness. At the neurological examination, he was confused, disoriented to time and presented bilateral papilledema.

The performed brain CT showed a heterogeneous tumor in the right occipital region, approximately 6 cm<sup>3</sup> (6,7 x 5 x 3,2 cm AP, CC e LL) and heterogeneous contrast enhancement. Adjacent to the lesion there was a cyst and a hyperdense area compatible with bleeding density. The image also showed perilesional hypodensity suggestive of vasogenic edema, slight right ventricle compression, midline deviation of 0.8 mm to the left, with deletion of right sulci and gyri (Figure 1a and 1b). On T1-weighted MRI, the mass appeared hypointense, with heterogeneous contrast enhancement (Figure 2A and 2D), while on T2-weighted MRI, it appeared hyperintense, with heterogeneous contrast enhancement and a cystic component (Figure 2B). Edema and mass effect were also present (Figure 2c).

The patient underwent craniotomy for tumor resection without intraoperative complications. During surgery, the tumor was flesh-colored and exhibited intra-lesional areas of hemorrhage, soft texture, thin capsule and clear limits without brain invasion. Complete resection was achieved. After surgical procedure, the patient remained in altered state of consciousness, but presented headache improvement, no additional neurological deficits and a post-operative CT scan was performed (Figure 1c and 1d).

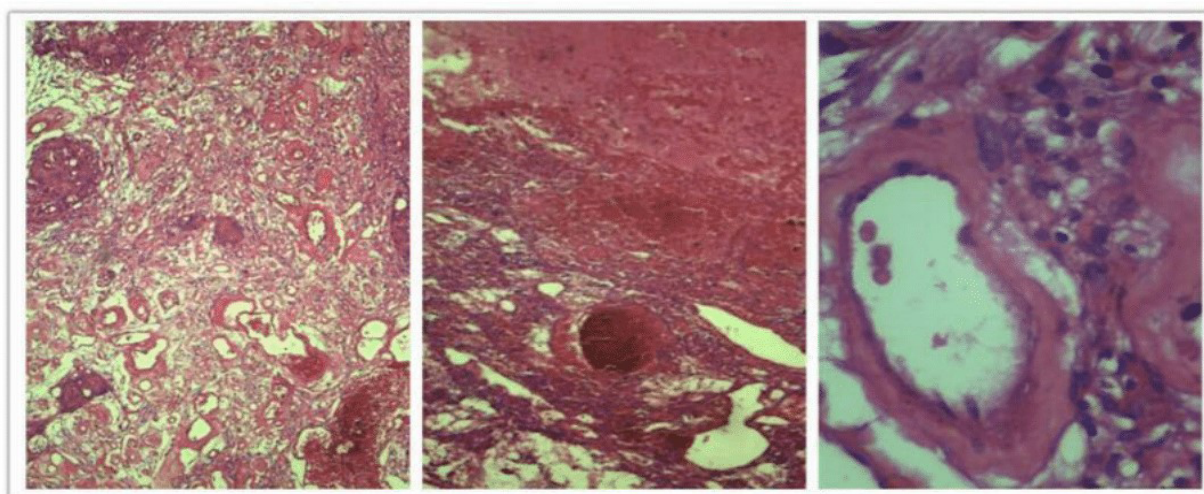


**Figure 1:** Axial Computerized Tomography (CT). A and B: CT scan in axial cut showing heterogeneous occipital lesion. C and D: CT scan in axial cut postoperative images.



**Figure 2:** A: Sagittal T1-weighted MRI with contrast, showing expansive lesion at the occipital region; B Axial T2-weighted MRI showing a solid-cystic lesion and mass effect. C Axial MRI, FLAIR incidence, showing perilesional edema. D Axial T1-weighted MRI with contrast showing heterogeneous enhancement, specially at the peripheral region.

The tumor was histologically described as angiomatous meningioma, presenting predominance of small and medium-sized vessels of the neoplastic cells, which were thick and hyalinized by excessive collagen fiber deposition (Figure 3). The patient is currently asymptomatic and without signs of recurrence on a 12-month follow-up.



**Figure 3:** Meningeothelial cells wrapped around small blood vessels, with vascular component exceeding 50% of total tumor area. Presence of hemorrhagic areas.

## Discussion

Angiomatous meningiomas have the histological and clinical features of benign meningeal tumors, in which the blood vessels components exceed 50% [4,10]. Despite this characteristics strongly suggests the diagnosis, it can only be confirmed by immunohistochemistry, in which can be find positivity for EMA, cytokeratin and progesterone, with a proliferation index MIB/KI67 of 2,4% [9,11]. The clinical

manifestations of an angiomatous meningioma usually involves headache, transient loss of consciousness, seizures, nausea, vomiting, fecal incontinence, facial hypoesthesia, tinnitus and deafness, hoarseness, papilledema, unilateral limb paresis, visual impairment, sluggish corneal reflex, flat nasolabial fold, unilateral limb spasticity, ataxia, positive Babinski sign and chewing muscle weakness [10]. In the reported case, the patient presented not only hemicranial headache and bilateral papilledema, but also forgetfulness, confusion and time disorientation, which makes this case rare, once cognitive alterations are uncommon in slow growing tumors. Most common signs and symptoms are (Table 1).

Headache, dizziness	55%
Transient loss of consciousness	33,3%
Seizures	25,9%
Nauseas, vomiting	18,5%
Papilledema	18,5%
Fecal incontinence	11,1%
Unilateral limb paresis	11,1%
Visual Impairment	7,4%

**Table 1:** Frequency of signs and symptoms.

Angiomatous meningiomas have some distinct radiographic features. They are usually dural based and located over the convexity. On CT scans, tumors display high contrast enhancement, along with a disproportionate peritumoral edema. Since blood vessels are significantly present, signs of bleeding within the tumor mass can appear. On MRA, angiomatous meningioma also shows as isointense or hyperintense compared to the brain cortex and seems to have more blood flow void shadow in the tumor [9]. Imaging techniques such as MRI and CT help to establish diagnosis with an accuracy rate of 80% e 50%, respectively [8]. On MRI, 48,1% of lesions are 3 to 5 cm in size and 66,7% are located at the convexity, usually with no signs of calcification, but moderate to severe edema is found in 88,9%. Oval shape is present in 81,5%, flow void sign in 100% and homogeneous presentation in 85,2% [8].

Cystic meningiomas are frequently aggressive, likely due to tumor necrosis, hemorrhage or neoplastic cell secretion [5,8,10,12]. The cystic classification defines three different variants for meningotheliomatous type based on MRI: cystic region not related to the tumor; cystic region at the surrounding area of the tumor but not continuous to it, and cystic region at the surrounding area continuous to it, with respective frequencies of 40%, 33% and 27% [8].

Rengachary, *et al.* classified cysts as intratumoral and extratumoral [13]. Nauta, *et al.* classify them in 4 types: intratumoral (I), peritumoral with (II) or without (III) contact to the tumor and at the brain-tumor interface(IV) [5]. Jung, *et al.* added a fifth type, a combination of types I and III. El-fiki, *et al.* related the location of the cyst to its content (Table 2) [12]. In the reported case, it was found a xanthochromic fluid contained by a thin capsule that made contact to the tumor but did not invade it.

Type	Content		Location
A	Clearfluidor CSF	A1	Extratumoral. CSF contained by arachnoid membrane.
		A2	Extratumoral, clear fluid not contained by arachnoid membrane
B	Xanthochromic	B1	Extratumoral, without cyst wall.
		B2	Intratumoral, thin portion surrounded by cystic tumor or nodule
C	Brown or dark yellow colored fluid		Intratumoral
D	Clear content, peritumoral cyst or extratumoral and small intratumoral brown cyst		

**Table 2:** El-fikiclassification.

When it comes to location, this kind of tumor usually appears over the convexity and a higher degree of peritumoral edema is observed very often. Because of high vascularity, it displays intense contrast enhancement and a significant peritumoral edema on Computerized Tomography (CT) scan. On Magnetic Resonance Imaging (MRI), a dural based mass shows homogeneous enhancement, precious blood flow void shadow and peritumoral edema [9,10,14]. Some factors are directly associated to peritumoral edema in meningiomas: venous obstruction, pial-meningeal anastomosis, increased capillary permeability, sexual hormones/receptors and vascular endothelial growth factor(VEGF) secretion, the latter being the main factor [6,15,16]. Also, other frequent factors involved are mast cells, hypoxia induction factor 1, aquaporine 4(AQP4), metalloproteinase 9(MMP), interleukine 6 (IL-6) [16]. The presence of edema is highly related to prognosis, since VEGF can be produced in high amounts by mast cells, specially in case of high grade meningiomas [17].

The peritumoral classification on imaging techniques was described by Steinhoff, *et al.* in 1975 and later related to mast cells and hypoxia induction factor 1(HIF1) by Joanna Reszec [18]. The edema is classified in 4 grades: absent (grade 0), peritumoral edema smaller than 2cm(grade 1), peritumoral edema limited to the ipsilateral hemisphere (grade 2) and peritumoral edema invading the contralateral hemisphere (grade 3) [17].

In terms of chromosomal alterations, angiomatous meningioma has a different pattern from other grade I meningiomas, characterized by numerous chromosomal polysomies and absence of mutations usually found in other meningioma subtypes [19]. While typical grade I meningiomas demonstrate monosomy of chromosome 22 or lack copy number aberrations, angiomatous meningioma presents polysomies of at least one chromosome, but often multiple, especially in chromosomes 5, 13 and 20 [19].

Differential diagnosis for supratentorial solid-cystic lesions includes gliomas, meningiomas and metastatic tumors, while for infratentorial location it includes hemangioblastomas and schwannomas with degenerated cysts in adults, with the pylocytic astrocytoma being included for pediatric patients [12,14].

Haemangiopericytoma and haemangioblastoma, called angioblastic meningiomas, highly vascular intraparenchymal brain tumors, are also rare and comprise differential diagnosis for angiomatous meningioma, so it should be investigated because of associated syndromes and different outcomes, respectively [20,21]. Recurrence is directly associated to the Simpson resection grade, with the respective rates for I, II, III and IV being 5%, 22%,31% and 35%.6 In our case report, we obtained a gross total resection(GTR) and observed no recurrence, confirming this as the gold standard treatment for angiomatous meningioma [9]. Nevertheless, post-operative radiotherapy may help patients with residual tumor. Angiomatous meningiomas belong to WHO grade I and has a favorable outcome when the surgical resection is complete.

The present case describes the location and radiological presentation of angiomatous meningioma and highlights the fact that making this diagnosis preoperatively is challenging and arduous. CT and MRI findings of angiomatous meningiomas can be nonspecific. Therefore, correlation of clinical, radiological, histopathological and immunohistochemical findings are always required to reach a particular diagnosis.

### Conclusion

In conclusion, we may say that angiomatous meningioma is a rare variant of meningioma with few distinctive clinical, radiological and histopathological features. Despite the uncommon histological type, our patient also presented cognitive changes that were not previously reported in literature. The differential diagnosis includes other highly vascular neoplasms such as hemangiopericytoma and sometimes it is hard to specify the correct diagnosis even with a combination of clinical, histopathological, immunohistochemical and neuroimaging methods. According to what was reported, we believe this case to be a contribution for greater knowledge about this disease.

## Financial Support and Sponsorship

Nil.

## Conflicts of Interest

There are no conflicts of interest.

## Bibliography

1. QT Ostrom, *et al.* "CBTRUS Statistical Report: Primary Brain and Central Nervous System Tumors Diagnosed in the United States in 2008-2012". *Neuro-Oncology* 17.4 (2015): 1-62.
2. Wiemels J, *et al.* "Epidemiology and etiology of meningioma". *Journal of Neuro-Oncology* 99.3 (2010): 307-314.
3. Bansal D, *et al.* "Intraparenchymal Angiomatous Meningioma: A diagnostic Dilemma". *Journal of Clinical and Diagnostic Research* 9.10 (2015): ED07-ED08.
4. Chaushev N, *et al.* "A case report of angiomatous meningioma". *Journal of Clinical Medicine* 3.3 (2010): 60-63.
5. Deb P, *et al.* "Cystic angiomatous meningioma in the cerebellopontine angle mimicking hemangioblastoma". *Journal of Cancer Research and Therapeutics* 6.4 (2010): 560-563.
6. Hwang J, *et al.* "Clinical and Radiological Characteristics of Angiomatous Meningiomas". *Brain Tumor Research and Treatment* 4.2 (2016): 94-99.
7. Whittle IR, *et al.* "Meningiomas". *Lancet* 363.9420 (2004): 1535-1543.
8. Zee CS, *et al.* "Magnetic Resonance Imaging of Cystic Meningiomas and Its Surgical Implications". *Neurosurgery* 36.3 (1995): 482-488.
9. Hasselblatt M, *et al.* "Angiomatous Meningioma: A Clinicopathologic Study of 38 Cases". *American Journal of Surgical Pathology* 28.3 (2004): 390-393.
10. Liu Z, *et al.* "Clinical characteristics and treatment of angiomatous meningiomas: a report of 27 cases". *International Journal of Clinical and Experimental Pathology* 6.4 (2013): 695-702.
11. Bodla AA, *et al.* "Meningioma of Orbit Mimicking as Malignant Neoplasm: A Case Report and Literature Review". *Orbit* 30.4 (2011): 183-185.
12. Sotiriadis C, *et al.* "Cystic meningioma: diagnostic difficulties and utility of MRI in diagnosis and management". *BMJ Case Reports* (2015).
13. Wasenko JJ, *et al.* "Cystic Meningiomas: MR Characteristics and Surgical Correlations". *American Journal of Neuroradiology* 15.10 (1994): 1959-1965.
14. Bansal S, *et al.* "Cystic Angiomatous Meningioma: A diagnostic dilemma". *Indian Journal of Neurosurgery* 5 (2016): 106-109.
15. Dietzmann K, *et al.* "Immunohistochemical detection of vascular growth factors in angiomatous and atypical meningiomas, as well as hemangiopericytomas". *Pathology, Research and Practice* 193.7 (1997): 503-510.
16. Shibuya M. "Pathology and Molecular Genetics of Meningiomas: Recent Advances". *Neurologia Medico-Chirurgica* 55.1 (2015): 14-27.
17. Polyzoidis S, *et al.* "Mast cells in meningioma and brain inflammation". *Journal of Neuroinflammation* 12 (2015): 170.

18. Reszec J., *et al.* "Mast cells evaluation in meningioma of various grades". *Folia Histochemica et Cytobiologica* 50.4 (2012): 542-546.
19. Abedalthagafi MS. "Angiomatous meningiomas have a distinct genetic profile with multiple chromosomal polysomies including polysomy of chromosome 5". *Oncotarget* 5.21 (2014): 10596-10606.
20. Ding D and Sheehan JP. "Intracranial Hemangiopericytomas: A Wolf in Sheep's Clothing". *World Neurosurgery* 82.7-8 (2014): e185-e186.
21. Meng Y., *et al.* "Preoperative radiologic characters to predict hemangiopericytoma from angiomatous meningioma". *Clinical Neurology and Neurosurgery* 138.8 (2015): 78-82.

**Volume 10 Issue 3 March 2018**

**© All rights reserved by Maick Willen Fernandes Neves., *et al.***