

## Evaluation of Minimally Invasive Esophagectomy

**Khalaf Mohammed Khalaf Alsayyali<sup>1\*</sup>, Mashel Khalid Alhawish<sup>2</sup>, Jawad Abdullah Ali Aldhafeeri<sup>3</sup>, Ahmad Salem Farj Alharbi<sup>4</sup>, Suliman Abdullah Assiri<sup>5</sup>, Mezzher Mohammad Ali Alsaeed<sup>6</sup>, Alshinqiti Nusiba Abdulrahman A<sup>4</sup>, Nazer, Raef Waleed M<sup>7</sup>, Abdulrahman Salah Almas<sup>8</sup>, Abdullatif Abdulaziz Bin Khunayn<sup>2</sup>, Abdulmalik Abdulaziz Abdullatif Bin Khunayn<sup>2</sup>, Dhafer Abdullah Abdulhadi Alshehri<sup>1</sup>, Abdulaziz Ibrahim Alhuthayli<sup>8</sup>, Maha Hussain Alhainiah<sup>9</sup>, Mazen Abdullah S Alzaedi<sup>10</sup> and Mohammed Yahya H Al Jamahir<sup>11</sup>**

<sup>1</sup>Prince Sattam Bin Abdulaziz University, Al-Kharj, Saudi Arabia

<sup>2</sup>Almaarefa Colleges, Riyadh, Saudi Arabia

<sup>3</sup>University of Groningen, Groningen, Netherlands

<sup>4</sup>Taibah University, Medina, Saudi Arabia

<sup>5</sup>Armed Forces Hospital Southern Region, Saudi Arabia

<sup>6</sup>Maternity and Children's Hospital Dammam, Dammam, Saudi Arabia

<sup>7</sup>Batterjee Medical College, Jeddah, Saudi Arabia

<sup>8</sup>King Faisal University, Hofuf, Saudi Arabia

<sup>9</sup>King Abdulaziz University, Jeddah, Saudi Arabia

<sup>10</sup>Taif University, Taif, Saudi Arabia

<sup>11</sup>Medical University of Gdansk, Gdańsk, Poland

**\*Corresponding Author:** Khalaf Mohammed Khalaf Alsayyali, Prince Sattam Bin Abdulaziz University, Al-Kharj, Saudi Arabia.

**Received:** August 24, 2017; **Published:** August 28, 2017

### Abstract

Esophageal cancer is the eighth most common malignancy and the sixth most common cause of cancer-related death worldwide. Esophagectomy delivers a curative treatment but carries significant morbidity and mortality. Minimally invasive esophagectomy (MIE) was defined as an effort to decrease operative morbidity. From that point forward numerous establishments have embraced and depicted their arrangement with this technique. This paper reviews the literature on the variety of MIE techniques, clinical and quality of life outcomes with MIE.

**Keywords:** Esophageal Cancer; Minimally Invasive Esophagectomy; MIE Techniques

### Introduction

Esophagectomy for benign or malignant ailment is a complex operation with significant morbidity and mortality. The five-year survival rate has been presented to be 19% to 46.5%, with a reconnaissance program and expanded recognition of early-stage esophageal cancer [1,2]. Notwithstanding these survival rates, Orringer, et al. set the standard for postoperative results with their described series of 1,085 patients who experienced open transhiatal esophagectomy from 1976 to 1998 with a hospital mortality and morbidity rate of 4% and 13%, respectively [3]. lately, they published an updated series of 2,007 patients who had a related hospital mortality rate of 1%, anastomotic leak rate of 9%, pneumonia rate of 2%, and intrathoracic hemorrhage, recurrent laryngeal nerve paralysis, chylothorax, and tracheal laceration rates of < 1% each [4]. With an end goal to decrease the morbidity of esophagectomy, minimally invasive methods began to be progressively applied in the 1990s. In 1998, Luketich, et al. revealed their underlying knowledge on 8 patients who experienced minimally invasive esophagectomy (MIE) using either laparoscopic and/or thoracoscopic techniques. They had no perioperative mortalities and one cervical anastomotic leak, hence exhibiting the potential safety and achievability of minimally invasive esophagectomy [5].

From that point forward, numerous establishments have detailed their encounters in the adoption and improvement of MIE for benign and malignant diseases of the esophagus. Henceforth, this paper abridges the literature to date, including both bigger single organization arrangement on MIE and furthermore review and forthcoming examinations of open versus MIE, and addresses the different lessons educated and discussions encompassing MIE.

### Minimally Invasive Esophagectomy Outcomes

As of now, no institutionalized contraindications exist in regards to the utilization of MIE. In any case, T4 sores (invasion of surrounding tissues) are for the most part not responsive to any type of surgical resection. Broad nodal malady and metastatic infection are likewise cutting-edge arranges that may require an open surgical approach or even endoscopic stenting for concealment rather than an endeavor at MIE [6]. Furthermore, any patient with a lesion that bridges the esophagogastric junction may not be viewed as a possibility for this approach unless the gastric edge can be cleared and an esophagogastrectomy should be possible either by means of open approach or minimally invasively. Similarly as with other laparoscopic methods, patients with extensive adhesions and scar tissue over the abdomen or chest wall, especially in territories where the thoracoscope or laparoscope would be set, are a higher hazard aggregate for treatment with MIE. More seasoned patients and those with comorbid conditions are not contender for surgery, as a result of the high horribleness with either a MIE or a standard method, yet they may profit more from nonsurgical treatment [7].

Luketich, one of the prior pioneers of MIE, revealed his broad experience from 1996 to 2002 on 222 patients who experienced MIE for either high-level dysplasia (n = 47) or obtrusive tumor (n = 175). MIE was effectively finished in 206 (92.8%) patients. Agent mortality was 1.4%. Horribleness included anastomotic break rate of 11.7%, pneumonia occurrence of 7.7%, and repetitive laryngeal nerve damage with vocal rope paralysis rate of 3.6% [7]. Their favoured and most normally utilized approach is joined right thoracoscopic and laparoscopic THE. On the off chance that noteworthy gastric expansion of the tumor is experienced, they like to resect more stomach and play out an intrathoracic anastomosis that is negligibly obtrusive ILE. A similar gathering later portrayed their initial involvement with negligibly intrusive ILE in 50 patients from 2002 to 2005 with an agent mortality and leak rate of 6% each [8].

Rajan, *et al.* additionally distributed an extensive arrangement of 463 patients in India who experienced insignificantly obtrusive esophagectomy from 1997 to 2009. Strangely, 71 percent of patients had squamous cell carcinoma, and 29% had adenocarcinoma of the throat. Agent mortality was 0.9%, and general horribleness was 16% [9]. Additionally, Nguyen and partners detailed a progression of 104 MIE methods performed in the vicinity of 1998 and 2007. Most strategies were insignificantly obtrusive THE or ILE (98 of 104) using a roundabout staple method.

Main complication rate was 12.5%, and minor confusion rate was 15.4%. Anastomotic leak rate was 9.6%, and agent mortality was 2.9% [10]. Subsequently, we detailed our outcomes in 105 successive patients who experienced MIE using a side-to-side 6 cm direct stapled system from August 2007 to January 2011. Our mortality was 1% (1/105), and dismalness included 7% transient left repetitive laryngeal nerve damage, 9% pneumonia, 1% wound contamination, and 4% anastomotic leak rate [11]. In a different report, we contemplated the impact of neoadjuvant chemoradiation on results after MIE and noticed that there were no critical contrasts in agent blood misfortune, middle agent time, aggregate or individual complexity rates, pneumonia, atrial fibrillation, intermittent laryngeal nerve damage, or anastomotic leaks between patients who got neoadjuvant chemoradiation and patients who did not [12]. At last, because of the closeness of our Veterans Administration Hospital to the University Hospital, we could exhibit the attainability of a MIE program at the Veterans Hospital in our underlying arrangement of 18 back to back MIE. There was one (5.6%) 30-day mortality, 1 (5.6%) anastomotic leak, and 3 (16.7%) postoperative pneumonias [13].

In 2007, Gemmill and McCulloch published one of the prior systematic reviews of minimally invasive operations for esophageal and gastric cancer centred on an electronic search of the literature from 1997 to 2007. From 188 abstracts reviewed, 23 articles were found on minimally invasive esophagectomies (n = 1398)-the operations spanning any combination of thoracoscopy or thoracotomy with lapa-

roscopy, hand-assisted laparoscopy, or laparotomy (i.e., MIE or hybrid MIE). Twenty-one of the 23 were case studies, and the remaining 2 were case-matched studies; there were no randomized controlled studies of open versus MIE at the time of this systematic review. For MIE or hybrid MIE, 30-day mortality was 2.3%, combined major and minor morbidity was 46.2%, anastomotic leak rate was 7.7%, and respiratory tract infection rate was 13.2%. The authors specified that whereas there appears to be substantial literature advising the feasibility and safety of minimally invasive surgery for esophageal cancer, the quality of the studies was poor [14] Flaws included:

- The predominance of case series-low levels of evidence.
- Lack of valid direct comparisons of open versus MIE.
- Heterogeneity of the studies with regard to the type of MIE or hybrid MIE and, thus, lack of generalizability.
- Selection bias-patients selected for minimally invasive surgery are unlikely to have been representative of the general population of esophageal cancer patients (i.e. earlier stage, smaller tumors, and/or less co-morbid).
- Publication bias-surgeons with unsatisfactory results may have been less inclined to publish their data. Hence, the authors suggested a prospective nonrandomized cooperative study by surgeons interested in first establishing a consensus on both the appropriate question and the appropriate procedure to be tested against open esophagectomy.

The study would permit for evaluation of learning curves, power calculations based on witnessed treatment effect, and improvement of quality measures; the study would consequently serve as a significant and less costly preliminary step before a randomized controlled trial.

Verhage, *et al.* published their results of a systematic review involving 10 case-control studies comparing open to MIE. Blood loss for MIE (compared to open esophagectomy) was consistently lower in all studies, although hospital and ICU length of stay, overall complication rate, and pulmonary complications were expressively lower with MIE in most studies [15]. This paper was limited by the heterogeneity of the studies in respect to technique of MIE and both selection and publication bias. A meta-analysis by Nagpal, *et al.* involving 12 studies comparing open esophagectomy (n = 612) and MIE or hybrid MIE (n = 672), concluded similar results as distinguished by Verhage's group. There were no significant differences in 30-day mortality or anastomotic leak rates. Blood loss, ICU length of stay, whole hospital stay, and total morbidity were expressively lower in the MIE group [16].

Finally, a huge United Kingdom population-based study by Mamidanna, *et al.* analyzed the Hospital Episode Statistics data from April 2005 to March 2010 and involved 7,502 esophagectomies, 1,155 (15.4%) of which were MIE-with marked growth in the proportion of MIE (24.7%) implemented from 2009 - 2010. There was no variance between open and MIE groups, correspondingly, in 30-day mortality (4.3% versus 4.0%) and overall morbidity (38.0% versus 39.2%). Reintervention rate was higher with MIE compared to open (21% versus 17.6%, P = 0.006) [17]. Notwithstanding the apparent equipoise in outcomes between open and MIE in the above study, there were significant limits of this population-based study based on an administrative database, as mentioned in editorials by Pennathur and Luketich [18].

As with numerous new processes, the early publications concerning minimally invasive esophagectomy were commonly institutional series. Outcomes from these institutional series included anastomotic leak rates of 4% to 11.7%, pneumonia rates of 7.7% to 16.7%, major morbidity rates of 12.5% to 23%, and operative mortality rates of 0.9% to 6% (Table 1).

Study	N	Type	Leak	Pneumonia	RLN injury	Morbidity	Mortality
Institutional series							
Luketich., <i>et al.</i> [7]	206	MIE	11.70%	7.70%	3.60%	-	1.40%
Bizekis., <i>et al.</i> [8]	50	MIE	6%	-	-	-	6%
Rajan., <i>et al.</i> [9]	463	MIE	-	-	-	16%	0.90%
Nguyen., <i>et al.</i> [10]	104	MIE	9.60%	-	-	12.50%	2.90%
Ben-David., <i>et al.</i> [11]	105	MIE	4%	9%	7%	-	1%
Ben-David., <i>et al.</i> [12]	18	MIE	5.60%	16.70%	-	-	5.60%
Systematic reviews or meta-analyses							
Gemmill and McCulloch [14]	1398	MIE	7.70%	13.20%		46.20%	2.30%
Verhage., <i>et al.</i> [15]	-	Open		22.90%		60.40%	3.80%
(10 case-control studies)	-	MIE		15.10%		43.80%	1.30%
Nagpal., <i>et al.</i> [16]	612	Open	No difference				No difference
(1 randomized controlled trial and 9 case-control studies)							
Mamidanna., <i>et al.</i> [17]	6347	Open				39.20%	4%
	1155	MIE				38%	4.30%

**Table 1:** MIE outcomes in institutional series, systematic reviews, and case-control studies.

### Minimally Invasive Esophagectomy Technique

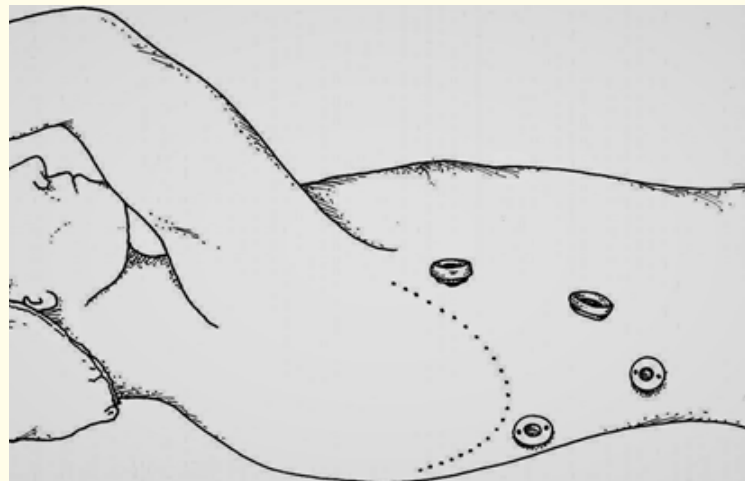
#### Transthoracic Esophagectomy with Cervical Anastomosis

After endoscopy to imagine the degree of ailment and reasonableness of the gastric conduit, the patient is intubated with a double lumen endotracheal tube and set in a left horizontal decubitus or prone position. Four thoracoscopic trocars are brought into the right thorax. Three 10-mm ports and one 5-mm port are put. One 5-mm port is utilized for retraction and is put quite recently anterior to the tip of the scapula. The initial 10-mm port placed in the seventh or eighth intercostal space anterior to the midaxillary line is for the camera.

The second 10-mm port is placed at the anterior axillary line in the fourth intercostal space. This is normally used to place the lung retractor. The final 10-mm port, which is used mostly for dissection and coagulation, is positioned at the eighth or ninth intercostal space at the posterior axillary line. A fifth 5-mm port can be positioned anteriorly at the sixth intercostal space as desirable for suction and assistance with the intrathoracic anastomosis [5,19] (Figure 1).

The initial step in the wake of setting up exact port position and representation is to put a suture (0-Surgiteck Endostitch) through the focal ligament segment of the stomach. This suture is then brought out anteriorly and poorly through the thorax at the level of addition of the stomach to encourage withdrawal and introduction of the distal throat and gastroesophageal intersection. Now, division of the second rate pneumonic tendon as performed. Accomplishing dismemberment onto the pericardium is imperative, with withdrawal of the mediocre pneumonic vein, to guarantee average introduction and to assemble the subcarinal lymph hubs and encompassing tissue, as this will be expelled with the example. Encourage dismemberment is helped out through the mediastinal pleura along the hilum to the level of the azygos vein. Once the azygos vein has been dismembered circumferentially, it is isolated utilizing an endoscopic stapler [5,19]. The subsequent stage is to activate the throat. This is begun by analyzing the parallel pleura overlying the throat from the azygos vein down to the gastroesophageal intersection, concentrating on staying away from damage to the thoracic pipe or aorta. By keeping

away from damage to the thoracic channel, the requirement for ligation of the conduit is deterred. All periesophageal hubs and fat are incorporated with the example. A Penrose deplete is useful in totally assembling the throat, permitting recovery amid neck dissection. To avert traction damage to the intermittent laryngeal nerves, the vagal trunks ought to be separated at the level of the azygos vein. Moreover, aortoesophageal connections are completely analyzed, cut, and isolated. Next, the lung is expanded, and the tracheal, bronchial, and parenchymal wounds are surveyed. Under thoracoscopic perception, a 28-French chest tube is put through the 10-mm camera port. The rest of the ports are then evacuated, and port destinations are shut utilizing polyglactin sutures. Utilizing bupivacaine, local anesthesia is given to the intercostal regions around the port destinations [7,20]. The following segment of the technique is the stomach laparoscopy. The patient is put in the prostrate position and soak invert Trendelenburg. Right now, the twofold lumen endotracheal tube can be supplanted with a solitary lumen tube. Five ports are required amid this piece of the system. A 10-mm port is first set under direct vision in the epigastrium between the xiphoid and umbilicus just to one side of midline. CO<sub>2</sub> insufflation is given through this port. Once satisfactory pneumoperitoneum is acquired, a 10-mm camera can be put and, under laparoscopic representation, the extra ports can be put. A 5-mm port is set just to one side of the midline at an indistinguishable level from the 10-mm port. The 10-mm camera can be evacuated, and a 5-mm, 30o camera is put through the 5-mm port. Extra 5-mm ports are embedded at the privilege and left subcostal edges. The last 5-mm port is set at the correct flank to permit liver withdrawal [7,19,20]. At this instant, the liver retractor is positioned to elevate the left lobe of the liver to permit appropriate visualization of the hiatus. The gastrohepatic ligament is divided, and the now exposed right and left crura are dissected until the gastroesophageal junction is freed. Evading dividing the phrenoesophageal ligament this prompt is important so that pneumoperitoneum is maintained. The gastrocolic ligament is recognized and, using ultrasonic coagulation shears, is divided lateral to the right gastroepiploic arcade.



**Figure 1:** Thoracoscopic port sites for transthoracic approach.

From now, the short gastric arteries are divided along the greater curvature to allow mobilization of the stomach. Once dissection has grasped the left crus, posterior gastroesophageal attachments and gastrocolic omentum are divided, conserving the right gastroepiploic arcade. The stomach is retracted overbearingly to expose the left gastric and celiac vessels. Nodal tissue in this region is dissected out and collected with the specimen. The left gastric artery and vein are then isolated and divided with clips and ties or a vascular stapler. The next step, after the stomach has been mobilized, is to perform a pyloroplasty. To diminish traumatic injury, the stomach must be handled with care. The pyloroplasty is generally performed in the Heinecke-Mikulicz fashion. A suture is placed superiorly and inferiorly on the pylorus to allow retraction. The ultrasonic shears or cautery is then used to create an opening in the pylorus. The opening is afterward closed with sutures in a transverse interrupted fashion. To permit the pylorus to reach the right crus and get tolerable mobilization of the gastric tube, the retrogastric and duodenal attachments are dissected as desired [7,20]. The gastric tube development is then completed as the

following stage. Making a gastric tube with a width no smaller than 4-5 cm is imperative. Anything smaller expands the danger of gastric tip putrefaction and neck spills. To make the gastric tube, a vascular-stacked endoscopic gastrointestinal anastomosis (GIA) stapler is first let go over the lesser-curve and flow vessels toward the incisura, protecting the privilege gastric vessels. This progression decides the breadth of the gastric tube and depends on the edge of the staple line. Ensuing stapling ought to be done along a line parallel to the more noteworthy bend vessels and arcade to keep up a steady width in the gastric tube and to evade gastric tube spiraling. The resected partition is joined to the gastric tube with two endosutures put from the tip of the fundus to the lesser bend of the example limiting the mass as this is gone through the rest and out the neck entry point and abstaining from winding [7,19,20]. An encouraging jejunostomy is then set. This may require an extra 10-mm port in the correct lower quadrant. With an Endostitch, a proximal jejunal appendage, controlled by first distinguishing the tendon of Treitz and following around 40 cm back, is connected to one side horizontal foremost stomach divider. A 5-French needle catheter is then set percutaneously into the jejunum (Compact Biosystems, Minneapolis, MN) under laparoscopic perception. A guide wire is put through the needle, which is then trailed by a jejunal catheter to a separation of around 20 cm. The bolstering tube is then furthermore attached to around 3 - 4 cm of separation to the foremost stomach divider for additionally bolster. To survey satisfactory arrangement, 10 mL of air or water are imparted through the tube. The last piece of the stomach operation is to now partition the phrenoesophageal tendon to encourage entry of the course through the break [7,20].

The last phase of the operation is the neck anastomosis. To begin, a 4-cm to 6-cm even neck entry point is made over the sternal score along the cervical wrinkle to uncover the cervical throat. Platysmal folds are created, the omohyoid is isolated, and dismemberment is conveyed down to the prevertebral belt. The cervical throat is then precisely analyzed and withdrew medially. With dismemberment conveyed down poorly, an open correspondence to the thoracic channel should now exist. The Penrose deplete from the thoracic technique should then be raised through the outlet to finish dismemberment. The example would then be able to be gradually conveyed through the neck entry point with the gastric conductor. A colleague ought to picture the section of the conductor through the rest laparoscopically to guarantee satisfactory and safe conveyance. Once conveyed through the neck, the two sutures holding the gastric tube to the example are partitioned and the example evacuated. The proximal throat is prepared by isolating 1 - 2 cm underneath the cricopharyngeal muscle, and after that a tote string suture is put with an auto-satchel string gadget (US Surgical, Norwalk, CT). After the reasonability of the gastric channel is guaranteed, a conclusion to-end anastomosis (EEA) is performed with a 25-mm EEA stapler; the iron block is set in the cervical throat and the tote string tied firmly around it while a little gastrotomy is made in the proximal gastric tube. Once the anastomosis is finished, a nasogastric tube is put under direct vision, and the gastrotomy is shut with an endoscopic GIA stapler.

The last step of the operation is to return to the abdominal cavity and apply gentle traction to the antral area until the cervical anastomosis returns into the neck incision. This also permits removal of the redundant gastric tube in the mediastinum. To avoid proximal herniation of the gastric tube, tacks are applied to attach the gastric tube to the hiatus. Normally, three sutures are placed. One is placed from the greater curvature to the left crus. Another is placed from the lesser curvature to the right crus. The last tack attaches the central edge of the hiatus to the anterior gastric tube. The cervical anastomosis is irrigated, hemostasis is preserved, and closure of all port sites and the cervical incision is completed [7,20].

### **Laparoscopic Transhiatal Esophagectomy**

The laparoscopic transhiatal esophagectomy initiates with the patient supine in the reverse Trendelenburg position, with the right thorax raised by 30° if there is a need for an emergency thoracotomy. Usually, the surgeon stands between the patient's legs. As with the transthoracic method, five ports are used. Placement of the first port is along the midline about 5 cm above the umbilicus using a 12-mm port. Pneumoperitoneum is established and a 30° scope inserted. The lasting ports can now be placed under laparoscopic visualization to avoid intra-abdominal injury. A 5-mm port is placed at the subxiphoid for liver retraction. Two more 12-mm ports are placed, one on the right midclavicular line (grasping) and the other on the left midclavicular line (dissection). The final 5-mm port is inserted at the left paraumbilical side for additional retraction [21,22].

Luketich, *et al.* have initiated to use a minimally invasive Ivor Lewis (transthoracic) approach wherein the anastomosis is being achieved within the thoracic cavity. It has been presented that with the experience of this group, morbidity and mortality are similar to those of procedures done with a cervical anastomosis. Moreover, Luketich has presented that they have removed the risk of recurrent laryngeal nerve injury and diminished pharyngeal and oropharyngeal swallowing dysfunction by using a thoracic anastomosis [23].

### Conclusion

The data recommend that operative mortality is insignificant between open and MIE, and operative morbidity in a few studies is enhanced after MIE. Moreover, comparisons of functional result after open versus MIE without pyloric drainage show little difference. The data though are severely limited in that the majority of the studies are either retrospective case series, or case-control studies, or meta-analyses of retrospective case-control studies-all limited by both selection and publication bias. Prospective, randomized studies are essential if any conclusion is to be made about the superiority of one surgical therapy over the other. The data also does not demonstrate superior outcomes as a result of prone positioning or gastric ischemic conditioning. Leaks are progressively being managed via less intrusive, endoscopic stenting with good outcomes, but controlled, prospective studies are essential to make any conclusions about outcomes after endoscopic stenting versus conventional treatments. The data does indeed support developed outcomes when performed at high volume centers by experienced esophageal surgeons. Largely, MIE is an integral tool that is safe and effective in the surgical management of esophageal cancer, and further study is warranted to determine if it should be the best standard procedure.

### Bibliography

1. Portale G., *et al.* "Modern 5-year survival of resectable esophageal adenocarcinoma: single institution experience with 263 patients". *Journal of the American College of Surgeons* 202.4 (2006): 588-596.
2. Kim T., *et al.* "Esophageal cancer-the five year survivors". *Journal of Surgical Oncology* 103.2 (2011): 179-183.
3. Orringer MB., *et al.* "Transhiatal esophagectomy: clinical experience and refinements". *Annals of Surgery* 230.3 (1999): 392-403.
4. Orringer MB., *et al.* "Two thousand transhiatal esophagectomies: changing trends, lessons learned". *Annals of Surgery* 246.3 (2007): 363-372.
5. Luketich JD., *et al.* "Minimally invasive approach to esophagectomy". *Journal of the Society of Laparoendoscopic Surgeons* 2.3 (1998): 243-247.
6. Litle VR and Luketich JD. "Minimally invasive esophagectomy". *CTSNet* (2008).
7. Luketich JD., *et al.* "Minimally invasive esophagectomy: outcomes in 222 patients". *Annals of Surgery* 238.4 (2003): 486-495.
8. Bizakis C., *et al.* "Initial experience with minimally invasive ivor lewis esophagectomy". *Annals of Thoracic Surgery* 82.2 (2006): 402-407.
9. Rajan PS., *et al.* "Minimally invasive oesophagectomy for carcinoma oesophagus - Approaches and options in a high volume tertiary centre". *Journal of the Indian Medical Association* 108.10 (2010): 642-644.
10. Nguyen NT., *et al.* "Minimally invasive esophagectomy lessons learned from 104 operations". *Annals of Surgery* 248.6 (2008): 1081-1091.
11. Ben-David K., *et al.* "Decreasing morbidity and mortality in 100 consecutive minimally invasive esophagectomies". *Surgical Endoscopy* 26.1 (2012): 162-167.

12. Ben-David K, *et al.* "Minimally Invasive Esophagectomy is Safe and Effective Following Neoadjuvant Chemoradiation Therapy". *Annals of Surgical Oncology* 18.12 (2011): 3324-3329.
13. Rossidis G, *et al.* "Overcoming challenges in implementing a minimally invasive esophagectomy program at a Veterans Administration medical center". *American Journal of Surgery* 202.4 (2011): 395-399.
14. Gemmill EH and McCulloch P. "Systematic review of minimally invasive resection for gastro-oesophageal cancer". *British Journal of Surgery* 94.12 (2007): 1461-1467.
15. Verhage RJJ, *et al.* "Minimally invasive surgery compared to open procedures in esophagectomy for cancer: a systematic review of the literature". *Minerva Chirurgica* 64.2 (2009): 135-146.
16. Nagpal K, *et al.* "Is minimally invasive surgery beneficial in the management of esophageal cancer? A meta-analysis". *Surgical Endoscopy and Other Interventional Techniques* 24.7 (2010): 1621-1629.
17. Mamidanna R, *et al.* "Short-term outcomes following open versus minimally invasive esophagectomy for cancer in England: a population-based national study". *Annals of Surgery* 255.2 (2012): 197-203.
18. Pennathur A and Luketich JD. "Minimally invasive esophagectomy: short-term outcomes appear comparable to open esophagectomy". *Annals of Surgery* 255.2 (2012): 206-207.
19. Kent MS, *et al.* "Minimally invasive esophagectomy: state of the art". *Diseases of the Esophagus* 19.3 (2006): 137-145.
20. Wee JO, *et al.* "Minimally invasive esophagectomy". Sugarbaker DJ, Bueno R, Krasna MJ, *et al*, eds. *Adult Chest Surgery*. New York: McGraw-Hill Professional (2009).
21. Palanivelu C, *et al.* "Laparoscopic esophagogastrectomy without thoracic or cervical access for adenocarcinoma of the gastroesophageal junction: an Indian experience from a tertiary center". *Surgical Endoscopy* 21.1 (2007): 16-20.
22. Benzoni E, *et al.* "Minimally invasive esophagectomy: a comparative study of transhiatal laparoscopic approach versus laparoscopic right transthoracic esophagectomy". *Surgical Laparoscopy Endoscopy and Percutaneous Techniques* 18.2 (2008): 178-187.
23. Levy RM, *et al.* "Laparoscopic and thoracoscopic esophagectomy". *Advances in Surgery* 44.1 (2010): 101-116.

**Volume SI Issue 1 August 2017**

**©All rights reserved by Khalaf Mohammed Khalaf Alsayyali, *et al.***