

## Bane and Anathema-Leprosy Lymphadenitis

**Anubha Bajaj\***

Department of Histopathology, Panjab University, A.B. Diagnostics, India

**\*Corresponding Author:** Anubha Bajaj, Department of Histopathology, Panjab University, A.B. Diagnostics, India.

**Received:** March 06, 2026; **Published:** May 01, 2026

Leprosy emerges as a contagious, chronic infectious disease engendered by *Mycobacterium leprae*. Lesions are preponderantly confined to cutis, peripheral nerves, mucosa of upper respiratory tract and ocular region. Lymph nodes are exceptionally involved.

Infiltration of lymph nodes with lymph node enlargement is infrequent. Subjects demonstrate pyrexia, neurological symptoms as significant pain, palpable bilateral ulnar nerve, worsened palmoplantar esthesiometric examination, classical lesions of erythema nodosum or absence of pain.

The intensely variable clinical representation is indicative of host immunological spectrum in response to *Mycobacterium leprae* infection comprised of Th1 and Th2 pattern of immune reaction [1,2].

Clinically, leprosy simulates diverse disease processes and expounds varied manifestations as numbness of extremities, non healing ulcer, repetitive ulcers, sensory loss or erythematous macules [1,2].

Localized pain with radiation, chills, insomnia, night sweats and spontaneous weight loss may ensue. Unilateral or bilateral lymphadenopathy may occur. Painless thickening of bilateral ulnar nerves and discrete infiltration of earlobes may be observed.

Lepromatous leprosy expounds infiltration of spleen and hepatic parenchyma. Lymphoma may simulate or concur with lepromatous leprosy [2,3].

Besides, leprosy may simulate diseases as sarcoidosis, cutaneous lymphomas, Jessner's lymphocytic infiltrate or connective tissue diseases [2,3].

Fine needle aspiration cytology (FNAC) of lymph node depicts foamy macrophages and poorly defined epithelioid cell granulomas [2,3].

Upon microscopy, lepromatous leprosy is comprised of lesions enunciating an infiltration of enlarged, pale, spherical histiocytes. An absence of epithelioid cell granulomas is encountered [3,4].

Alternatively, surgical tissue samples depict superficial ulceration, epithelioid cell granulomas and foamy macrophages. A distinct Grenz zone impregnated with acid fast bacilli of *Mycobacterium leprae* is observed. Necrosis is absent to minimal [3,4].

Discrete foci of perivascular inflammatory infiltrate with absent acid fast bacilli may be enunciated [3,4].

Infiltrated perilesional region is associated with epidermal rectification and a distinct Grenz zone expounding innumerable bacilli [4,5].

Disorganized dermal and perineural epithelioid cell granulomas are accompanied by an intense infiltrate of xanthomatous histiocytes impregnated with innumerable acid fast bacilli of *Mycobacterium leprae*.

Morphologically, lymph node stroma is disorganized. Quantifiably significant histiocytes are observed. Absence of necrotic areas or infiltration of leukocytes may concur with lymph node reaction due to leprosy [4,5].

Leprosy induced lymph node involvement appears as a component of visceral disease observed in multi-bacillary subjects. The reticuloendothelial system expounds spectral infiltration by *Mycobacterium lepra*, akin to cutaneous lesions [4,5].

T cell prolymphocytic leukaemia
T cell large granular lymphocytic leukaemia
Chronic lymphoproliferative disorder of NK cells
Aggressive NK cell leukaemia
Systemic EBV+ T cell lymphoma of childhood
Hydroa-vacciniforme like lymphoproliferative disorder
Adult T-cell leukaemia /lymphoma
Extra-nodal NK/T cell lymphoma-nasal type
Enteropathy associated T cell lymphoma
Monomorphic epitheliotropic intestinal T cell lymphoma
Indolent T cell lymphoproliferative disorder of the gastrointestinal tract
Hepatoplenic T cell lymphoma
Subcutaneous panniculitis like T cell lymphoma
Mycosis fungoides
Sezary syndrome
Primary cutaneous CD30+ T cell lymphoproliferative disorder
Lymphomatoid papulosis
Primary cutaneous anaplastic large cell lymphoma
Primary cutaneous $\alpha^{\delta}$ T cell lymphoma
Primary cutaneous CD8+ aggressive epidermotropic cytotoxic T cell lymphoma
Primary cutaneous acral CD8+ T cell lymphoma
Primary cutaneous CD4+ small/medium T cell lymphoproliferative disorder
Peripheral T cell lymphoma NOS
Angio-immunoblastic T cell lymphoma
Follicular T cell lymphoma
Nodal peripheral T cell lymphoma with TFH phenotype
Anaplastic large cell lymphoma ALK+
Anaplastic large cell lymphoma ALK-
Breast implant associated anaplastic large cell lymphoma

**Table:** WHO classification of mature lymphoid histiocytic and dendritic T cell neoplasm (2016) [6].

The causative, acid fast organisms may be appropriately discerned by modified Ziehl-Neelsen stain which demonstrates numerous acid-fast bacilli, thereby indicating lymphadenitis due to leprosy [7,8].

Fite-Faraco stain expounds clusters of innumerable acid fast bacilli. Leprosy necessitates segregation from lesions as lymphoma, granuloma annulare, fungal infection, annular psoriasis, systemic lupus erythematosus, keloid, mycosis fungoides, neurofibromatosis or cutaneous leishmaniasis [7,8].

Ultrasonography depicts enlarged lymph nodes with reactive architecture or splenomegaly. Haematological parameters may expound lymphopenia [8,9].

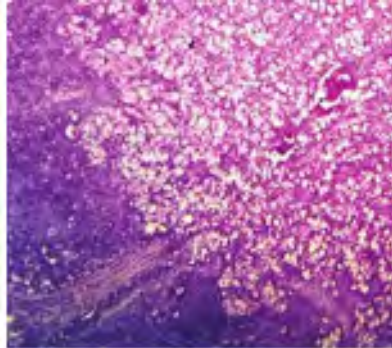
Nerve conduction studies may be employed to assess amplitude of bilateral ulnar and sural nerves or median nerve [8,9].

Fine needle aspiration cytology (FNAC) is beneficial in diagnosis of lymphadenopathy due to leprosy wherein exclusion of diverse causes of lymphadenitis may be obtained [8,9].

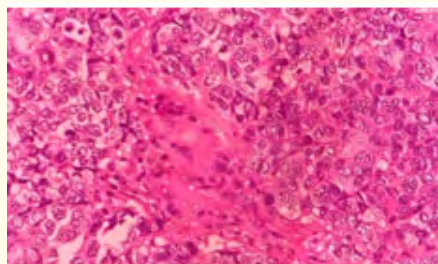
Leprosy may be adequately detected by polymerase chain reaction (PCR). Alternatively, immunofluorescence techniques may be employed. An interruption of chain of disease transmission is necessitated, especially within subjects with multi-bacillary disease [10,11].

Multi-bacillary lesions are appropriately treated with multidrug therapy. Agents such as rifampin, dapsone, clofazimine, minocycline, ofloxacin, moxifloxacin, levofloxacin and clarithromycin may be beneficially employed [10,11].

Meticulous monitoring for leprosy bacilli in various organs apart from cutis or peripheral nervous system is necessitated [10,11].



**Figure 1:** Leprosy lymphadenitis depicting an infiltration of enlarged, pale histiocytes and disorganized lymphoid architecture. Perivascular inflammatory infiltrate is absent [12].



**Figure 2:** Leprosy lymphadenitis delineating an infiltration of enlarged, pale histiocytes impregnated with acid fast bacilli. Ill defined epithelioid cell granulomas are seen [13].

## **Bibliography**

1. Deps PD., *et al.* "Leprosy research updates: Shaping the future of global health". *Indian Journal of Medical Research* 161.2 (2025): 120-124.
2. Chitkara F., *et al.* "Lepromatous lymphadenitis: a rare manifestation of leprosy diagnosed by fine needle aspiration cytology". *Annals of Pathology and Laboratory Medicine* 12.9 (2025): C143-C146.
3. Froes Luis Alberto., *et al.* "Leprosy: clinical and immunopathological characteristics". *Anais Brasileiros de Dermatologia* 97.3 (2022): 338-347.
4. Victor Henrique Murback dos Reis., *et al.* "Borderline lepromatous leprosy with lymph node infiltration: Dermatology helps to clarify challenging diagnoses". *Anais Brasileiros de Dermatologia* 100.3 (2025): 615-618.
5. Bhandari J., *et al.* "Leprosy". Stat Pearls International. Treasure Island, Florida (2025).
6. Steven H Swerdlow., *et al.* "The 2016 revision of world health organization classification of lymphoid neoplasm". *Blood* 127.20 (2016): 2375-2390.
7. Reis VHMD., *et al.* "Borderline lepromatous leprosy with lymph node infiltration: Dermatology helps to clarify challenging diagnoses". *Anais Brasileiros de Dermatologia* 100.3 (2025): 615-618.
8. Cline K A. "Challenges in leprosy control: Addressing gaps in diagnosis and treatment". *Journal of Global Health* 11.2 (2019): 112-118.
9. Miller J F. "The rise of multidrug-resistant leprosy: Implications for treatment and eradication efforts". *Journal of Infectious Diseases* 222.8 (2021): 1369-1374.
10. van Hooij A., *et al.* "Prototype multi-biomarker test for point-of-care leprosy diagnostics". *iScience* 24.1 (2020): 102006.
11. Florian MC., *et al.* "Clinical aspects and classification of Hansen's disease". In: Deps PD, editor. Hansen's disease. Cham: Springer International Publishing (2023): 81-108.
12. Image 1 Courtesy: *International Journal of Medicine*.
13. Image 2 Courtesy: Leprosy review.

**Volume 22 Issue 5 May 2026**

**©All rights reserved by Anubha Bajaj.**