

## Implementation Possibilities of Reproductive Potential in Patients with Endometrial Cancer G2 with Polycystic Ovary Syndrome (PCOS) and Infertility on the Example of a Clinical Case

Pasman NM<sup>1,2</sup>, Shumeikina AO<sup>1,3,4\*</sup>, Kedrova AG<sup>3,5</sup>, Chernyshova AL<sup>6</sup> and Krasilnikov SE<sup>1,3,7</sup>

<sup>1</sup>Federal State Autonomous Educational Institution of Higher Education "Novosibirsk National Research State University", Novosibirsk, Russia

<sup>2</sup>Limited Liability Company "Clinic of Professor Pasman", Novosibirsk, Russia

<sup>3</sup>Federal State Budgetary Institution "National Medical Research Center Named After Academician E.N. Meshalkin" of the Ministry of Health of the Russian Federation, Novosibirsk, Russia

<sup>4</sup>Federal State Budget Scientific Institution "Federal Research Center of Fundamental and Translational Medicine", Russia

<sup>5</sup>Federal State Budgetary Institution "Federal Scientific and Clinical Center for Specialized Types of Medical Care and Medical Technologies of the Federal Medical and Biological Agency of Russia", Moscow, Russia

<sup>6</sup>Tomsk National Research Medical Center, Russian Academy of Science, Tomsk, Russia

<sup>7</sup>Novosibirsk State Medical University, Krasny Prospect, Novosibirsk, Russia

**\*Corresponding Author:** Shumeikina AO, Federal State Autonomous Educational Institution of Higher Education "Novosibirsk National Research State University", Novosibirsk, Russia.

**Received:** August 15, 2023; **Published:** September 05, 2023

### Abstract

A clinical case demonstrates the possibilities of treating endometrial cancer and, in the subsequent implementation of reproductive function.

**Keywords:** Reproductive Potential; Endometrial Cancer G2; Polycystic Ovary Syndrome (PCOS); Infertility

### Introduction

PCOS occurs in 5 - 10% of women. Difficulties in the implementation of reproductive function in patients with PCOS are associated with several factors - with anovulation, which leads to infertility, as well as endometrial pathology, which occurs in 70% of cases, while endometrial cancer in patients with PCOS occurs in 5 - 7%.

### Description of the Clinical Case

Patient A., 26 years old, diagnosed with PCOS, primary infertility, endometrial polyp (according to ultrasound for two years) turned to Professor Krasilnikov S.E. for hysteroresectoscopy of the endometrial polyp. According to the pathomorphological conclusion dated 12/18/2017. N 42180 - moderately differentiated (G2) adenocarcinoma in the polyp.

Considering the age of the patient, the desire to maintain reproductive function, the absence of a history of pregnancies, in January 2018 the patient was referred to the Tomsk National Research Medical Center for a revision of the pathological material and a repeated endometrial biopsy under hysteroscopy control.

According to the revision dated 01/15/2018 N 6736/17 - moderately differentiated (G2) adenocarcinoma in the polyp, histological examination after repeated hysteroscopy N562-68/18 dated 01/22/2018 - endometrial hyperplasia without atypia.

Patient's diagnosis is Endometrial cancer IA st T1aN0M0.

By the decision of the council: doctors recommended organ-preserving treatment, then a levonorgestrel-containing intrauterine system was installed and treatment with gonadotropin-releasing hormone agonists was carried out for 6 months with control hysteroscopies, the treatment was carried out during 2018 - 2019.

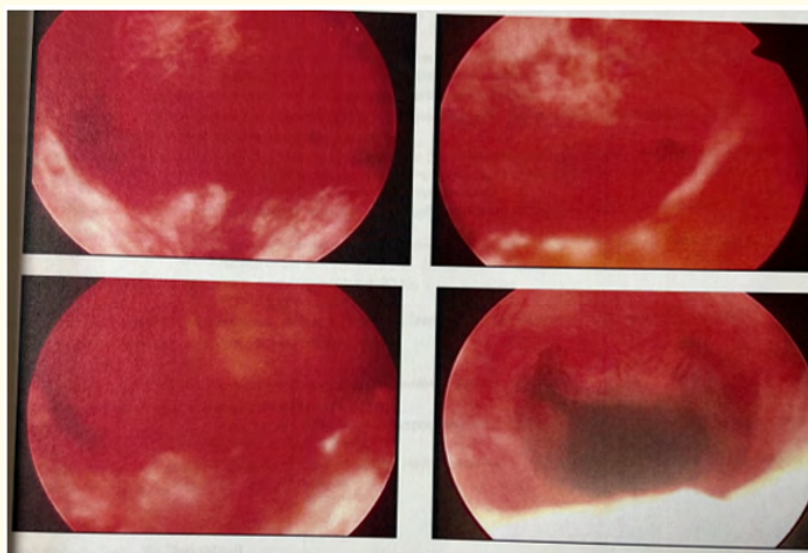
After completing the oncological stage of treatment, the patient was referred to the clinic of Professor Pasman for the implementation of the reproductive function.

In August 2019 there was hysteroscopy, photodynamic therapy of the uterine cavity, according to the histological examination of August 26, 2019 No. 33445 - complex endometrial hyperplasia without atypia. To assess resistance to hormone therapy, immunohistochemical study No. 2618/20 dated 01/31/2020 was carried out - diffuse expression of antibodies to progesterone receptors.

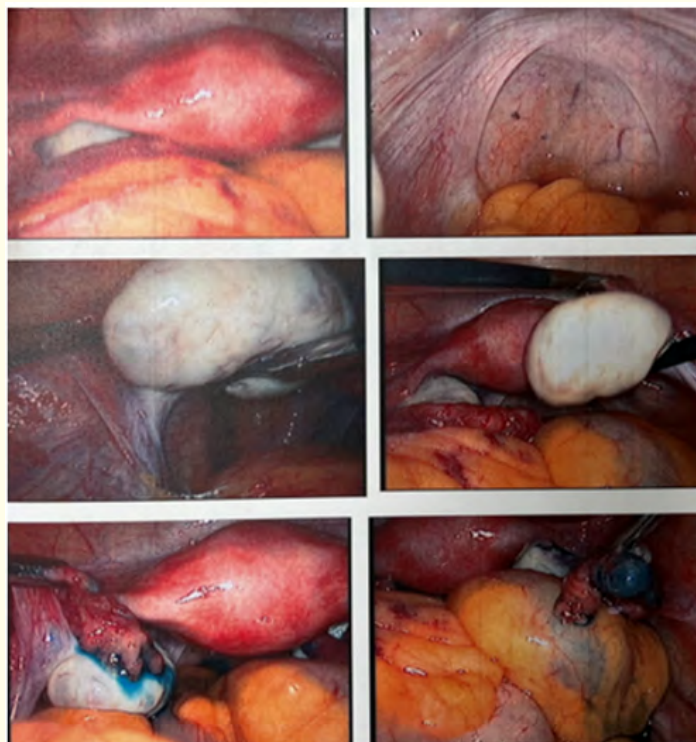
At a consultation consisting of an oncologist, an obstetrician-gynecologist, a reproductive specialist with the participation of Professor Pasman N.M. an attempt at spontaneous conception is recommended, with ineffectiveness after 1 month - controlled induction of ovulation - a short protocol (clomiphene citrate 50 mg from 2 to 6 days + Gonal) and artificial insemination with husband's sperm. Also the examination revealed polymorphism of hemostasis genes - heterozygous F13, homozygous PAI-1 and MTHRR, heterozygous.

Laparoscopy, ovarian drilling, hysteroscopy were performed on February 8<sup>th</sup>, 2022. Two months later artificial insemination with the husband's sperm had successfully performed in a natural cycle. During pregnancy were diagnosed: Gestational diabetes mellitus, the target level of glycated hemoglobin is less than 6%. Isthmicocervical insufficiency, correction with a circular suture, obstetric pessary.

Finally, patient had timely operative delivery during pregnancy I at 37 weeks 3 days, urgent Caesarean section in the Novosibirsk Regional Perinatal Center on December 21<sup>st</sup>, 2022. Volume of blood loss = 400 ml, boy 3900g, 52 cm, 8/8 Apgar scores. There are currently no data for recurrence and progression.



**Figure 1:** Hysteroscopy, chronic endometritis, photodynamic therapy, August 2019.



*Figure 2: Laparoscopy, ovarian drilling, February 2022.*

### Conclusion

- 1) When treating patients with PCOS, it is recommended to perform hysteroscopy, a histological examination to diagnose the state of the endometrium and identify endometrial pathology before using assisted reproductive technologies.
- 2) In patients diagnosed with cancer of the uterine body and PCOS, it is possible to carry out organ-preserving treatment without violating oncological principles.
- 3) The decision on pregnancy planning and management of pregnancy and childbirth is made at a consultation with the participation of an oncologist, an obstetrician-gynecologist, and a reproductologist.