ECRONICON OPEN ACCESS

EC GYNAECOLOGY
Research Article

Quantitative Assessment of the Extraorgan Anastomoses of the Uterine Artery in Women of Mesomorphic Somatotype

Kuzmenko Alexander Victorovich*

Associate Professor, Department of Human Anatomy, Establishment of Education "Gomel State Medical University", Gomel, Republic of Belarus

***Corresponding Author:** Kuzmenko Alexander Victorovich, Associate Professor, Department of Human Anatomy, Establishment of Education "Gomel State Medical University", Gomel, Republic of Belarus.

Received: October 27, 2022; **Published:** January 30, 2023

Abstract

Background and Aim: The UtA is one of the arteries of the pelvic cavity on which endovascular operations are often performed. The anatomy of the anastomotic branches of the a. uterina is of interest to researchers due to their effect on hemostasis during endovascular interventions. However, the quantitative assessment of extraorgan collaterals of the UtA is not widely used in modern works. The aim of the study was to develop an algorithm for the quantitative assessment of extraorgan anastomoses of the UtA in women of mesomorphic somatotype and to obtain data on the anatomy of these collaterals.

Materials and Methods: The material for the study was 59 cadavers of mesomorphic women (aged 32 to 88 years), who died because of accidental causes not associated with the pathology of the pelvic organs. To achieve the goal of the study, the method of vascular injection, preparation method, somatotype method, mathematical modelling method and statistical processing of the obtained data were used.

Results: According to our data 15 extraorgan anastomoses of the UtA, which is 25.4% of cases were found on the right half of the pelvis in mesomorphic women. Twelve extraorgan anastomoses of the UtA, which is 20.3% of cases were identified on the left half of the mesomorphic female pelvis. Quantitative assessment of the extraorgan anastomoses of the UtA in mesomorphic women on the right side of pelvic cavity can be performed by the formula: X = 0.2542 * Z. On the left half of the mesomorphic female pelvis, such a quantitative assessment can be calculated by the formula: X = 0.2029 * Z. Where Z is the number of mesomorphic females, and X is the number of extraorgan anastomoses UtA, which varies in proportion to the variable Z.

Conclusion: The developed algorithm for the quantitative assessment of extraorgan anastomoses of the UtA with a high degree of probability allows you to set the number of collaterals depending on the change in the size of the study sample.

Keywords: *Uterine Artery; Extraorgan Anastomoses; Pelvic Cavity; Embolization*

Abbreviations

IIA: Internal Iliac Artery; UA: Umbilical Artery; SVA: Superior Vesical Artery; MRA: Middle Rectal Artery; IGA: Inferior Gluteal Artery; ILA: Iliolumbar Artery; IVA: Inferior Vesical Artery; UtA: Uterine Artery; OA: Obturator Artery; IPA: Internal Pudendal Artery; SGA: Superior

Gluteal Artery; LSA: Lateral Sacral Artery; CT: Common Trunk for Inferior Gluteal and Internal Pudendal Arteries; A: Arteria (Artery in Latin)

Introduction

The UtA is the artery of the pelvic cavity on which endovascular operations are often performed to stop bleeding from the uterus [1-3] or in the presence of neoplasms inside the uterus [4-6]. It should be noted that in the specialized scientific literature some unsuccessful cases of embolus formation for occlusion of the visceral branches of the IIA have been described in the presence of well-developed extra-organ anastomoses [7]. It should be emphasized, that despite the growing interest of clinicians to the variant of anatomy of the anastomoses of the branches of the IIA, the number of studies aimed at improving of detail of data on the topography and types of anastomoses of these arteries remains insignificant. Usually, only a fragmentary information on the anatomy of the arterial anastomosis of the pelvic arteries is provided [8,9] in specialized sources. At the same time, the options for the topography of the intrapelvic anastomoses are not described, and a comparative characteristic of the variant anatomy of these anastomoses, depending on the somatotype of the person, is not carried out. In addition, there are no works on the quantitative assessment of extraorgan anastomoses of the arteria uterina.

Aim of the Study

To develop an algorithm for the quantitative assessment of extraorgan anastomoses of the UtA in women of mesomorphic somatotype and to obtain data on the anatomy of these collaterals.

Materials and Methods

To achieve our goal, the branches of the IIA were prepared along with their intrapelvic arterial anastomoses on 59 unfixed cadavers of women of mesomorphic somatotype (aged 32 to 88 years) on both sides of the pelvic cavity. The caliper SHC-I-150-0.02 was used to measure the lengths of the isolated vessels, and an MK-63 micrometre was used to establish the values of their diameters. The caliper SHC-III-500-0.1 was used to measure the distance between the extreme points of the acromions in each woman. When measuring the height of a corpses, a tape was used ATLAS TAPE MEASURE. The instruments have passed specialized metrological verification at the Republican Unitary Enterprise "Vitebsk Centre for Standardization, Metrology and Certification" before performing the work.

In cases where the layer of subcutaneous adipose tissue was not thick, operative access to the branches of a. iliaca interna was performed using a complete midline laparotomy of access from the level of the xiphoid process of the sternum to the pubic symphysis. Within the incision, we performed dissection of the subcutaneous tissue, superficial fascia, white line of the anterior abdominal wall, transverse fascia of the abdomen, the layer of preperitoneal fat tissue and the anterior leaf of the parietal peritoneum. When the subcutaneous fat tissue was significant, we performed an operative approach in an oblique direction from the xiphoid process of the sternum to the lowest points of the right and left tenths of the ribs. Then the incision was made symmetrically to the crests of the right and left iliac bones. The final stage of the surgical approach was performed from the anterior superior iliac spine parallel to the inguinal fold of the skin to the external edge of the rectus abdominis muscle. With this type of incision of the anterior abdominal wall, it becomes possible to cut out a flap of the skin and deeper soft tissues, which eliminates the difficulty of working through a linear incision with a thick layer of subcutaneous fat. Then we shifted the organs of the peritoneal cavity towards the diaphragm and dissected the posterior sheet of the parietal peritoneum and sequentially isolated the bifurcation of the aorta, as well as the common, external, and internal iliac arteries. Billroth forceps were applied near the origin of the common and external iliac arteries, after which we punctured a. iliaca communis with a syringe, injecting 50 ml of a solution of red ink into it. The injection of a contrast agent has significantly increased the degree of visualization of the branches of IIA and their intrapelvic anastomoses.

We began exposing the IIA branches with displacement of the posterior leaf of the parietal peritoneum to the medial side and removal of the connective tissue off of a. iliaca interna and UA in one of the halves of the pelvic cavity. Then, the following arteries were sequentially isolated: SVA, IVA, UtA, OA, MRA, IPA, IGA, SGA, ILA and LSA. In addition to these arteries, we dissected all extraorgan anastomoses extending from a. uterina.

Macro photography was carried out.

The somatotype was determined according to the Nikityuk-Kozlov method.

Using the data obtained by the anthropometric method, we determined the relative width of the shoulders on all examined corpses using the following formula: Shoulder width × 100 ÷ corpse height = relative shoulder width. Then we determined the arithmetic mean (M) and standard deviation (SD) from all data on the relative shoulder width of the examined corpses.

The boundaries between the intervals of mesomorphic somatotypes are determined by the following formulas: M - 0.67 × SD; M + 0.67 × SD.

We have developed a mathematical model to predict the number of intrapelvic arterial anastomoses of UtA, depending on the change in the number of objects included in the analyzing variation series. We built a graph in the form of a curvilinear trapezoid to establish the distribution of the central trend of the studied trait (the ratio of the number of anastomoses to the number of corpses) in the general population. The area of the resulting geometric figure was calculated by the formula:. After that, the values of the areas of the curved trapezium per one examined corpse (S1) and one detected intrapelvic anastomosis of the UtA (S2) were calculated, where S1 is the area of the curved trapezium divided by the number of corpses, and S2 is the area of the curved trapezium divided by the number of intrapelvic anastomoses of a. uterina in the women of mesomorphic body types. Then, the coefficient (k), which determines the number of anastomotic branches of the UtA, depending on the change in the sample, was calculated by the formula: k = S1/S2. Based on the obtained data, the calculation of the number of intrapelvic anastomoses of a. uterina can be calculated as following: X = k * Z, where X is the number of arterial anastomoses in a specific sample of research objects, k is a coefficient reflecting the distribution of the frequency of intrapelvic anastomoses of UtA in the general population, Z is the number of selected research objects.

The statistical method of the study was carried out in the framework of the specialized MedStat package (licensed version No. 3, serial number MS 000050). To determine the type of distribution of the obtained numerical variational series (obeying the normal law or different from it), the W-criterion of Shapiro-Wilk was calculated. After the completion of the calculations, it was found that all the variational series obey the normal distribution law. Then, the values of the mean lengths and diameters of the UtA and its extraorgan anastomoses were calculated together with the determination of the confidence intervals (CI) for them. For comparative evaluation between diameters a. uterina and its anastomotic branches of mesomorphic somatotype women, we calculated the Student's t-test (T) for two independent samples. In order to identify a correlation between an increase in the diameter of the UtA in mesomorphic somatotype women and an increase in the diameters of its intrapelvic anastomoses, the Pearson correlation coefficient (R) was calculated.

Results

According to the results of our studies, the size of the average length of the UtA in mesomorphic women on the right side of pelvic cavity was 4.8 cm with CI = (4.4; 5.2) cm, and the size of the average diameter of this artery was 4.2 mm with CI = (3.8; 5,0) mm; average length of extraorgan anastomoses a. uterina is 1.5 cm with CI = (1.3; 1.7) cm, and the average diameter of these anastomoses is 1.9 mm with CI = (1.7; 2.2) mm.

Comparative characteristics of the average values of the diameter of the UtA in mesomorphic women on the right side of pelvic cavity and its extraorganic anastomoses revealed that there are statistically significant differences between them (the value of the Student's test

is equal to T = 5.88 at p < 0.001). This indicates that the average diameter of a. uterina significantly exceeds the average diameter of its extraorgan arterial anastomoses. Calculation of the Pearson correlation coefficient showed that there is no linear correlation between the values of the diameters of the UtA and its anastomoses (R = 0.24 at p = 0.292). Thus, with increasing diameter of a. uterina an increase in the diameter of the extraorgan anastomosis of this artery in all cases should not be expected.

According to our data 15 extraorgan anastomoses of the UtA, which is 25.4% of cases were found on the right half of the pelvis in mesomorphic women. It should be emphasized that, according to results of our investigation, the most frequent extraorgan anastomoses of the a. uterina are localized in the proximal (73.4% of the total number of isolated anastomoses, 11 vessels) and middle (26.6% of the total number of isolated anastomoses, 4 vessels) thirds of this artery. It was not found presence of such anastomotic branches in distal third of UtA.

On the right half of the pelvic cavity in mesomorphic women, the UtA formed 4 anastomoses with IPA (26.6% of the total number of isolated anastomoses), with IVA - 3 anastomoses (20.0% of the total number of isolated anastomoses), with UA - 3 anastomosis (20.0% of the total number of isolated anastomoses), with SGA - 2 anastomoses (13.3% of the total number of isolated anastomoses). A. uterina has given off 1 anastomotic branch each to the IGA, MRA (Figure 1) and CT (6.7% each of the total number of isolated anastomoses).

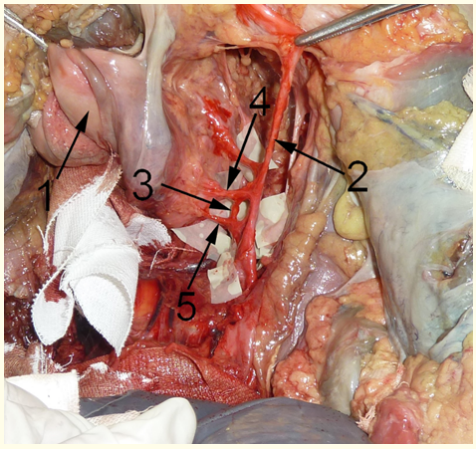

Figure 1: *Arteries and anastomoses in the right half of the pelvic cavity of a 49 year old mesomorphic woman. 1-uterus; 2-umbilical artery; 3-anastomose between the uterine and middle rectal arteries; 4-uterine artery; 5-middle rectal artery.*

It was found that the size of the average length of the UtA in mesomorphic women on the left side of pelvic cavity is 5.2 cm with CI = (4.7; 5.7) cm, and the size of the average diameter of this artery is 4.0 mm with CI = (3.6; 4.6) mm. According to our data, the average length of extraorgan anastomoses of a. uterina in mesomorphic women on the left side of pelvic cavity is 1.4 cm with CI = (1.2; 1.7) cm, and the average diameter of these anastomoses is 2.0 mm with CI = (1.7; 2.3) mm.

Calculation of the Student's t-test (T = 7.23 at p < 0.001) revealed the differences in the mean values of the diameter of the UtA and its extraorgan anastomoses in mesomorphic women on the left side of pelvic cavity at a statistically significant level. This indicates that the average diameter of a. uterina significantly exceeds the average diameter of its extraorgan arterial anastomoses. After calculating of the Pearson correlation coefficient, it was found that there is no linear correlation between the values of the diameters of the UtA and its anastomoses (R = 0.128 at p = 0.243). Thus, with increasing diameter of a. uterina an increase in the diameter of the extraorgan anastomosis of this artery in all cases should not be expected.

Twelve extraorgan anastomoses of the UtA, which is 20.3% of cases were identified on the left half of the mesomorphic female pelvis. According to our data, the most frequent extraorgan anastomoses of the UtA were localized in the proximal (58.3% of the total number of isolated anastomoses, 7 vessels) and middle (33.3% of the total number of isolated anastomoses, 4 vessels) thirds of this artery. Much less often, these anastomoses can be identified in mesomorphic women on the left side of pelvic cavity in the distal third of a. uterina (8.4% of the total number of isolated anastomoses, 1 vessel).

It was found that on the left half of the pelvis in men, the UtA formed 4 anastomoses with SVA (33.3% of the total number of isolated anastomoses), with IPA - 4 anastomoses (33.3% of the total number of isolated anastomoses), with UA - 2 anastomoses (16.6% of the total number of isolated anastomoses), with MRA and IVA (Figure 2) - 1 anastomose each (8.4% each of the total number of isolated anastomoses).

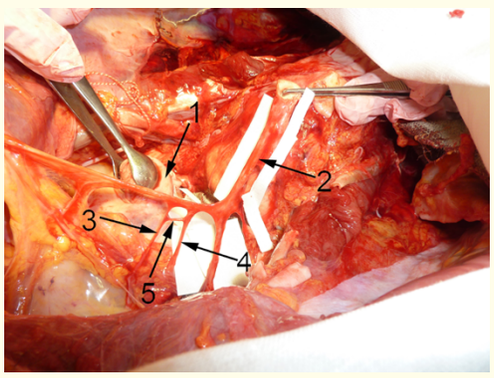

Figure 2: *Arteries and anastomoses in the left half of the pelvic cavity of a 49 year old mesomorphic woman.*
1-uterus; 2-internal iliac artery; 3-inferior vesical artery; 4-uterine artery; 5-anastomose between the uterine and inferior vesical arteries.

According to the graphical image of the curvilinear trapezium obtained by us (Figure 3), which displays the distribution of extraorgan anastomoses of UtA in mesomorphic women on the right side of pelvic cavity in our sample, the area of this geometric figure can be calculated by the formula:

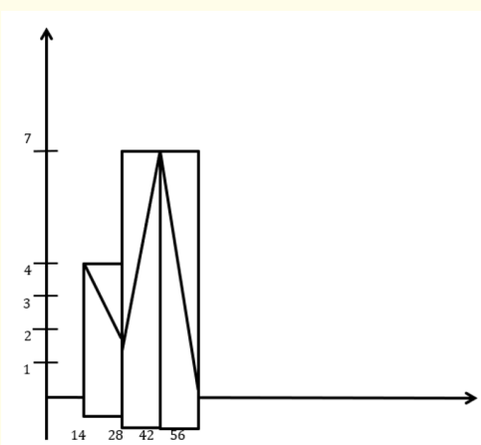

Figure 3: *Curved trapezoid showing the distribution of extraorgan anastomoses a. uterina within the sample of females of the mesomorphic somatotype on the right side of pelvic cavity.*
The abscissa axis reflects the number of corpses of women of a mesomorphic body type. The ordinate axis is the number of extraorgan anastomoses of the UtA on the right side of pelvic cavity.

$$\int_{14}^{56} 4 * 14 - 0.5 * 14 * 2 + 7 * 14 - 0.5 * 14 * 5 + 7 * 14 - 0.5 * 14 * 6$$

As a result of solving the obtained definite integral, it was found that the area of the curved trapezoid is 6762. Based on the fact that the unit of area per object of study (S1) is 114.6, and for one detected extraorgan anastomosis (S2) - 450.8, the value of the coefficient (k), which determines the frequency of occurrence of the studied arterial anastomosis UtA, equals 0.2542. According to this, the predicted number of extraorgan anastomoses a. uterina on the right side of pelvic cavity can be calculated using the formula:

X = 0.2542 * Z

Where Z is the number of mesomorphic females, and X is the number of extraorgan anastomoses UtA on the right side of pelvic cavity, which varies in proportion to the variable Z.

According to the graphical image of the curvilinear trapezium obtained by us (Figure 4), which displays the distribution of extraorgan anastomoses of UtA in mesomorphic women on the left side of pelvic cavity in our sample, the area of this geometric figure can be calculated by the formula:

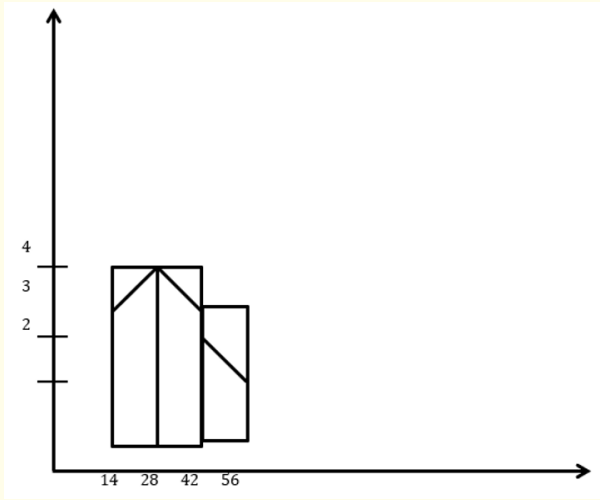

Figure 4: *Curved trapezoid showing the distribution of extraorgan anastomoses a. uterina within the sample of females of the mesomorphic somatotype on the left side of pelvic cavity.*

The abscissa axis reflects the number of corpses of women of a mesomorphic body type. The ordinate axis is the number of extraorgan anastomoses of the UtA on the left side of pelvic cavity.

$$\int_{14}^{56} 4 * 14 - 0.5 * 14 + 4 * 14 - 0.5 * 14 + 14 * 3 - 0.5 * 14$$

As a result of solving the obtained definite integral, it was found that the area of the curved trapezoid is 5796. Based on the fact that the unit of area per object of study (S1) is 98.2, and for one detected extraorgan anastomosis (S2) - 483, the value of the coefficient (k), which determines the frequency of occurrence of the studied arterial anastomosis UtA, equals 0.2029. According to this, the predicted number of extraorgan anastomoses a. uterina on the left side of pelvic cavity can be calculated using the formula:

$X = 0.2029 * Z$

Where Z is the number of mesomorphic females, and X is the number of extraorgan anastomoses UtA on the left side of pelvic cavity, which varies in proportion to the variable Z.

Discussion

Prevention of the recanalization of endovascular emboli remains an urgent issue in modern surgery [10]. This problem is closely related to the influence of the work of the anastomotic bed on the destruction of an embolus located with a therapeutic purpose in the lumen of any artery. It should be noticed that the size of the diameter of the arterial anastomoses and their number directly affect the recanalization of the therapeutic embolus [11].

It should be emphasized that in the specialized literature there are no data on the patterns of the topography of extraorgan anastomoses of the a. uterina. The data in specialized sources are reduced just to listing the anastomotic branches of the UtA. In our study was detected that the extraorgan arterial anastomoses of the UtA in mesomorphic somatotype women are most often found in the proximal and middle thirds of this artery. Much less often, the formation of these anastomosis is noted in the distal third of a. uterina.

Based on the data obtained, it should be emphasized that the most common locations of extraorgan anastomoses of the UtA are the proximal and middle third of this artery. From this it follows that for the prevention of secondary bleeding in the postoperative period the above-mentioned sections of this artery must be excluded from the bloodstream.

One of the most effective surgical techniques in this case is endovascular embolization of the UtA with the placement of several titanium coils throughout the proximal and middle thirds of a. uterina. In this case, several emboli will be formed inside the UtA in precisely those areas of this vessel that can potentially lead to bleeding after surgery if they are not occluded.

The accuracy of the calculations of the proposed mathematical model was verified using the proportion method. It was found that the difference between the results obtained (model and proportion method) laid within 0.1 - 0.2 units of calculation, which is not a statistically significant difference between the obtained variables.

Conclusion

The proposed algorithm for quantitative assessment of the extraorgan anastomoses of UtA in mesomorphic women predicts their number with a high degree of probability depending on the change in sample size. Proximal two thirds of the UtA in mesomorphic women form more than 90% of extraorgan anastomoses of this artery.

Limitations of the Study and Strengths

Studies were performed on a limited sample of mesomorphic women. However, the proposed algorithm for quantitative assessment of extraorgan anastomoses of UtA allows predicting the change in their number depending on the sample size.

Conflict of Interest

None.

Authors' Contributions

Kuzmenko A.V.: Conceptualization, Methodology, Software, Validation, Formal analysis, Investigation, Resources, Writing - Original Draft, Writing - Review & Editing, Visualization, Project administration.

Funding Support

None.

Ethics Approval and Consent

The obtained material was collected in accordance with the legislation of the Republic of Belarus and approved by the Ethics Committee of the Gomel state medical university.

Bibliography

1. Moss J and Christie A. "Uterine artery embolization for heavy menstrual bleeding". *Women's Health* 12.1 (2016): 71-77.
2. Zhang XQ., *et al*. "The emergent pelvic artery embolization in the management of postpartum hemorrhage: a systematic rewiew and meta-analysis". *Obstetrical and Gynecological Survey* 74.4 (2021): 234-244.
3. Chen CH., *et al*. "Recent update of embolization of postpartum hemorrhage". *Korean Journal of Radiology* 19.4 (2018): 585-596.
4. Niekamp A., *et al*. "Palliative embolization for refractory bleeding". *Seminars in Interventional Radiology* 34.4 (2017): 387-397.
5. Chung Y., *et al*. "Development of a model for the prediction of treatment response of uterine leiomyomas after uterine artery embolization". *International Journal of Medical Sciences* 15.14 (2018): 1771-1777.
6. Kim M. "Uterine artery embolization for leiomyomas and adenomyosis: a pictorial essay based on our experience from 1300 cases". *Korean Journal of Radiology* 20.10 (2019): 1462-1473.
7. Kim T., *et al*. "Management of bleeding uterine arteriovenous malformation with bilateral uterine artery embolization". *Yonsei Medical Journal* 55.2 (2014): 367-373.
8. Hoffer EK. "Transcatheter embolization in the treatment of hemorrhage in pelvic trauma". *Seminars in Interventional Radiology* 25.3 (2008): 281-292.
9. Selcuk I., *et al*. "Anatomic structure of the internal iliac artery and its educative dissection for peripartum and pelvic hemorrhage". *Turkish Journal of Obstetrics and Gynecology* 15.2 (2018): 126-129.
10. Winship IR., *et al*. "Augmenting collateral blood flow during ischemic stroke via transient aortic occlusion". *Journal of Cerebral Blood Flow and Metabolism* 34.1 (2014): 61-71.
11. Lindquist JD and Vogelzang RL. "Pelvic artery embolization for treatment of postpartum hemorrhage". *Seminars in Interventional Radiology* 35.1 (2018): 41-47.

Volume 12 Issue 2 February 2023