

## The Role of Dopplerography in Assessing the Life Activity of the Fetus and Threatened Abortion in the First Trimester of Pregnancy

**Abdullaiev R Ya\***

*Kharkov Medical Academy of Postgraduate Education, Ukraine*

**\*Corresponding Author:** Abdullaiev R Ya, Kharkov Medical Academy of Postgraduate Education, Ukraine.

**Received:** May 08, 2020; **Published:** March 29, 2021

### Abstract

Most often, abortions occur at 8 - 11 weeks. Ultrasonography is the main method for predicting the threat of termination of pregnancy and diagnosing fetal death. The article shows the role of ultrasonography in the diagnosis of the pathological course of pregnancy among women who have a clinical suspicion of threatened abortion.

Registration of cardiac activity is very important for assessing the vital activity of the fetus. Already at 6 weeks in the Doppler mode, it is possible to register the number of heartbeats, which is 110 beats per minute. A heart rate of less than 100 beats/min during 7 - 8 weeks of pregnancy may be an unfavorable prognostic factor.

Another sign of a threatened abortion is the absence of an image of the yolk sac and hypoplasia of the amniotic cavity after 6 weeks of gestation. Localized thickening of the myometrium is often correlated with lower back pain. The real threat of termination of pregnancy arises with a local thickening of the myometrium on the side under the forming placenta

**Keywords:** *Dopplerography; Life Activity; Fetus; Threatened Abortion; Pregnancy*

Complications in early pregnancy are the most common reasons a woman seeks medical help [1]. These events peak between 8 and 11 weeks of gestation. Ultrasonography is integral to assessing such women, and the transvaginal approach is now standard. Accurate diagnosis is important, as the potential damage from inappropriate intervention after improper ultrasound evaluation in early pregnancy can have serious consequences [2].

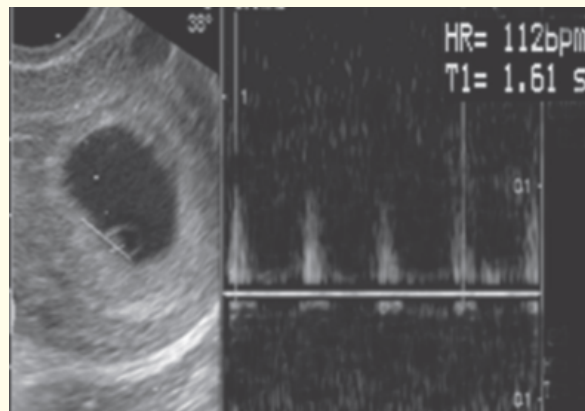
The definition of a threatened abortion defined by the World Health Organization (WHO) is pregnancy-related bloody vaginal discharge or frank bleeding during the first half of pregnancy without cervical dilatation. Threatened abortion can present during early pregnancy with lower abdominal pain and/or vaginal bleeding. Nearly 25% of pregnant women have some degree of vaginal bleeding during the first two trimesters and about 50% of these progress to an actual abortion. More than half of threatened abortions will abort. The risk of spontaneous abortion, in a patient with a threatened abortion, is less if fetal cardiac activity is present [3-6].

It is very important to timely identify the threat of abortion, when a pregnant woman has pain in the lower back or abdomen, but so far there is no bloody discharge from the vagina. Transvaginal ultrasound may be used to locate the pregnancy and determine if the fetus is viable.

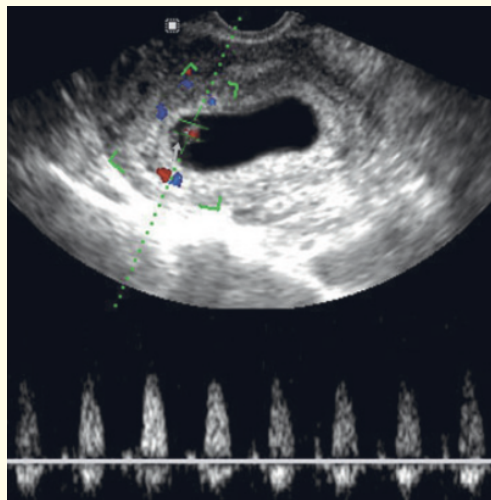
**Dopplerographic assessment of the fetus life activity**

Assessment of the vital activity of the embryo includes the determination of its cardiac activity and motor activity. Registration of cardiac activity is possible from the beginning of the 6<sup>th</sup> week of pregnancy. The best way to record cardiac activity is the Doppler mode. The heart rate (HR) increases between the 5<sup>th</sup> week of gestation and 9<sup>th</sup> week of gestation and after the 13<sup>th</sup> week of gestation reduces.

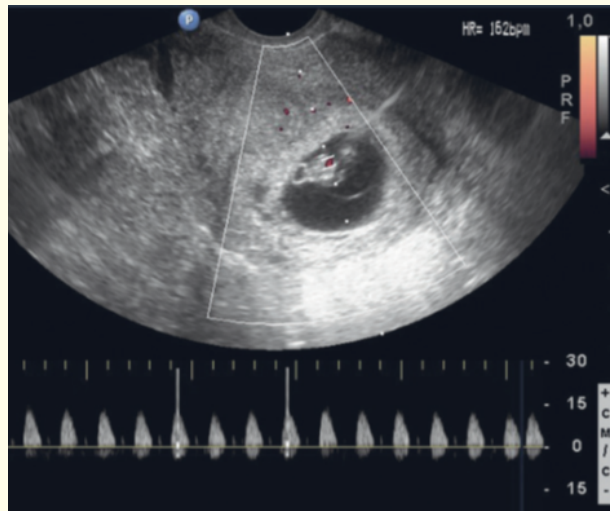
With an uncomplicated pregnancy, the heart rate gradually increases, at 5 weeks it exceeds 110 beats, and by 9 - 10 weeks it can increase to 200 beats/min, but after 10 weeks it begins to decrease (Figure 1-3). A heart rate of less than 100 beats/min during 7 - 8 weeks of pregnancy may be an unfavorable prognostic factor (Figure 4).



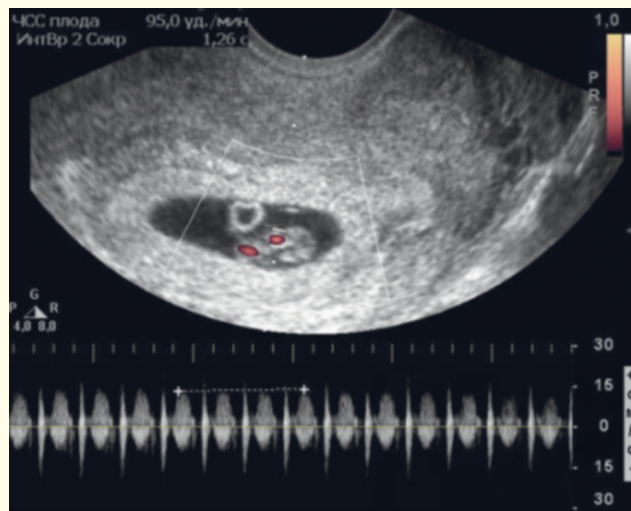
**Figure 1:** Registration of cardiac activity of the embryo with a gestational age of 5 weeks. Heart rate is 112 beats/min.



**Figure 2:** Pregnancy of 5 weeks and 2 days. In color and pulsed Doppler modes, the cardiac activity of the embryo is recorded.



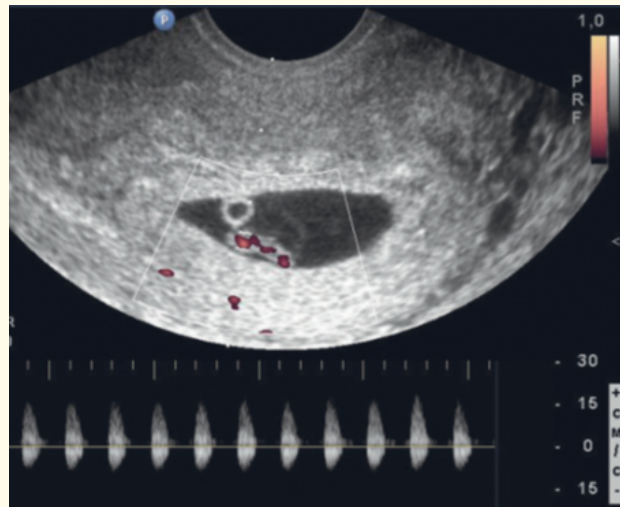
**Figure 3:** Registration of cardiac activity of the embryo with a gestational age of 7 - 8 weeks. Heart rate is 162 beats/min.



**Figure 4:** Pregnancy of 7 weeks and 3 days. The heart rate is 95 beats/min. After 3 days, the embryo died.

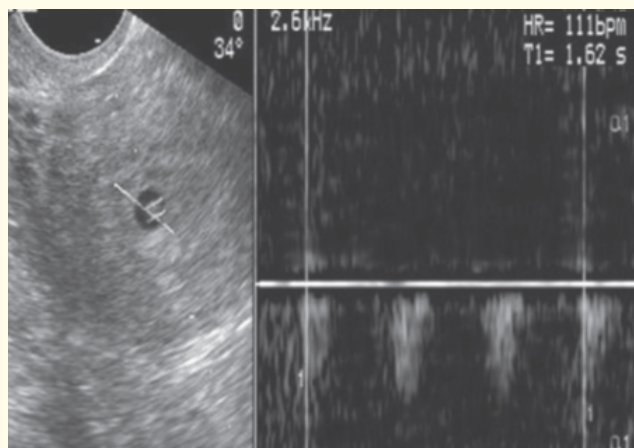
In the normal course of pregnancy, the yolk sac is visualized in all cases if the average size of the ovum exceeds 10 mm. In the period of 6 - 8 weeks of pregnancy, the diameter of the yolk sac does not exceed 4 mm, by the 10<sup>th</sup> week it increases slightly and can reach 7 mm, and then begins to decrease in size. Often the absence of an ultrasound image of the yolk sac by the 7<sup>th</sup> week is accompanied by spontaneous miscarriage. In addition, his premature disappearance can also be an unfavorable sign of an undeveloped pregnancy.

With the physiological development of pregnancy after 6 weeks, it is possible to register blood flow in the vessels of the yolk sac of venous and arterial types (Figure 5). In cases of non-developing pregnancy, only venous blood flow can be recorded or it is completely absent. The absence of an image of the yolk sac with an average fetal egg size of more than 10 mm may indicate an undeveloped pregnancy, a sign of which may be premature disappearance of the yolk sac. There is some correlation between the size of the yolk sac and the course of pregnancy: for example, with small (less than 2 mm) and large (more than 7 mm) sizes of the yolk sac, the frequency of an undeveloped pregnancy or spontaneous miscarriage increases.



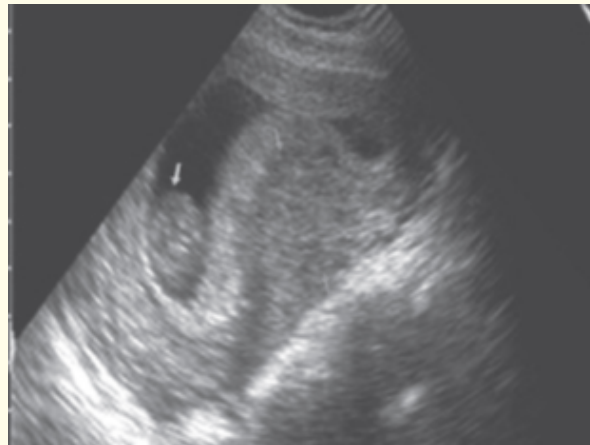
**Figure 5:** Registration of blood flow in the vessels of the vitelline duct in color and pulsed Doppler modes.

Usually, the growth of the embryo and the average size of the ovum occurs synchronously. For example, with a period of 6 weeks of pregnancy, the average size of the fetal egg is 16 - 18 mm, and the length of the embryo is on average about 4 mm, and with a period of 8 weeks it is 26 - 27 mm and 17 - 18 mm, respectively. Hypoplasia of the amniotic cavity often leads to an undeveloped pregnancy and spontaneous miscarriage (Figure 6).

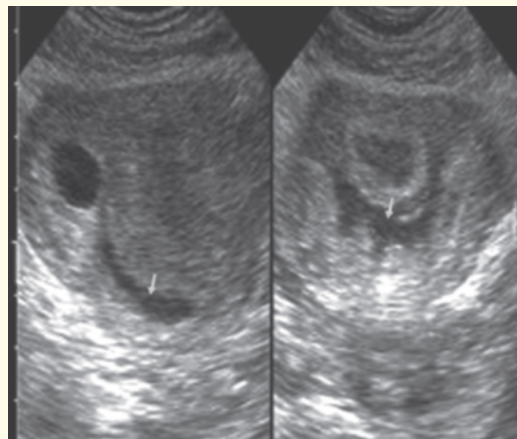


**Figure 6:** Hypoplasia of the amniotic cavity in a pregnant woman with spontaneous miscarriage with a gestation period of 6 weeks. The average size of the fetal egg with a gestational age of 6 weeks is less than 10 mm. The reduced heart rate is determined - 111 beats/min.

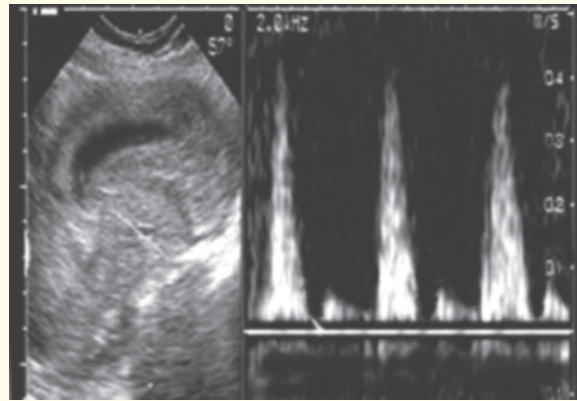
With a clinical suspicion of threatened abortion, a transvaginal examination is needed very carefully, avoiding the mechanical impact of the sensor on the cervix. The most frequent variants of the threat of termination of pregnancy include a local thickening of the myometrium, corresponding to its local hypertonicity and the associated appearance of invagination of this area towards the gestation sac. Spontaneous miscarriages more often occur with the development of myometrial hypertonicity under the forming placenta. In addition, the localization of the embryo is also important, since the location of the embryo closer to the internal cervical os is more dangerous than in the bottom of uterus. In the presence of a subchorial hematoma, the threat of interruption increases. In such cases, you need conduct dynamic ultrasound monitoring of the result of treatment (Figure 7-11).



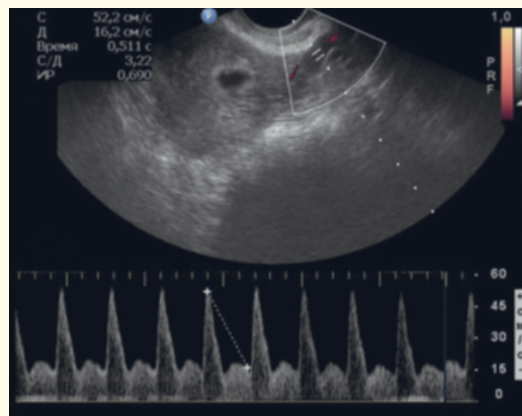
**Figure 7:** The threat of termination of pregnancy for a gestation of 7-8 weeks. The right arrows show a significant thickening of the myometrium under the emerging placenta, the left arrow is the embryo located closer to the cervix.



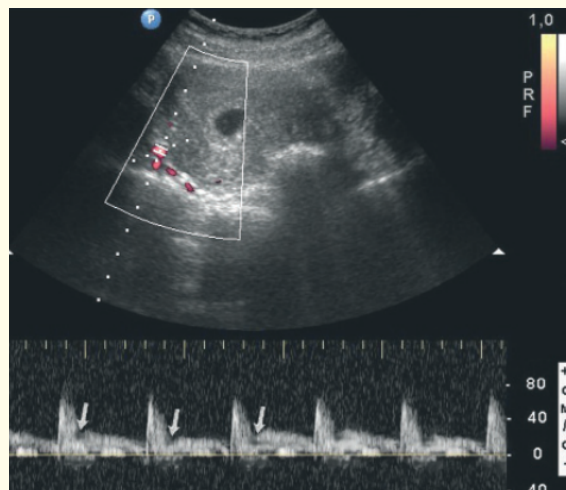
**Figure 8:** Pregnancy of 5 weeks. The arrows show the retrochorial hematoma in longitudinal and cross sections in the form of an anechoic zone of irregular shape.



**Figure 9:** The Doppler spectrum was obtained from the arcuate artery in the area of local thickening of the myometrium in a pregnant woman with a spontaneous miscarriage at a gestational age of 4 - 5 weeks. The gestation sac is deformed. In the early diastole of the Doppler spectrum, a deep notch is determined.



**Figure 10:** Normal Doppler spectrum of blood flow obtained from the left uterine artery during uncomplicated pregnancy with gestation age of 4 - 5 weeks. High diastolic blood flow velocity is noted.



**Figure 11:** Registration of blood flow from the right uterine artery in a pregnant woman with spontaneous miscarriage in the gestation period of 4 - 5 weeks. Arrows show deep notch in early diastole.

## **Conclusion**

Ultrasonography in B and Doppler modes allows you to diagnose the threat of termination in the first trimester of pregnancy both in the presence of clinical suspicions and among women without any complaints during screening studies.

## **Bibliography**

1. Maya Al-Memar, *et al.* "The role of ultrasonography in the diagnosis and management of early pregnancy complications". *The Obstetrician and Gynaecologist* 17 (2015): 173-181.
2. Barnhart KT. "Early pregnancy failure: beware the pitfalls of modern management". *Fertility and Sterility* 98 (2012): 1061-1065.
3. Karataşlı V, *et al.* "Maternal and neonatal outcomes of adolescent pregnancy". *Journal of Gynecology Obstetrics and Human Reproduction* 48.5 (2019): 347-350.
4. Hendriks E., *et al.* "First Trimester Bleeding: Evaluation and Management". *American Family Physician* 99.3 (2019): 166-174.
5. Goodarzi P, *et al.* "Therapeutic abortion and ectopic pregnancy: alternative sources for fetal stem cell research and therapy in Iran as an Islamic country". *Cell Tissue Bank* 20.1 (2019): 11-24.
6. Boiko VI., *et al.* "The problem of miscarriage in multiple pregnancy". *Wiadomości Lekarskie* 71.7 (2018): 1195-1199.

**Volume 10 Issue 4 April 2021**

**©All rights reserved by Abdullaiev R Ya.**