

## The Role of Laparoscopy in the Diagnosis and Treatment of Ectopic Pregnancy in Tubal Remnant Stump; A Case Report

Kršić V\*, Jovanović D and Jocić-Pivač B

GAK Narodni Front, Belgrade, Serbia

\*Corresponding Author: Kršić V, GAK Narodni Front, Belgrade, Serbia

Received: November 23, 2020; Published: February 27, 2021

### Abstract

**Aim:** We would like to present an unusual case of a ectopic pregnancy (EP) in the stump of remnant Fallopian tube after assisted reproductive technology IVF/ET.

**Case Report:** A 30-years-old woman (gravida-2, para0) was followed in pur hospital after she underwent assisted reproductive technology IVF/ET to see success of the treatment. She had medical history with experienced of two ectopic pregnancies. The first one was 4 years ago, on the right Fallopian tube (FT) after intrauterine insemination (IUI) and the treatment was incision right tube and expression ovum by laparoscopy. The second EP was located in the left FT, one year later, again after IUI. We performed left salpingectomy by laparoscopy. Between this two EP she had conizatio of cervix uteri because of cervical intraepithelial neoplasia III. The third laparoscopy was because of hydrosalpinx on right FT and we performed right salpingoneostoma. One year later she underwent IVF/ET.

**Results:** The serum level of human chorionic gonadotropin (beta HCG) was 6,0 IU/ml 20th days of embryotranfer (ET), 30 IU /ml 25th days of ET, 127 IU /ml 30th days, 900 IU/ml 33th days and 1500 IU/ml 40th days of ET. Transvaginal ultrasound (TVS) examination revealed no sign of intrauterine pregnancy without free fluid in the sac of Douglas. The endometrium was thick and patients had no vaginal bleeding and abdominal pain. The full blood count and vital signs were normal. We suspected on cornual pregnancy and performed lparoscopy which showed intact EP on the left side in the tubal remnant sump. We removed residual stump with ectopic pregnancy and removed right FT. Pathologic confirmed present of trophoblastic tissue.

**Conclusion:** The prevalence of EU ranges from 6 to 16% in general population. Most of them are in FT (95%). All medical assisted procreatin techniques increased risk for EU. Thus, the possibility of EU should be considered even after bilateral salpingectomy. Through this rare case we can see the big role of laparoscopy as the most effective treatment for this patients who unfortunately had 3 EU. Laproscopy, at least, enable such patients fast recovery with minimal scarves of operation. Nowadays, we are preparing this patient for second attempt IVF/ET and hope it will be successfully with live birth child.

**Keywords:** Ectopic Pregnancy; Laparoscopy; IVF/ET

### Introduction

Ectopic pregnancy is defined as the implantation and development of an embryo outside the uterus [1]. Ectopic pregnancy occurring in the remnant tube after ipsilateral salpingectomy is assumed to be rare. Ectopic pregnancy is a major gynecologic emergency occurring in 1% to 2% of all pregnancies [1,2]. The incidence of ectopic pregnancy has increased over recent decades, which is partly due to the

increased prevalence of sexually transmitted infections and the use of assisted reproductive technique (ART). However, ectopic pregnancy in the remnant tube after ipsilateral salpingectomy is rare and usually associated with reproductive techniques, being less likely to occur after natural conception. The unique anatomic location of the tubal stump pregnancy sometimes results in delayed diagnosis. Transvaginal ultrasound is the only method which help to diagnosed this problem (Figure 1). The risk of rupture of the uterus tends to increase beyond 12 weeks of amenorrhea and the rupture of the ectopic part occurs in 20% of ectopic pregnancies beyond 12 weeks of gestational age [3]. Developing better methods for earlier diagnosis would decrease morbidity and increase the chance of successful laparoscopic surgery.

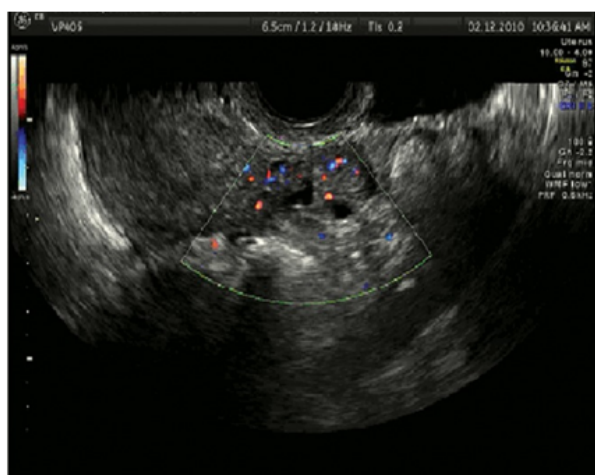

Figure 1: Ultrasound and peripheral vascularization.

In this paper, we present the case of a patient with tubal stump pregnancy. The patient underwent successful laparoscopic surgery and experienced an uneventful recovery.

### Case Report

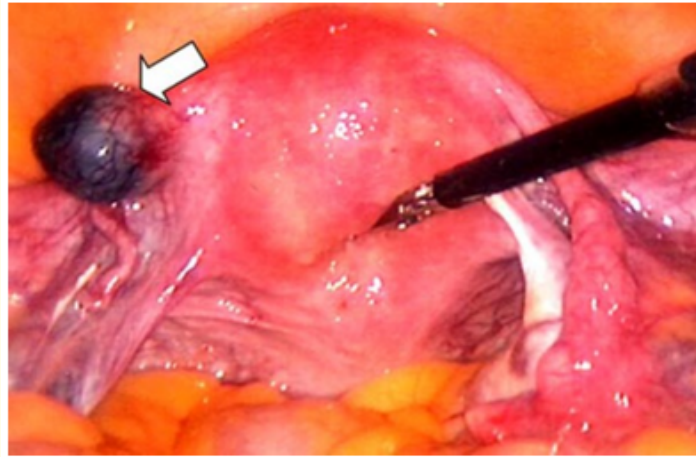
A 30-years-old woman (gravida-2, para0) was followed in our hospital after she underwent assisted reproductive technology IVF/ET to see success of the treatment. She had medical history with experienced of two ectopic pregnancies. The first one was 4 years ago, on the right Fallopian tube (FT) after intrauterine insemination (IUI) and the treatment was incision right tube and expression ovum by laparoscopy. The second EP was located in the left FT, one year later, after IUI.

We performed left salpingectomy by laparoscopy. Between this two EP she had conisatio of cervix uteri because of high cervical intraepithelial neoplasia, stadium III. The third laparoscopy was because of hydrosalpinx on right FT and we performed right salpingoneostomia. One year later she underwent IVF/ET.

On the 14<sup>th</sup> day after embryo transfer the serum level of human chorionic gonadotropin (beta HCG) was 6,0 IU/ml. Although value of human chorionic gonadotropin was just little higher than normal limits we repeated on 25<sup>th</sup> days of ET and value of beta HCG was 30 IU/ml. Transvaginal ultrasound examination revealed no sign of intrauterine pregnancy without free fluid in the sac of Douglas. Value of beta HCG were; 127 IU/ml 30<sup>th</sup> days, 900 IU/ml 33<sup>th</sup> days and 1500 IU/ml 40<sup>th</sup> days of ET. Transvaginal ultrasound examination still revealed no sign of intrauterine pregnancy without free fluid in the sac of Douglas. The endometrium was thick and patients had no vaginal bleeding

and abdominal pain. The full blood count and vital signs were normal. Her vital signs were stable and a physical examination revealed diffuse lower abdominal tenderness with no signs of peritoneal irritation. Her hemoglobin level was 11.8 mg/dL.

We suspected on cornual pregnancy and performed laparoscopy which showed intact EP on the left side in the tubal remnant stump (Figure 2). We removed residual stump with ectopic pregnancy and right salpingectomy because right tuba was obturated. Pathologic examination of the excised tubal stump revealed trophoblastic tissue.



**Figure 2:** Isthmic pregnancy in the remnant tube (arrow) during laparoscopic surgery.

### Discussion

The prevalence of ectopic pregnancy ranges from 6 to 16% in the general population. The overall incidence has increased dramatically in the last two decades due to an increase in pelvic inflammatory disease and the introduction of medical assisted procreation techniques. Other risk factors are: previous ectopic pregnancy (15%), tubal diseases and surgery, Diethylstilbestrol (DES) exposure during pregnancy, intrauterine contraception, infertility, multiple sexual partners, and smoking [1]. Recently IVF treatments have become more frequent due to increased maternal age at first pregnancy. ART represent an independent risk factor for ectopic and heterotopic pregnancies. The rate of heterotopic pregnancy (the simultaneous occurrence of intrauterine and ectopic gestation) after IVF is estimated to be as high as 0.3 - 1% [3].

Almost all ectopic pregnancies occur in the Fallopian tube (95%), with the distribution of sites being: ampullary (76.9%), isthmic (12%), and fimbria (11.1%). Ectopic pregnancies are ovarian (2%), interstitial or cornual (2%), and the remaining are abdominal or cervical [4].

Risk factors for interstitial pregnancies are similar to those for other tubal pregnancies [5], particularly salpingectomy [6-9]. IVF treatments are also strongly associated with interstitial pregnancies (26.9%) [10-12].

The occurrence of interstitial pregnancy is estimated to be 1:3600 for all pregnancies achieved with IVF treatments. These pregnancies trend to be diagnosed later than most other ectopic pregnancies, as interstitial pregnancies can grow larger because the surrounding myometrium is more expandable than within the fallopian tube. Consequently, interstitial pregnancies have an increased risk of rupture

and early diagnosis is very important. In Buyer's study, almost one third of cornual ectopic pregnancies have been diagnosed after rupture with a significant hemoperitoneum. The typical rupture of these ectopic pregnancies occurs after 9 weeks and as late as 20 weeks [4].

Exact incidence of ectopic pregnancy occurring in the remnant tube after ipsilateral salpingectomy is not known; however, Takeda reported an incidence of 1.16% in their department [16]. Several possible mechanisms have been described for a recurrent ipsilateral ectopic pregnancy after previous salpingectomy. One theory explains that spermatozoa pass through the patent tube into the pouch of Douglas, then travel to fertilize the ovum on the side of the diseased tube. The fertilized ovum then implants on the stump of previous ectopic site. A second theory suggests transperitoneal passage of the fertilized egg through the contralateral intact uterine tube. A third theory says despite ligation, luminal remain intact in the interstitial portion and distal remnant of the Fallopian tube. This allows communication between the endometrial and peritoneal cavities and thus migration of the fertilized ovum or spermatozoa from the endometrial cavity to the distal remnant of Fallopian tube [17,18]. In our case, because the distal end of the remnant tube was closed and the corpus luteum was in the ovary on the opposite side of the ectopic tube, it is conceivable that after ovulation from the contralateral ovary, an oocyte may have been normally fertilized in the tube and later taken up to the remnant tube by intrauterine transmigration [16]. Because of its rarity, the possibility to prevent this type of ectopic pregnancy is unknown. Therefore, to decrease the risk of recurrence, care should be taken not to leave a long stump when performing salpingectomy for ectopic pregnancy.

These ectopic pregnancy locations are associated with increased risk of rupture and severe bleeding at an early gestational age, because of the decreased ability of distention of the interstitial part of the uterine tube and increased vascularity of this area. While the overall mortality rates for ectopic pregnancies over the past five decades have steadily decreased to 0.14%, the case mortality rate for interstitial pregnancies remains at 2.0% to 2.5% [8].

A TVUS is the most useful test in determining the location of an EP, despite some studies that describe the use of magnet resonance imaging (MRI) in diagnosing a pregnancy in a rudimentary horn [13,14]. In our routine clinical practice MRI is not useful so we could not use MRI as a diagnostic approach. However, imaging studies might not be diagnostic, as gestation is too early to be visualized. In this setting, the combination of TVUS and beta-HCG can achieve diagnosis in almost 70% of cases [11,15].

This article underlines the importance of total salpingectomy and accurate cauterization of the tubal stump in patients undergoing surgery for ectopic pregnancy in the Fallopian tube in order to avoid the risk of a consequent interstitial pregnancy or in remnant stump. Particular attention must be taken in women undergoing IVF treatment

In fact, whether or not ART is scheduled, the chances of an embryo spontaneously implanting at the corn or at the residual tubal stump are probably higher in such case. We stress that whenever there is a history of prior salpingectomy and at least 1 normal functioning ovary remains, careful ultrasound monitoring should be provided from the early stages.

### Conclusion

A 30-years-old woman (gravida-2, para0) was followed in our hospital after she underwent assisted reproductive technology IVF/ET to see success of the treatment. She had medical history with experienced of two ectopic pregnancies. The first one was 4 years ago, on the right Fallopian tube (FT) after intrauterine insemination (IUI) and the treatment was incision right tube and expression ovum by laparoscopy.

### Bibliography

1. Farquhar CM. "Ectopic pregnancy". *Lancet* 366 (2005): 583-591.
2. Rajkhowa M., et al. "Trends in the incidence of ectopic pregnancy in England and Wales from 1966 to 1996". *BJOG: An International Journal of Obstetrics and Gynaecology* 107 (2000): 369-374.

3. Strandell A., *et al.* "Risk factors for ectopic pregnancy in assisted reproduction". *Fertility and Sterility* 71.2 (1999): 282-286.
4. Bouyer J., *et al.* "Sites of ectopic pregnancy: a 10-year population-based study of 1800 cases". *Human Reproduction* 17.12 (2002): 3224-3230.
5. Moawad NS., *et al.* "Current diagnosis and treatment of interstitial pregnancy". *American Journal of Obstetrics and Gynecology* 202.1 (2010): 15-29.
6. Okohue JE., *et al.* "Ectopic pregnancy following in vitro fertilization and embryo transfer". *West African Journal of Medicine* 29.5 (2010): 349-351.
7. Sturlese E., *et al.* "Ectopic pregnancy in tubal remnant stump after ipsilateral adnexectomy for cystic teratoma". *Archives of Gynecology and Obstetrics* 280.6 (2009): 1015-1017.
8. Lau S and Tulandi T. "Conservative medical and surgical management of interstitial ectopic pregnancy". *Fertility and Sterility* 72.2 (1999): 207-215.
9. Chen CD., *et al.* "Cornual pregnancy after IVF-ETA report of three cases". *The Journal of Reproductive Medicine* 43.4 (1998): 393-396.
10. Soriano D., *et al.* "Laparoscopic treatment of cornual pregnancy: a series of 20 consecutive cases". *Fertility and Sterility* 90.3 (2008): 839-843.
11. Tulandi T and Al-Jaroudi D. "Interstitial pregnancy: results generated from the Society of the Reproductive Surgeons Registry". *Obstetrics and Gynecology* 103.1 (2004): 47-50.
12. Agarwal SK., *et al.* "Cornual pregnancies in patients with prior salpingectomy undergoing in vitro fertilization and embryo transfer". *Fertility and Sterility* 65.3 (1996): 659-660.
13. Zuzarte R and Khong CC. "Recurrent ectopic pregnancy following ipsilateral partial salpingectomy". *Singapore Medical Journal* 46 (2005): 476-478.
14. Milingos DS., *et al.* "Three surgically managed ipsilateral spontaneous ectopic pregnancies". *Obstetrics and Gynecology* 112 (2008): 458-459.
15. Filhastre M., *et al.* "Interstitial pregnancy: role of MRI". *European Radiology* 15.1 (2005): 93-95.
16. Bourdel N., *et al.* "Interstitial Pregnancy. Ultrasonographic diagnosis and contribution of MRI. A case report". *Gynaecology Obstetrics Fertility* 5.2 (2007): 121-124.
17. Ng S., *et al.* "Laparoscopic management of 53 cases of cornual ectopic pregnancy". *Fertility and Sterility* 92.2 (2009): 448-452.
18. Takeda A., *et al.* "Spontaneous ectopic pregnancy occurring in the isthmic portion of the remnant tube after ipsilateral adnexectomy: report of two cases". *Journal of Obstetrics and Gynaecology Research* 32.2 (2006): 190-194.

**Volume 10 Issue 3 March 2021**

**© All rights reserved by Kršić V., *et al.***