

## Possibilities of X-Ray Tomosynthesis in the Diagnostics of Breast Diseases the Glands in the Auxiliary Program Reproductive Technologies

D Belotserkovtseva, NV Klimova\* and ZO Sarsebaeva

Surgut State University KhMAO-Yugra, Surgut, Russia

\*Corresponding Author: NV Klimova, Surgut State University KhMAO-Yugra, Surgut, Russia.

Received: August 23, 2019; Published: August 29, 2019

### Abstract

**Objective:** To study diagnostic potential of tomosynthesis in pathological changes of breast tissue in the reproductive technologies programme.

**Patients and Methods:** We analysed the results of examination of 220 women aged 35 to 45 years with various pathological changes in breast tissue, who received treatment under the assisted reproductive technologies programme (ART). 180 (81.8%) patients were examined prospectively, 40 (18.2%) -5 years after *in vitro* fertilisation (IVF). X-ray examination was performed in the combined mode: standard mammography and 3D-mammography - "TOMO" + "COMBO".

**Results:** We found the following nosologies of breast diseases: mastopathy with dysplastic changes - 89 (40.5%); fibroadenomas - 34 (15.5%), fibrolipomas - 18 (8.2%), cysts and polycystosis - 67 (30.5%). Unlike mammography, the tomosynthesis mode permitted to specify the character of contours of non-palpable masses. In general, the sensitivity of tomosynthesis was 98.5%, of mammography - 97.0%, specificity - 89.0 and 85.0%, respectively.

**Conclusion:** The use of tomosynthesis in x-ray diagnosis of breast lesions in women of late reproductive age broadens possibilities, enhances the informativity of determining nodular masses, alleviates search for microcalcifications, improving differential diagnosis of breast diseases. Key words: assisted reproductive technologies, breast disease, search for microcalcifications, tomosynthesis.

**Keywords:** X-Ray Tomosynthesis; Breast Diseases; Glands

### Relevance

Breast diseases are diagnosed in 75 - 80% of women of reproductive age. Moreover, it has been substantially proven that in neuroendocrine diseases the mammary gland is involved in the pathological process in 97.8% of observations [1]. As you know, benign breast diseases are considered as a leading risk factor for breast cancer. Currently, digital technologies and digital mammography are priority methods in the diagnosis of breast diseases. With the transition to digital mammography, radiologists were able to independently obtain and adjust the necessary image characteristics of breast tissue structures on the monitor. Options such as magnification, inversion and clear visualization of clustered calcinates with the help of the microcalcine search module appeared, which significantly increased the diagnostic value of the method and raised to a qualitatively new level the organization of the mammological service. However, there are difficulties in interpreting the image of a volumetric object due to the superposition of tissue structures located in different planes, which leads to the need for additional styling and aiming mammography. This disadvantage can be avoided by using a special option of tomosynthesis, which allows to perform a series of pictures with minimal compression of the mammary gland with subsequent transformation into a series of tomograms and transfer the pictures to the workstation of the radiologist [2-4].

**Citation:** NV Klimova., *et al.* "Possibilities of X-Ray Tomosynthesis in the Diagnostics of Breast Diseases the Glands in the Auxiliary Program Reproductive Technologies". *EC Gynaecology* 8.9 (2019): 868-874.

### Purpose of the Study

To study the diagnostic possibilities of tomosynthesis in pathological changes in the mammary gland in the program of reproductive technologies.

### Patients and Methods

The analysis of the results of the examination of 220 women aged 35 to 45 years with various pathological changes in the mammary gland receiving treatment under the ART program was performed. Of these, 180 (81.8%) patients were prospectively examined, 40 (18.2%) were examined 5 years after extracorporeal fertilization (IVF). The complex of diagnostic methods included: physical examination, radiological and ultrasound methods, cytological and histological examinations if necessary. The radiological examination was performed on the Selenia 3D apparatus in the combined mode (standard mammography and 3D mammogram - "TOMO" + "SOMBO" were performed with one compression). In TOMO mode, the mammogram performed a series of 15 images with the X-ray tube rotating from -7.50 to + 7.50 relative to the receiver (Figure 1). The workstation software shell displays the data obtained in three variants: a standard mammogram, a series of images of 15 mammograms made at different angles, and a series reconstruction. As a result of the reconstruction, a series of images of the mammary gland formed in parallel with the radiation receiver in 1 mm increments.

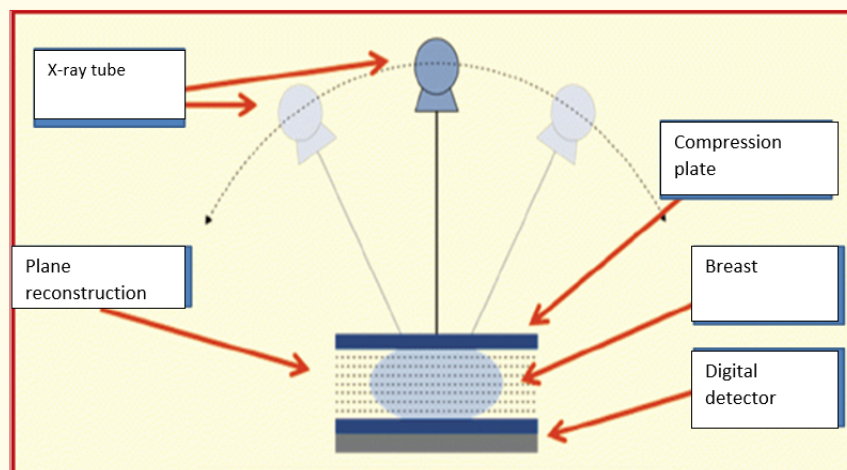


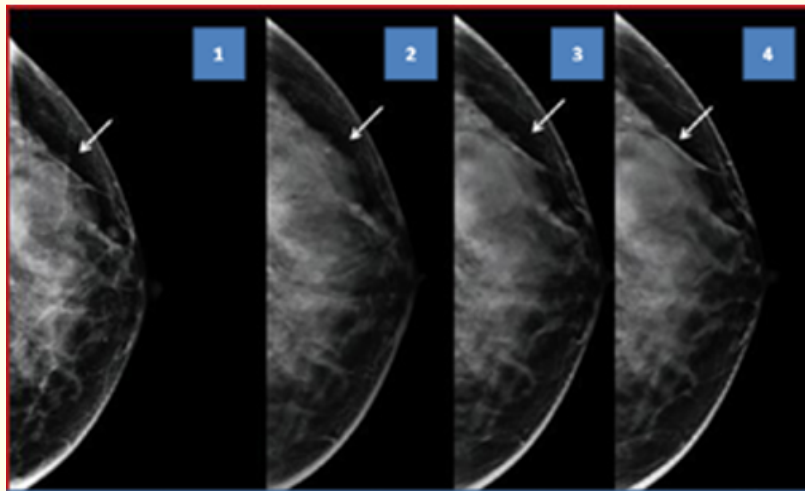
Figure 1: Taking a series of shots of the mammary gland in tomosynthesis mode.

Tomosynthesis images were taken under reduced exposure conditions with a decrease in the number of mAs (the exposure is measured by the product of the current in the x-ray tube (mA) at shutter speed (c) and expressed in milliamperere seconds (mAs)) and the same power by the x-ray diffraction. This allowed virtually no increase in the effective dose per patient when performing a series of 15 shots. The dose per breast tissue averaged both a series of tomograms and a standard 2D mode of 1.6 mGy (effective radiation dose - 0.16 mSv). All patients underwent mammograms of both mammary glands in two projections in a combined mode: sequentially in conditions of breast compression and decompression. Thus, obtaining images, we were able to work with three arrays of data of one projection of a mammary gland. When displaying a mammogram on one working monitor and reconstructed breast sections on one working monitor, it is possible to compare the images and isolate that section at the level of which the formation visible on the standard mammogram is more clearly revealed. Standard mammograms were viewed in TOMO + COMBO mode. Further, using a magnifying glass, individual areas of interest were evaluated. Two monitors were displayed first with images of both mammary glands in a straight line, then with oblique projections.

Then they went into the mode of tomosynthesis, where the program allowed us to use the same viewing tools - in the form of consecutive all sections, which gave us a small amount of CCTV on the cut frames. For statistical analysis of the obtained data, we used the STATISTICA 64 bit for Windows module package. Frequency differences were considered statistically significant at significance levels of  $p < 0.05$ ,  $p < 0.01$  (95% significance level).

### Results and Discussion

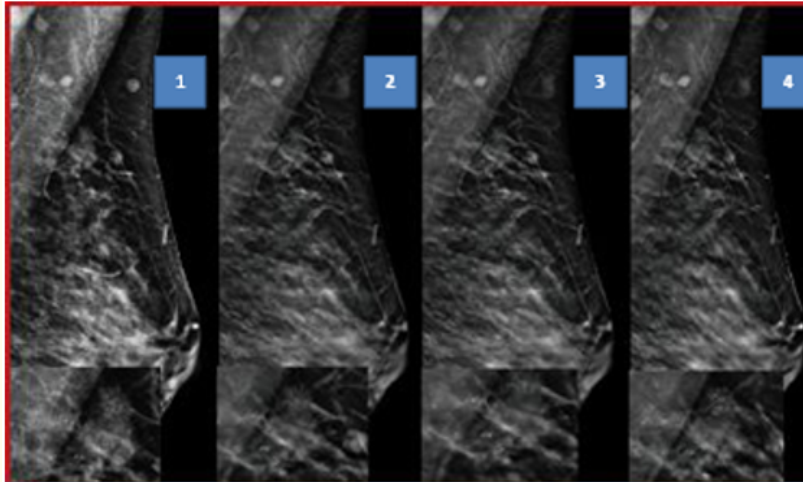
As a result of the examination of mastopathy with dysplastic changes, 89 (40.5%) women were diagnosed, in benign neoplasms; of these, 34 (15.5%) had fibroadenomas, 18 (8.2%) had fibro lipomas, 67 (30.5%) had cysts and polycystic breast disease. On standard mammograms on the background of diffuse changes, nodular formations and calcinates were detected in 85 patients (40.2%), in the mode of tomosynthesis - in 89 (40.5%). Thus, image reconstruction provided additional information to standard mammography in 9 (4.1%) patients. In 5 (2.3%) patients, structures reminiscent of severe restructuring were excluded in a series of sections because their formation was facilitated by the overlay of various structural elements of the mammary gland. In mammograms, areas suspicious of clustered microcalcines of malignant nature were identified in 7 (3.4%) patients, and in a series of sections of tomosynthesis they were diagnosed in 8 (3.5%) patients. The mode of tomosynthesis allowed to clarify the nature of the contours of the detected non-palpable formations. For example, in 13 (5.9%) women, mammograms showed formations with fuzzy and radiant contours. When viewing the layered images, the contours of these formations were clearly visualized throughout the volume, which made it possible to eliminate the infiltrative growth of tumors due to the clarity of the depicted structural elements on each (Figure 2).



**Figure 2:** Patient A., 40 years old 2D 1 and 3D (2,3,4) - layered images of tomosynthesis of the right mammary gland.

The greatest difficulties of diagnostics arise at the detection of sites of accumulation of microcalcines. The available microcalcine search module was applied to each tomographic slice of tomosynthesis, which allowed us to determine a clear localization and character of their malignant or benign nature. This sequence made it possible to visualize clustered microcalcines. In 8 women, changes in individual sections seemed more convincing, as more calcinates were visualized due to the exclusion of tissue superposition (Figure 3).

In 1 patient, on the contrary, the high density of accumulation of calcifications was caused by the imposition of two small fields of calcite of medium size, located at different sections (at different levels) (Table 1). In general, the diagnostic value of tomosynthesis exceeded that of mammography by 4.5%.



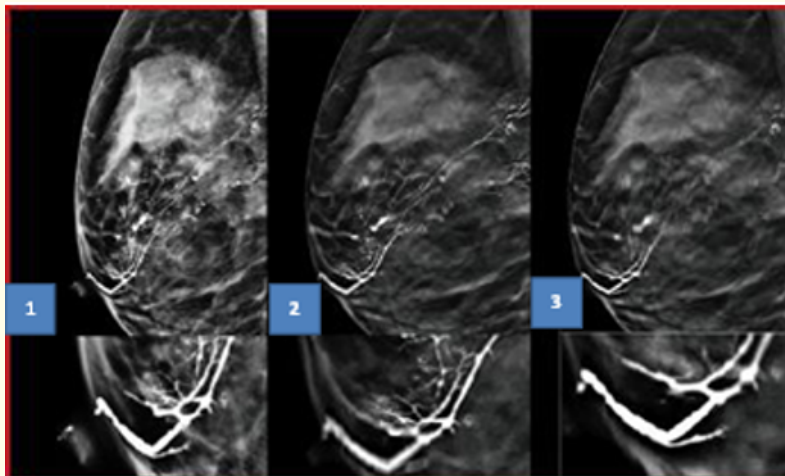
**Figure 3:** Patient T. is 42 years old. Layered scans of tomosynthesis of the right mammary gland. Grouped microcalcines. Breast cancer. 2D 1 and 3D (2,3,4) are layered images of tomosynthesis.

Pathological processes of mammary glands are revealed	Tomosynthesis		Mammography	
	Abs. number	%	Abs. number	%
Mastopathy	89	40,5	85	40,2
Nodal mastopathy	45	20,5	43	20,3
Microcalcines, of benign nature	44	20,0	42	19,8
Intra-flow pappillomas	4	1,8	3	1,4
Benign neoplasms	119	54,1	116	55,0
Fibroadenoma	34	15,5	33	15,6
Fibrolipoma	18	8,2	17	5,9
Cyst, Polycystic	67	30,5	66	33,5
Grouped microcalcines of malignant nature (BC)	8	3,5	7	3,4
Total	220	100	211	95,5

**Table 1:** Comparative evaluation of mammography imaging with tomosynthesis scans.

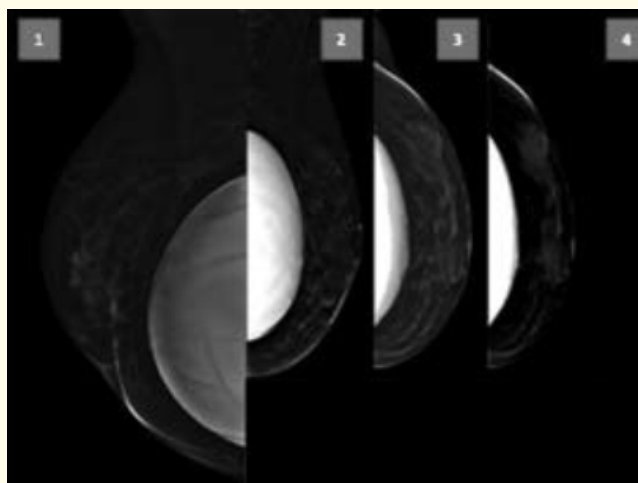
According to this table, all 220 (100%) patients underwent mammary gland tomosynthesis study, the effectiveness of this method in comparison with mammography was 4.5%, which corresponds to the data of NI. Carob [5-16].

In patients with mammary gland discharge, women were suspected of runaway (intra-ductal papilloma) 5 patients underwent ductography. Omnipak-350 was used as a contrast agent in an amount of 1 to 1.5 ml. The contrast preparation was introduced by a single galactography system with pre-bougienage of the ducts to maximize their lumen. Intra-ductal changes on a series of tomograms were detected in 4 patients, and classical ductography revealed changes in only 3 patients (Figure 4).



**Figure 4:** Patient P. is 37 years old. Dictogram of breast. 2D 1 and 3D (2,3) layered scans of tomosynthesis. Intra-flow pappillomas.

Due to the lack of effect of tissue superposition, the layer-by-layer visualization of the contours of the ducts was clearer, which revealed a greater number of filling defects in the lumen of the milk duct. The positive thing is the opportunity to see the mutual arrangement of the ducts relative to each other. This clarified the topical diagnosis of intra-ductal expansions by superimposing ducts on a two-dimensional mammogram. When analyzing images on a series of tomograms, only one duct located at the level of the given section is clearly visible in each slice. This makes it possible to detect the smallest filling defects along the high-definition wall of the 0.5 mm duct. And using the mode of a series of native images at different angles allows to evaluate the mutual arrangement of the ducts relative to each other and to explore the branching zones. In addition to all these techniques, tomosynthesis is the «gold standard» for the diagnosis and imaging of breasts with implants, as the compression plate of tomosynthesis is sparing due to the rotational capacity of the x-ray tube (Figure 5).



**Figure 5:** Patient P., 44 years. Polycystic breast disease. 2D (1) and 3D (2, 3, 4) layers of tomosynthesis. Polycystic disease

## Conclusion

Thus, the use of tomosynthesis can significantly improve the accuracy of diagnosis of breast diseases. In our studies, the sensitivity of tomosynthesis was 98.5%, mammography - 97.0%, specificity - 89.0 and 85.0%, respectively (Figure 6).

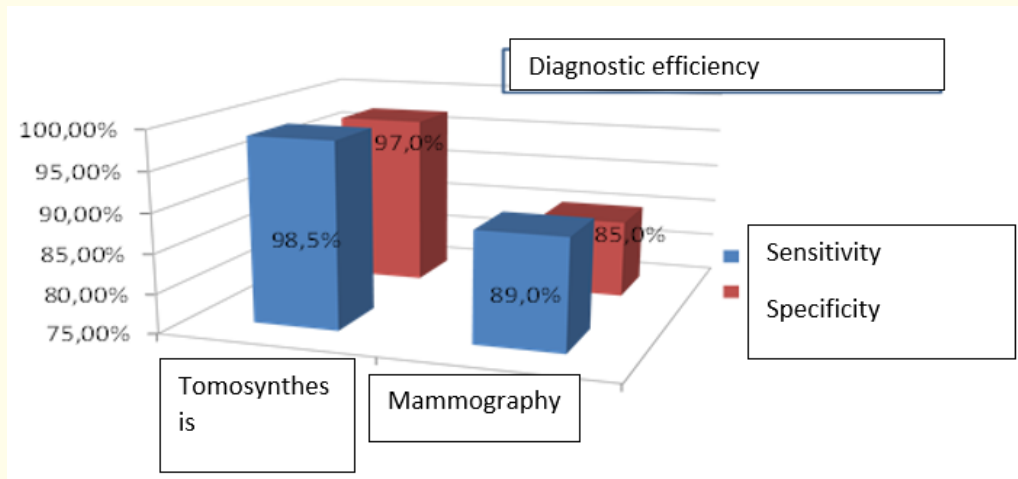


Figure 6: Diagnostic value of tomosynthesis and mammography.

## Bibliography

1. Tatarchuk TF, et al. "Benign breast diseases in metabolic syndrome". *Sovremennaya Meditsina: Current Issues* 21 (2013): 623.
2. Wang L. "Early Diagnosis of Breast Cancer". *Sensors (Basel)* 17.7 (2017): E1572.
3. Godley KC., et al. "The UK breast screening program - what you need to know". *Climacteric* 20.4 (2017): 313-320.
4. Chan HP, et al. "Characterization of Breast Masses in Digital Breast Tomosynthesis and Digital Mammograms: An Observer Performance Study". *Academic Radiology* 24.11 (2017): 1372-1379.
5. Kim WH., et al. "Impact of prior mammograms on combined reading of digital mammography and digital breast tomosynthesis". *Acta Radiologica* 58.2 (2017): 148-155.
6. Mariscotti G., et al. "Digital breast tomosynthesis as an adjunct to digital mammography for detecting and characterizing invasive lobular cancers: a multireader study". *Clinical Radiology* 71.9 (2016): 889-895.
7. Chunyuan F, et al. "Fertility Drugs and Young-Onset Breast Cancer: Results from the Two Sister Study". *Journal of the Nation Cancer Institute* 104.13 (2012): 1021-1027.
8. Belotserkovtseva LD., et al. "Possibilities of early diagnosis of breast cancer in the conditions of the perinatal center". *Issues of Gynecology, Obstetrics and Perinatology* 13.6 (2014): 70 -74.

9. V Sinitsin. "System for description and processing of breast cancer research data, BI – RADS". Mammological Atlas/Ed. VE Sinitsina - M: ID "MEDPRACTIC-M", C328-332.
10. Tabar L., *et al.* "Mammography service screening and mortality in breast cancer patients: 20-year follow-up before and after screening". *Lancet* 361.9367 (2003): 1405-1410.
11. Philip Z Israel and Richard E Fine. "Stereotactic Needle Biopsy for Occult Breast Lesions: A Minimally Invasive Alternative". *The American Surgeon* 61.1 (1995): 89-93.
12. Rozhkova NI and Kharchenko VP. "Radial diagnosis of breast diseases, treatment and rehabilitation". Issue 3: Radial syndrome diagnosis of breast disease. M: Firm STROM (2000): 166.
13. Moiseenko VM. "The "natural history" of breast cancer growth". *Practical Oncology* 1 (2002): 6-14.
14. Ternova SK and Abduraimov AB. "Radiation mammology". M: GETAR-Media (2007): 32-40.
15. Semiglazov VF and Semiglazov VV. "Screening for breast cancer". *Practical Oncology*.
16. Ternova SK and Shishmareva NF. "Computed tomography in the diagnosis of breast cancer". *Bulletin of Radiology and Radiology* 1 (2008): 23-27.

**Volume 8 Issue 9 September 2019**

**©All rights reserved by NV Klimova., *et al.***