

Primary Double Synchronous Ovarian Tumor: Giant Mucinous Adenocarcinoma/Steroid Cell Tumor with Intense Virilization. Clinical Case and Review of Literature

María Cristina Guerrero de León^{1*}, Diana Paola Ramirez Salado², Antonio Cesar Escobar Moreno³, Olga Esquivel Hernández⁴ and José López Zamudio⁵

¹Intensive Care Unit, Gynecology and Obstetrics Hospital UMAE 23, Instituto Mexicano del Seguro Social, Monterrey, Nuevo León, México

²Chief of Pathology Department, Gynecology and Obstetrics Hospital UMAE 23, Instituto Mexicano del Seguro Social, Monterrey, Nuevo León, México

³Pathology Department, Gynecology and Obstetrics Hospital UMAE 23, Instituto Mexicano del Seguro Social, Monterrey, Nuevo León, México

⁴Department of Gynecology, General Hospital HGZ 16/Instituto Mexicano del Seguro Social/Torreón, Coahuila, México

⁵Department of Onco-Surgery, General Hospital HGZ 16/Instituto Mexicano del Seguro Social/Torreón, Coahuila, México

***Corresponding Author:** María Cristina Guerrero de León, Intensive Care Unit, Gynecology and Obstetrics Hospital UMAE 23, Instituto Mexicano del Seguro Social, Monterrey, Nuevo León, México.

Received: July 20, 2019; **Published:** August 13, 2019

Abstract

The coexistence of a mucinous ovarian cystadenocarcinoma and ovarian steroid cell tumor in the contralateral ovary is very rare. Clinical presentation can coexist with increased abdominal size and clinical signs of virilization. Due to the size of this tumor and the gross manifestations of virilization due to ovarian steroid cell tumor which is a very rare functioning sex-cord stromal tumor representing 0.1% of all ovarian tumors we decide to present this clinical case, with the information that was available.

Here in we report a case of a 55 year-old female patient, she began her illness 5 years ago with androgenic alopecia, 2 years with marked hirsutism, clitoromegaly, a year with increased abdominal size and two months with progressive weight loss. Physical examination showed a woman with marked signs of virilization, androgenic alopecia and hirsutism, abdomen with central obesity, distribution of android hair, abdominal mass occupying all the abdominal cavity, regular edges, firm consistency, not mobile, slightly painful. Genitals with clitoromegaly. Tumor markers Ca 125: 756, AFP 4.5, ACE 20. She underwent laparotomy. A huge mass in the right ovary occupying abdominal cavity and another smaller mass was found in left ovary. Patient complicated with hypovolemic shock due to bleeding of 4 liters during surgery, she required polytransfusion and mechanical ventilation. Her evolution at intensive care unit was favorable. Histopathological report revealed a mucinous cystadenocarcinoma in right ovarian and tumor of malignant steroid cells in left ovary. We report a bilateral synchronous primary ovarian carcinoma which is a rare entity found in clinical practice, in this case there are two different histological types of ovarian tumor, having the left ovary metastasis from the cancer of the right ovary, this is extremely rare that's why we report this case, actually we did not find case reports with this combination of gynecological cancer (mucinous cystadenocarcinoma + steroid cell tumor) with high degree of virilization.

Keywords: Multiple Synchronous Primary Ovarian Tumors; Mucinous Cystadenocarcinoma; Malignant Tumor of Steroid Cells; Virilization; Hirsutism; Clitoromegaly

Abbreviations

AFP: Alpha-Fetoprotein; ACE: Carcinoembryonic Antigen; HyE: Hematoxilina Eosina

Introduction

Worldwide, 240,000 women are diagnosed with ovarian cancer each year, with a five-year survival of less than 45%, responsible for 150,000 deaths per year, which makes it the seventh cause of cancer and the eighth cause of death cancer among women, being considered the first cause of death from gynecological cancer, which makes it the diagnosis of higher lethality [1]. In Mexico, around 4,000 new cases are diagnosed every year, being this the third cause of gynecological cancers in our female population. This neoplasm is underestimated compared to other well-known types of cancers, such as breast and cervical cancer [2]. Ovarian cancer includes epithelial cancer that develops on the surface of the ovary. It is the most common type of cancer and represents 85% of cases, especially in women between 45 and 59 years old. The germ cell type represents 10% and is more frequent in young women under 30 years of age. Stromal tumors are very rare (2 - 3%) and affect the ovarian tissue, but they can be functional and produce hormones. There are also ovarian sarcomas and neuroendocrine tumors that are very rare malignancies [2]. The presence of synchronous primary ovarian malignant tumors, that is, of different histological type, is very rare, with an incidence ranging between 0.7% and 1.5% [3-5], so it is of special interest to describe clinical cases as the one presented below due to the limited information available about its diagnosis, clinical evolution and treatment. This rare combination of tumors has never been reported so far in the literature to the best of our knowledge.

Clinical Case

Written Informed consent was obtained from the patient and her daughter for publication of her case.

Here in we present the case of this 55-year-old female patient with no relevant family history, with intense alcoholism for around 15 years, suspended at the time of consultation, chronic hypertension of 10 years of evolution, on treatment with losartan 50 mg x 2 and metoprolol 100 mg x 2. Gesta 1, caesarean section 1, 32 years ago, antecedent of hysterectomy 20 years ago secondary to uterine myomatosis. Patient attended consultation due to an increase in the abdominal circumference of 1 year of evolution, which increased in the last 6 months, weight loss of 10 kg was added in the last 2 months, besides she referred to have 5 years of evolution with androgenic alopecia and 2 years with marked hirsutism. Physical examination showed a woman with marked signs of virilization, androgenic alopecia Ludwig Classification Type III (Figure 1) and hirsutism (Figure 2), abdomen with central obesity, distribution of android hair, abdominal mass occupying 4 quadrants of regular edges, firm consistency, not mobile, mild pain during palpation, external genitals with clitoromegaly (Figure 3).

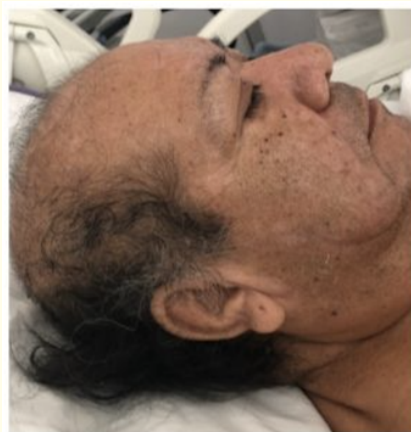

Figure 1: Androgenic alopecia Ludwig Classification Type III.

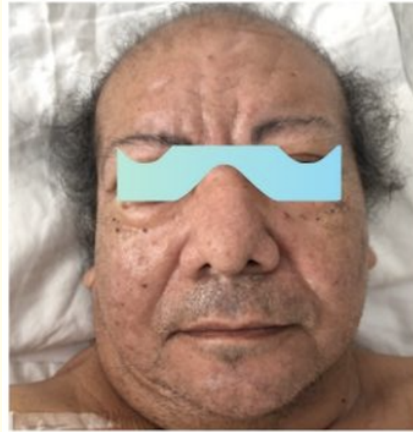

Figure 2: Hirsutism.

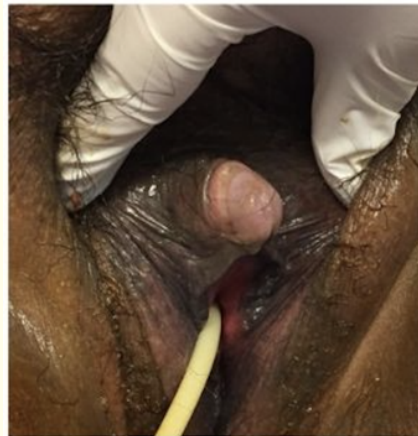

Figure 3: Clitoromegaly.

Vaginal examination was not performed due to refusal of the patient. Lower limbs were hypotrophic. Abdominal ultrasound showed the hepatic right lobe with granular ecotexture as an incipient finding of liver disease, an increase in abdominal size due to a multilocular cystic image with thick septos and echogenic detritus in its interior, which displaces abdominal structures, making it difficult to determine its origin. CT scan showed a tumor apparent right-sided origin of 30 x 65 x 62 cms, heterogeneous with predominantly cystic hypodense zones, in addition to a solid and heterogeneous tumor measuring 12 x 10 cm in the left annex (Figure 4). Laboratory findings included blood cell count which was abnormal due to anemia, her hemoglobin level was 10.8 g/dL (12.7 - 16.5), hematocrit 33.8% (41.3 - 43.7), leucocytes $11.7 \times 10^3/\mu\text{l}$ (4.8 - 10.2), and platelets $377 \times 10^3/\mu\text{l}$ (142 - 424). Her renal function was also abnormal report in ureic nitrogen 37 mg/dL (5 - 23), urea 79.1 mg/dL (10.0 - 50.0), Creatinine 1.4 mg/dL (0.55 - 1.0), Hyperuricemia of 9.8 mg/dL (2.4 - 7.0), hepatic profile with mild hypoalbuminemia of 3.4 g/dL (3.5 - 5.2), hyperglobulinemia of 3.7 g/dL (1.0 - 2.0), alkaline phosphatase 195 U/L (35 - 123), lactic dehydrogenase 274. U/L (91 - 180), electrolytes were normal. Additional measures were tumor markers Ca 125 which was in 756, AFP 4.5, ACE 20. Hormonal profile could not be obtained. Patient underwent laparotomy where there were multiple adhesions from

the abdominal wall to the omentum and the intestine, as well as a tumor that occupied the totality of the abdominal cavity measuring 30 x 56 cm in its largest diameter with origin in the right ovary, macroscopically with an external blue-white surface, with congestive vessels, right salpings was adhered (Figure 5). In addition, a 10 x 12 cm left ovarian tumor with a whitish and lobulated surface was obtained, pathology report showed metastasis of mucinous adenocarcinoma of contralateral ovary, with implants on the ovarian surface (Figure 6). During the surgical procedure patient had hypovolemic shock due to bleeding of 4000 cc. she underwent transfusion of 7 red blood package cells, 10 cryoprecipitate, 5 plasma and 6 platelet concentrates, she was in mechanical ventilation and was extubated 3 hours after her arrival to intensive care unit where she spent three days then was moved to gynecology ward.

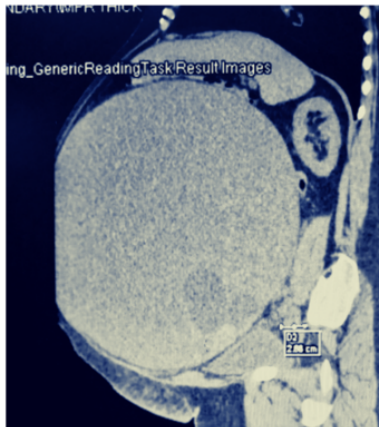


Figure 4: Abdominal CT Scan sagittal view showing the tumoral mass.

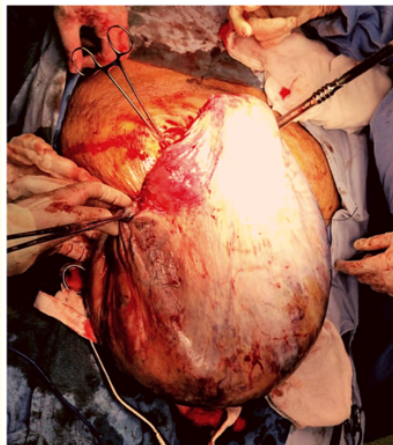


Figure 5: Laparotomy showing Right sided ovarian tumor 30 x 56 cms.

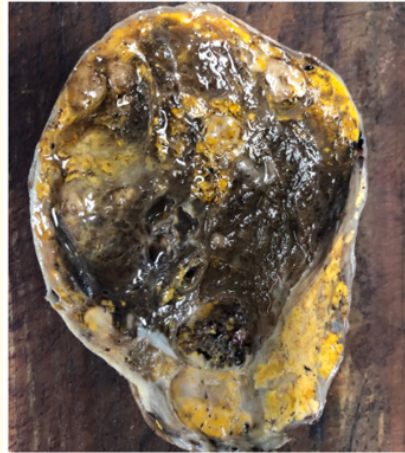

Figure 6: Left ovary. Malignant tumor of steroid cells. With a solid cut surface, predominantly yellowish with central necrosis and some whitish areas of myxoid appearance with central necrosis.

Pathology report of right ovary showed a 30 x 36 cms mucinous cystadenocarcinoma, with infiltrative invasive pattern, grade 2 and foci of solid areas with signet ring cells, with capsular invasion and implants on the capsular surface, tumoral necrosis and angiolymphatic invasion present (Figure 7). Pathology report of left ovarian tumor was malignant steroid cell tumor, 12 cm, diffuse pattern, areas of necrosis, mitotic count greater than 2 mitoses per high power field (40x), hemorrhage and nuclear grade 2, with metastasis of the mucinous cystadenocarcinoma of the right ovary on the surface (Figure 8).

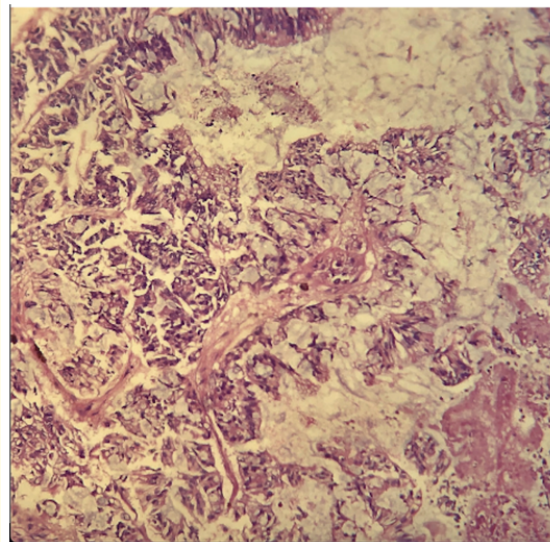


Figure 7: Right ovary. HyE. 10X Mucinous Adenocarcinoma Mucoproduction cells forming atypical glands and mucus lagoons.

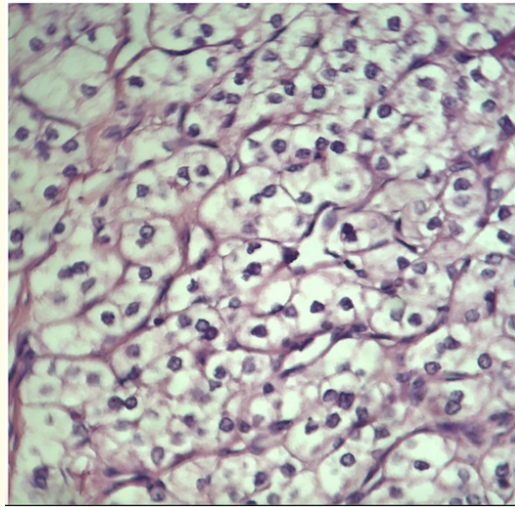
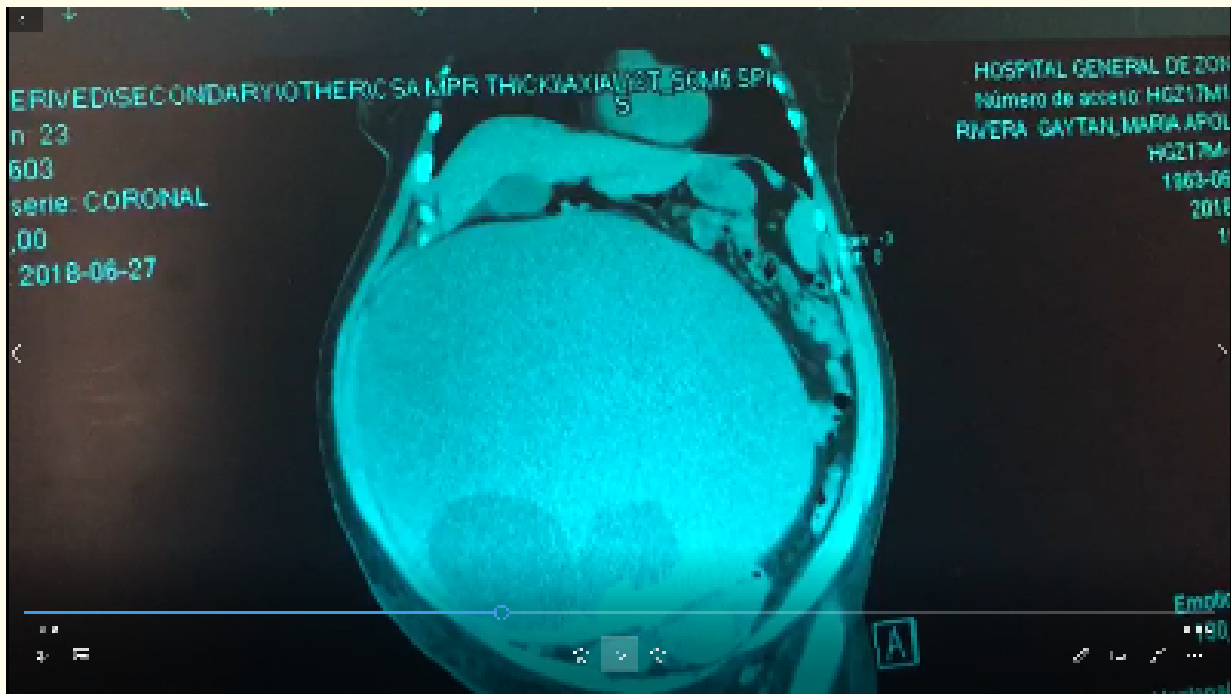
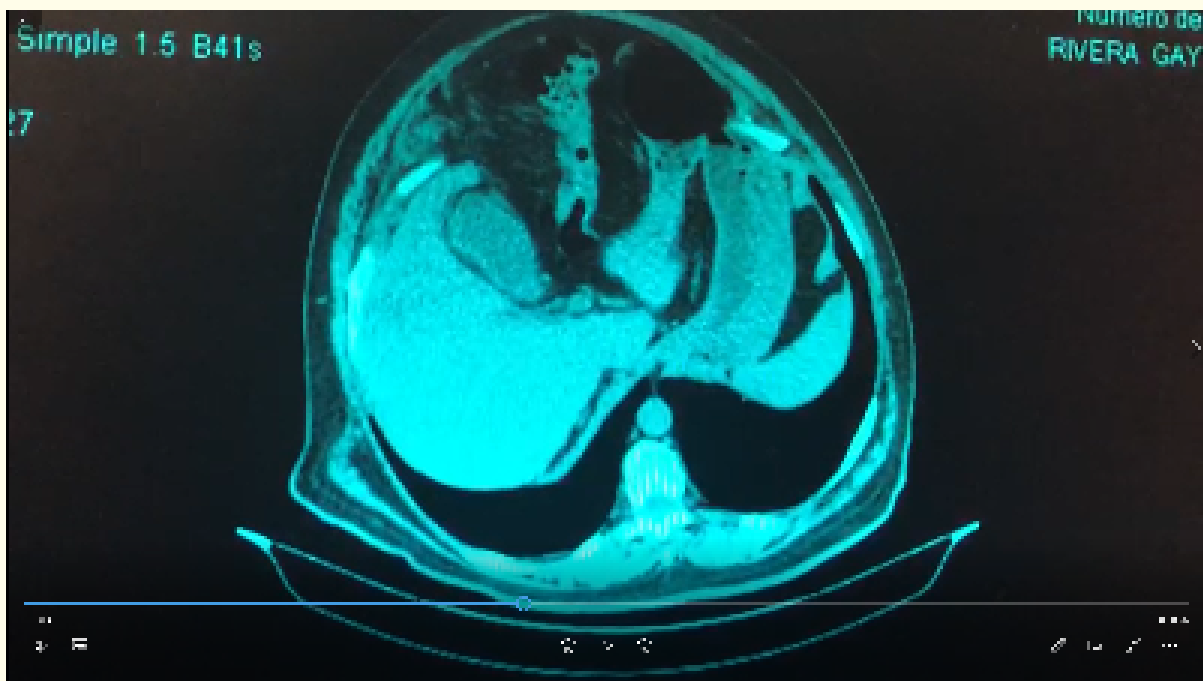
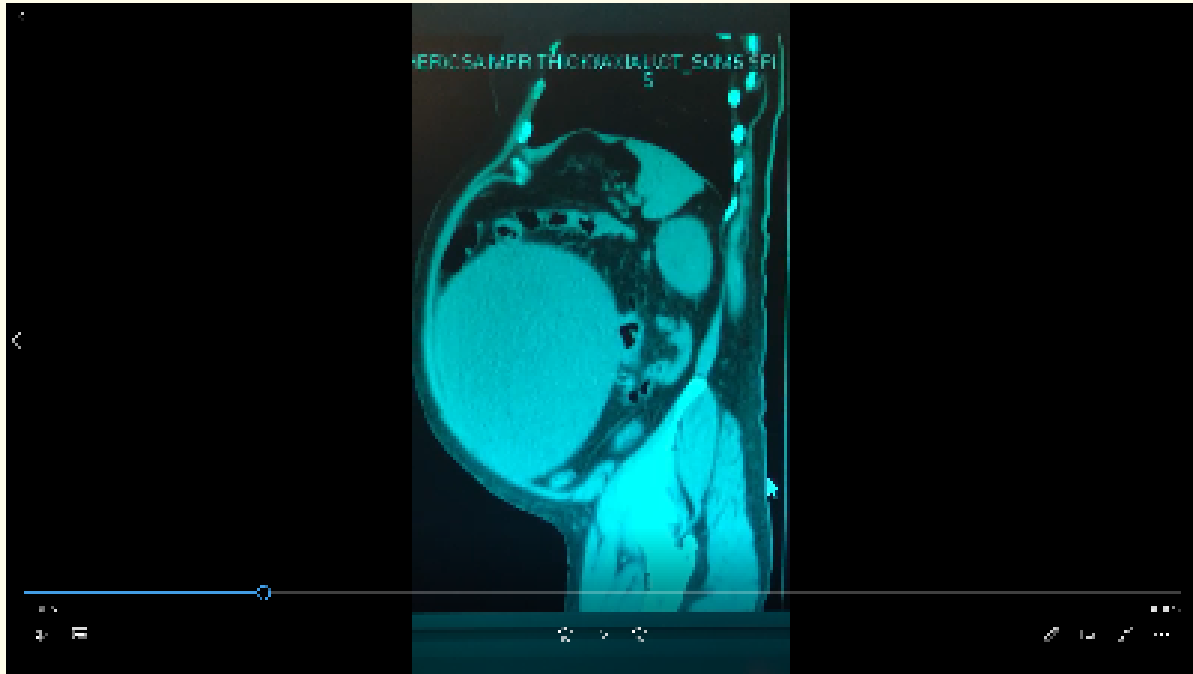


Figure 8: Left ovary. HyE. 40X Steroid Cells Malignant Tumor. Steroid cells with nuclear atypia are observed.





Discussion

Ovarian cancer is the third most common malignancy of the genital tract after endometrial carcinoma being the cervical carcinoma in first place. It's incidence increases with age being more frequent between 50 and 55 years old. It's rarely diagnosed in its early stages (20 - 25%) and, in general, is very advanced at the time of diagnosis, which often offers an ominous prognosis in spite of advances in the knowledge of the behavior and biology as well as the existing treatment protocols. The bilateral synchronous primary ovarian carcinoma is a rare entity found in clinical practice. It has been defined as double primary synchronous, in this case ovarian, being a neoplasm with two simultaneous primary tumors diagnosed in a period less than six months and distinguishes it from that which occurs in the same way but successively or in a period greater than six months, which is usually called metachronous tumor [6,7].

Epithelial ovarian cancer is the most lethal gynecological cancer, it consists of six main histological subtypes (histotypes); Low grade serous carcinoma, high grade serous carcinoma, clear cell carcinoma, endometrial carcinoma, mucinous carcinoma and transition cell carcinoma with different genetic profiles, biological behavior and results [8]. Ovarian mucinous adenocarcinomas as the one our patient had in right ovary are rare, since they comprise 2% to 3% of the primary malignant epithelial neoplasms of the ovary. From 65 to 80% of mucinous ovarian cancers are diagnosed at an early stage 6, according to the classification of the International Federation of Gynecology and Obstetrics (FIGO stage I, defined as a tumor confined to a single ovary) Mucinous ovarian cancers are usually very large primary tumors (typically > 15 cm in diameter) that generate symptoms while the disease is still localized in the ovary [9]. The main strategy to treat mucinous carcinomas of the ovary is surgical resection with staging. Unfortunately, in our case patient came with very advanced disease and the size of her right tumor was 30 x 65 x 32 cms. Epithelial ovarian cancer is considered a relatively chemoresistant disease, with poor results [10]. Regarding Steroid cell tumors this type of neoplasm is very rare and represent approximately 0.1% of all ovarian neoplasms [11]. They occur over a wide age range and are generally unilateral, approximately half of the patients presenting with androgenic symptoms in the presentation such as androgenic alopecia [12,13], hirsutism, clitoromegaly and hoarse voice. They are composed of polygonal tumor cells with abundant cytoplasm ranging from eosinophils to vacuolated, according to the degree of lipid accumulation. When they are more eosinophils, they are morphologically similar to the cells of the Leydig cell tumors, although the latter contain Reinke crystals. The cells are soft, with round nuclei that contain a prominent and centrally located nucleus. These tumors are positive for inhibin, calretinin and steroidogenic factor 1 by immunohistochemistry. Characteristics associated with malignant behavior include larger size (47 cm), prominent mitotic activity (42 mitosis/10 high potency fields), necrosis, hemorrhage, and significant cytologic atypia [14-17].

Interestingly, pathologically benign tumors can behave in a clinically malignant manner. About 20% of patients develop metastatic lesions usually within the peritoneal cavity and rarely in distant sites. The primary treatment is the surgical removal of the primary lesion and there are no reports of effective radiotherapy or chemotherapy. The main reason is the poor knowledge of chemotherapy and radiotherapy in the treatment of these tumors due to its rarity.

Conclusion

This is a rare and perhaps unique case, since no cases of association of malignant mucinous tumor with malignant steroid cell tumor were found in the literature because of their low clinical presentation in both cases. This rare variety of virilizing ovarian tumors is not only a medical problem, but also a social problem for any age group of women. Its description is important in order to provide a guideline of the natural behavior of the disease, improving the diagnostic and therapeutic approaches, unfortunately most of them at the time of diagnosis are in advanced clinical stages with unfavorable prognoses. Due to the low presentation of synchronous tumors as mentioned in this case, there is still a wide field of research before being able to make some recommendations about diagnosis and treatment, being necessary the publication of more clinical cases and research studies to be able to reach to a consensus to improve the survival of women with this condition.

Conflict of Interest

There are no financial interest or any conflict of interest.

Bibliography

1. Webb PM and Jordan SJ. "Epidemiology of epithelial ovarian cancer". *Best Practice and Research Clinical Obstetrics and Gynaecology* 41 (2016): 3-14.
2. Gallardo-Rincón D., et al. "Epidemiological overview, advances in diagnosis, prevention, treatment and management of epithelial ovarian cancer in Mexico". *Salud Pública de México* 58.2 (2016): 302-308.
3. Ionescu A., et al. "Synchronous bilateral primary ovarian carcinoma Case Presentation". *Romanian Journal of Morphology and Embryology* 58.1 (2017): 219-223.
4. Tavassoli FA and Deville P. "WHO Classification of Tumours of the Breast and Female Genital Organs". 3rd edition. Lyon: IARC press (2003): 113-202.
5. Goyal., et al. "Histopathological Study of Ovarian Tumors at a Tertiary Care Hospital". *Journal of College of Medical Sciences-Nepal* 15.1 (2019).
6. Sethi D., et al. "A synchronous presentation of two different ovarian tumors: a rare occurrence". *Annals of Medical and Health Science Research* 3.2 (2013): 268-270.
7. Bernárdez F., et al. "Tumor doble primario sincrónico de ovario in situ". *Ginecología y Obstetricia de México* 80.7 (2012): 480-486.
8. Mueller., et al. "International Study of Primary Mucinous Ovarian Carcinomas Managed at Tertiary Medical Centers". *International Journal of Gynecological Cancer* 28.5 (2018): 915-924.
9. Prat J. "FIGO's staging classification for cancer of the ovary, fallopian tube, and peritoneum: abridged republication". *Journal of Gynecologic Oncology* 26.2 (2015): 87-89.
10. Morice P., et al. "Mucinous Ovarian Carcinoma". *New England Journal of Medicine* 380 (2019): 1256-1266.
11. Das A., et al. "Steroid cell tumor: A rare virilizing ovarian tumor". *Journal of Cancer Research and Therapeutics* 11.3 (2015): 660.
12. Ludwig E. "Classification of the types of androgenetic alopecia (common baldness) occurring in the female sex". *British Journal of Dermatology* 97.3 (1977): 247-254.
13. Gupta M and Venkataram M. "Classification of patterned hair loss: a review". *Journal of Cutaneous and Aesthetic Surgery* 9.1 (2016): 3-12.
14. McGregor S., et al. "Case Report Collision Signet-Ring Stromal Tumor and Steroid Cell Tumor of the Ovary: Report of the First Case". *International Journal of Gynecological Pathology* 36.3 (2017): 261-264.
15. Scully RE., et al. "Tumors of the ovary and maldeveloped". In: Armed Forces Institute of Pathology. AFIP Atlas of Tumor Pathology. Washington, DC: AFIP (1979): 215-220.
16. Hartman LC., et al. "Ovarian sex cord-stromal tumors". In: Hoskins WJ, Perez CA, Young RC (editors). Principles and Practice of Gynecologic Oncology. 2nd edition. Philadelphia: Lippincott-Raven (1997): 1015-1019.
17. Hayes MC and Scully RE. "Ovarian steroid cell tumors (not otherwise specified): a clinicopathological analysis of 63 cases". *American Journal of Surgical Pathology* 11.11 (1987): 835-845.

Volume 8 Issue 9 September 2019

©All rights reserved by María Cristina Guerrero de León., et al.