

Scar Endometriosis the fact and the Myth: A Report of 2 Cases and Literature Review

Marwa Fakhreldin^{1*}, Rawia Mohamed² and Sadoon S Sadoon¹

¹Department of Obstetrics and Gynecology, Corniche Hospital, Abu Dhabi, UAE

²Department of Pathology, Sheikh Khalifa Medical City Hospital, Abu Dhabi, UAE

***Corresponding Author:** Marwa Fakhreldin, Department of Obstetrics and Gynecology, Corniche Hospital, Abu Dhabi, UAE.

Received: May 28, 2019; **Published:** July 10, 2019

Abstract

Endometriosis is a disease where functional endometrial cells exist outside the uterine cavity. Scar endometriosis is a rare variant of endometriosis; however, it is well described in literature. The cause is understood to be the re-implantation or disposition of these active pluripotent cells in the scar site. The debate has always been about whether it is preventable or not. The main risk lies within the delay of diagnosis of such cases given the malignant potential within. The objective of this review is to highlight the importance of prompt diagnosis, prevention and management. We report our experience in the management of 2 cases with scar endometriosis over one year in a tertiary care center in UAE. Scar endometriosis is a rare entity which makes it difficult for researchers to conduct case controlled or prospective studies on modes of prevention. Few studies were done previously to try to understand the process of implantation and hence prevention of endometriosis specifically at the scar sites given its iatrogenic potential. The disposition theory does not explain the inadvertent presence of endometrial cells inside the parenchyma of lungs and gut for instance. Pathologists tend to believe that the cell characters and the genetic potential are the main factors behind this disease existence, supported by the malignant drive on the long term. Surgical techniques to prevent scar endometriosis are not properly investigated and needs more research with multicenter involvement. Scar endometriosis should be considered as an important differential in reproductive age patients presenting with pain over scar sites. Delay in diagnosis affects the management and the outcome. Proper assessment should be instigated prior to intervention as mesh placement in large endometriomas might be needed. Preventive techniques should be explored extensively in both laboratory and clinical aspects.

Keywords: Scar Endometriosis; Endometrial Tissue; Cesarean Scar; Endometriosis

Introduction

Endometriosis is a disease where functional endometrial cells exist outside the uterine cavity. Scar endometriosis is a rare variant of endometriosis; however, it is well described in literature. The cause is understood to be the re-implantation or disposition of these active pluripotent cells in the scar site. The debate has always been about whether it is preventable or not.

Case Report

In this review, we are reporting our experience in the management of two cases of scar endometriosis in a tertiary care center in UAE. Both were 33 years old, medically fit and had a normal BMI.

The first case was a P3 with previous 2 normal deliveries followed by 1 cesarean section in 2009 that was complicated by rectus sheath hematoma and wound infection. She has been using IUCD for contraception since then. She also had history of laparoscopic ovarian cystectomy for a simple cyst in 2008. Her first complaint was in 2012, 3 years after her cesarean section, where she presented with cyclic pain over the scar site. She was initially seen by general surgeons who suspected incisional hernia, CT was done and the same was

excluded. CT reported mild thickening of the lower Rectus Abdominis muscle. Patient was managed conservatively for 2 years with simple analgesia and no proper diagnosis. In 2014, she presented to us with constant pain over the scar site that increases with menstruation, coughing and exercise. On examination a 3 cm well demarcated nodule was felt subcutaneously. Ultrasound showed a mixed echo area anterior to the bladder measuring 2.58 x 1.46 cm, with no vascularity (Figure 1). She was advised for MRI and surgical excision but she defaulted. In 2016, again 2 years later she represented with more pain that exacerbates with any movement. Ultrasound scan was repeated which showed an increase in the mass size with cystic changes and mild vascularity (Figure 2).

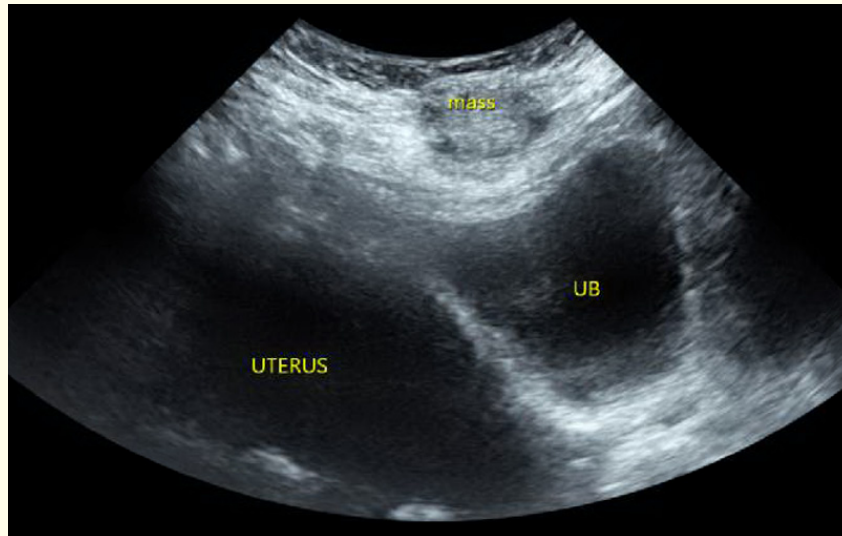
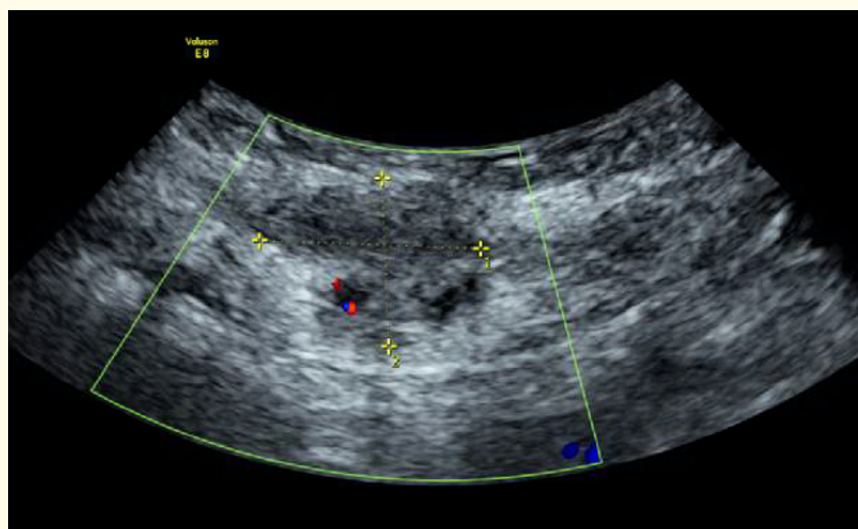


Figure 1: A mixed echo area is noted superficially, anterior to the bladder, measuring 2.58 x 1.46 cm. No vascularity seen.



Figures 2: A mass with multiple cystic changes seen under the skin, in the soft tissue, extending to the left, measuring 3.81 x 2.11 x 2.05 cm.

The second case had a history of laparoscopic myomectomy in 2011 with histopathologic evidence of adenomyosis too. She got pregnant for the first time in 2012. She then had an emergency laparotomy for complete uterine rupture in 2013 at 35 weeks gestation with subsequent repair. MRI was done 4 months later as she was complaining of pain. It only showed minimal subserosal fluid collection at the site of scar. She remained on oral contraceptive pills till 2015. In 2016, she came back with pain at the scar site and a palpable mass of 3 cm in size under the skin. She noted that that pain is constant but increases during menstruation. MRI was then done which showed features suggestive of scar endometriosis.

Both patients then had surgical excision in 2016. The first case was done with diathermy cutting, and the second was done with cold knife and scissors. Rectus sheath was intact in both cases. Histopathology examination for both cases showed fibrofatty tissue with endometriotic glands and stroma in between. No cytological evidence of malignancy or atypia was noted. Scar endometriosis was confirmed. No recurrence or complications till date (Figures 3 and 4). The Second case got pregnant again and delivered in 2019 with no recurrence or residual mass noted during her repeat cesarean section.

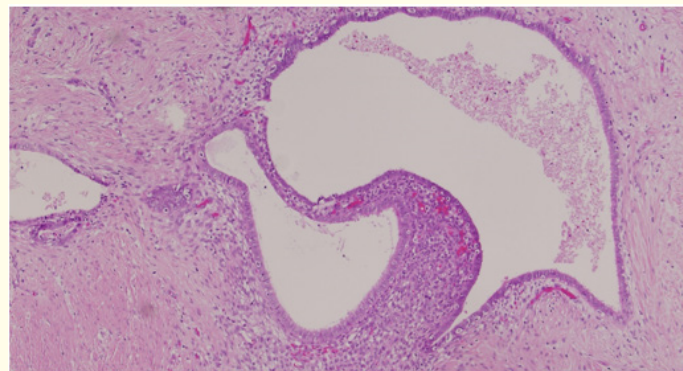


Figure 3: Biopsy Specimen shows benign looking endometrial glands, stroma and adipose tissue within a background of connective tissue. Low power view (H&E staining x 10 magnification).

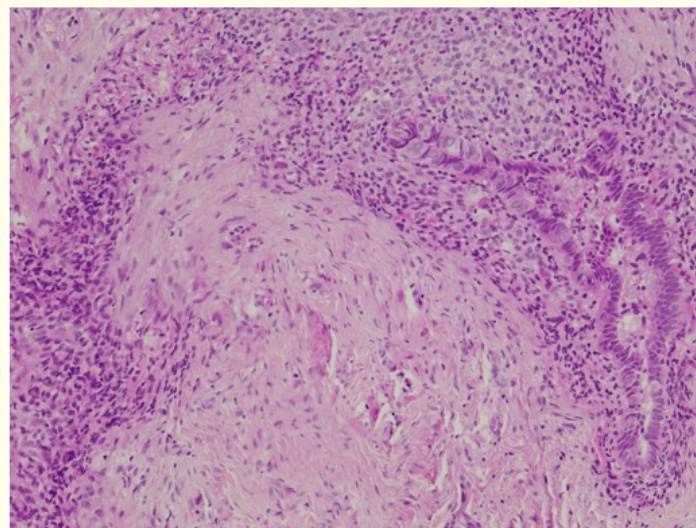


Figure 4: Biopsy Specimen shows unremarkable endometrial glands and stroma, adipose and fibrous tissue. High power view (H&E staining x 20 magnification).

Discussion

The real incidence of scar endometriosis is undetermined till date. Many of the mild cases remain undiagnosed. It is estimated to be 0.3 - 1% [1]. Increased menstrual flow and alcohol consumption were reported by De Oliveira and his team in a case controlled study as important risk factors; they also noted that high parity can be a protective factor [2]. Other studies suggest that immunologic, hormonal and environmental factors may render some individuals more susceptible to the development of endometriosis [3]. The cellular characteristics of endometrial cells and their ability to regulate cytotoxic immune activity and escape apoptosis through immune system dysfunction, enables them to survive in ectopic areas [4]. Experimental studies have proven the ability of transplanted endometrial tissue to grow in immune compromised rats [5].

Several diagnostic modalities are well documented for their high predictive value in scar endometriosis. Computed Tomography, Ultrasound Scan and Fine-Needle Aspiration Cytology (FNAC) are all reliable. FNAC was described by Medeiros and his team in a series of 9 cases, as an accurate and inexpensive tool, which can clearly identify endometrial cells and stroma in the lesion [6]. However, clinical history is still important especially in cases where FNAC shows nuclear atypia, or decidualization under the influence of progesterone either internally or externally, where findings can be mistakenly interpreted as malignancy [7].

Delayed diagnosis is often associated with a change in the clinical and radiologic picture of the lesion [8]. There is also a risk of malignant transformation in 1% of cases, most commonly into an endometrioid and clear cell carcinoma, rare scenarios as carcinosarcomas has also been reported [9]. Whether this risk is related to advanced age or large size as in cases of ovarian endometriomas or not, no one knows.

Surgical exploration with wide margins on excision is the mainstay of treatment. It is the only means to prevent recurrence and malignant transformation [10]. Success rates reaches 95%, with incomplete excision in 4.3 % in a review of 445 cases by Horton, *et al* [11]. Hull, *et al.* and his team used hook wire to facilitate identification of the lesion and reduce the size of incision and defects in rectus sheath; which also helps in cases where palpation of the lesion is difficult [12]. Medical therapy is less instigated in cases of scar endometriosis. Theoretically clinical symptoms might be relieved by hormone suppression, only if diagnosis is confirmed.

There is no solid evidence about modes of prevention if any. Many suggestions as closure of visceral and parietal peritoneum, high dose progesterone for 6 months postoperative [13] and abdominal wash with saline particularly on the surgeon's side and corner sites [14]. The level of CA-125 postoperatively was suggested as a means to monitor recurrence in scar endometriosis, but the value is questioned [15] and again no studies to prove it.

Conclusion

High level of suspicion is needed to diagnose scar endometriosis. Proper history taking and paying attention to the pain cyclic pattern is key to early diagnosis. Imaging is the confirmatory modality, and surgical excision is the mainstay of treatment. Prevention is possible by meticulous surgical technique; however, no proven etiology is identified as yet.

Conflict of Interest Statement

The authors have no conflicts of interest to declare.

Funding

No funding was needed for the study.

Ethical Approval

Ethical approval was obtained from the internal review board.

Bibliography

1. Mistrangelo M., *et al.* "Surgical scar endometriosis". *Surgery Today* 44.4 (2014): 767-772.
2. de Oliveira MAP., *et al.* "Risk factors for abdominal scar endometriosis after obstetric hysterotomies: a case-control study". *Acta Obstetricia et Gynecologica Scandinavica* 86.1 (2007): 73-80.
3. Samal AG., *et al.* "Abdominal scar endometriosis". *Indian Journal of Surgery* 75.1 (2013): 217-219.
4. Vellido-Cotelo R., *et al.* "Endometriosis node in gynaecologic scars: a study of 17 patients and the diagnostic considerations in clinical experience in tertiary care center". *BMC Womens Health* 15 (2015): 13.
5. Pelch KE., *et al.* "Mouse model of surgically-induced endometriosis by auto-transplantation of uterine tissue". *Journal of Visualized Experiments* 59 (2012): e3396.
6. Medeiros FDC., *et al.* "Fine-needle aspiration cytology of scar endometriosis: Study of seven cases and literature review". *Diagnostic Cytopathology* 39.1 (2011): 18-21.
7. Rekhi B., *et al.* "Cytopathological features of scar endometriosis mimicking an adenocarcinoma: A diagnostic pitfall". *Journal of Cytology* 30.4 (2013): 280-283.
8. Francica G and Scarano F. "Delayed diagnosis is associated with changes in the clinical and ultrasound features of subcutaneous endometriosis near cesarean section scars". *Journal of Ultrasound* 12.3 (2009): 101-106.
9. Leng J., *et al.* "Carcinosarcoma arising from atypical endometriosis in a cesarean section scar". *International Journal of Gynecological Cancer* 16.1 (2006): 432-435.
10. Shalin SC., *et al.* "Clear cell adenocarcinoma arising from endometriosis in abdominal wall cesarean section scar: a case report and review of the literature". *Journal of Cutaneous Pathology* 39.11 (2012): 1035-1041.
11. Horton JD., *et al.* "Abdominal wall endometriosis: a surgeon's perspective and review of 445 cases". *American Journal of Surgery* 196.2 (2008): 207-212.
12. Hull ML., *et al.* "Hook-wire insertion facilitates the excision of scar endometriosis". *BJOG: An International Journal of Obstetrics and Gynaecology* 113.6 (2006): 744-746.
13. Minaglia S., *et al.* "Incisional endometriomas after Cesarean section: a case series". *Journal of Reproductive Medicine* 52.7 (2007): 630-634.
14. Teng CC., *et al.* "Abdominal wall endometriosis: An overlooked but possibly preventable complication". *Taiwanese Journal of Obstetrics and Gynecology* 47.1 (2008): 42-48.
15. Kocakusak A., *et al.* "Abdominal wall endometriosis: A diagnostic dilemma for surgeons: Three case reports". *Medical Principles and Practice* 14.6 (2005): 434-437.

Volume 8 Issue 8 August 2019

©All rights reserved by Marwa Fakhreldin., *et al.*