

Hysteroscopic Tubal Occlusion with LASER: A Preliminary Report

Bernardo Portugal Lasmar^{1,2*}, Ricardo Bassil Lasmar³, Roberto Carvalhosa Santos^{4,5,6}, Leon Cardeman⁷ and Flavia de Mello Viot⁸

¹Professor of Gynecology, Estacio de Sá University (UNESA), Brazil

²Department of Gynecological Endoscopy, Central Hospital Aristarcho Pessoa (HCAP-CBMERJ), Rio de Janeiro, Brazil

³Professor of Gynecology, Department of Maternal and Child Health, Federal Fluminense University, Brazil

⁴Professor of Gynecology, Estacio de Sá University (UNESA), Brazil

⁵Professor of Gynecology, Souza Marques University, Brazil

⁶Department of Gynecology, Piedade Hospital, Rio de Janeiro, Brazil

⁷Director of Labcardeman Pathology Clinic, Brazil

⁸Gynecology Residency (3rd Year), Piedade Hospital, Rio de Janeiro, Brazil

***Corresponding Author:** Bernardo Portugal Lasmar, Department of Gynecological Endoscopy, Central Hospital Aristarcho Pessoa (HCAP-CBMERJ), Rio de Janeiro, Brazil.

Received: April 13, 2019; **Published:** June 19, 2019

Abstract

Background: Hysteroscopy is the gold standard method for the diagnosis and treatment of diseases of the uterine cavity. Using this access, some methods of contraception have been developed, for example tubal devices (ESSURE), which lead to fibrosis and permanent tubal occlusion. Recently, biolitec (Germany) developed the Dual Wavelength System Generator (Leonardo[®], Figure 1), incorporating in the hysteroscopic arsenal a new tool, which allows the treatment of uterine lesions of different sizes at the outpatient level, using a laser fiber in the operative channel of the system.

Methods: This is a prospective study, in post hysterectomy wombs. For this study, seven LASER procedures were performed on hysteroscopic endosalpinge in uterine pieces after hysterectomies to evaluate the temperature reached in the uterine serosa and extent of mucosal damage. The indication of surgery (hysterectomy) followed the medical criteria, basing itself on the clinical indication of the procedure.

Results: There were safe tube serosa temperature and endosalpinge necrosis in the majority of the cases.

Conclusion: Hysteroscopic tubal occlusion with Laser seems to be safe and viable.

Keywords: *Hysteroscopic Tubal Occlusion; LASER*

Introduction

In 1981 the first endometrial vaporization with Nd YAG for the treatment of abnormal uterine bleeding was performed. Since then, several hysteroscopic applications for LASER have arisen, among them myomectomy, polypectomy, septoplasty, among others.

Recently, biolitec (Germany) developed the Dual Wavelength System Generator (Leonardo[®], Figure 1), incorporating in the hysteroscopic arsenal a new tool, which allows the treatment of uterine lesions of different sizes at the outpatient level, using a laser fiber in the operative channel of the system. This technology allows the resection of polyps and fibroids with minimal peripheral tissue damage, reducing pain and improving therapeutic results [1].

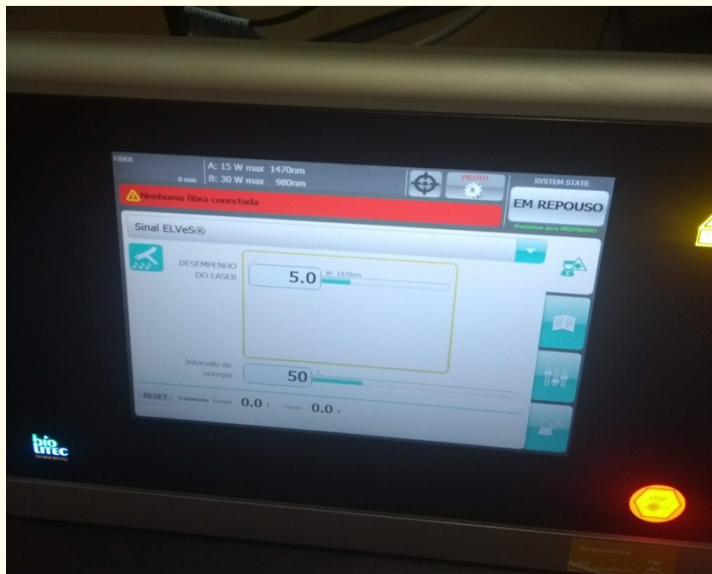


Figure 1: Leonardo generator by Biolitec.

Leonardo® is a diode laser device capable of mixing two different wavelengths, 980 nm and 1,470 nm. A 980 nm wavelength is more absorbed by hemoglobin, leading to higher coagulation effect. At 1,470 nm, we will have higher vaporization effect due to affinity to water. This mixing capacity allows combined effects that can be adjusted for each tissue and or surgery.

This technology is used in several other medical specialties, such as varicose veins, kidney stones, hemorrhoids, fistulas, etc [2].

Hysteroscopy is the gold standard method for the diagnosis and treatment of diseases of the uterine cavity. Using this access, some methods of contraception have been developed, for example tubal devices (ESSURE), which lead to fibrosis and permanent tubal occlusion.

Some papers have used laser fibers in animal models for tubal occlusion successfully [3]. The objective of this work is to evaluate the safety of the use of this technology and the possibility of applying LASER in tubal obstruction in humans.

Materials and Methods

Prospective study, in post hysterectomy wombs. For this study, seven LASER procedures were performed on hysteroscopic endosalpinge in uterine pieces after hysterectomies to evaluate the temperature reached in the uterine serosa and extent of mucosal damage. The indication of surgery (hysterectomy) followed the medical criteria, basing itself on the clinical indication of the procedure. The search did not interfere in any way with this indication. Specimens were selected from patients submitted to hysterectomy for benign diseases, without suspected adnexal or tubal lesions, and without previous tubal ligation.

The procedure was performed with Leonardo bipolar generator (Biolitec®) and ELVeS RADIAL SLIM 2Ring fiber, with 1470 nm wavelength. The fibers were donated by Biolitec®. The equipment was programmed for 5W and was applied 100J in 6 pieces. In one piece the application of 300J was tested. As a protocol, energy was triggered after insertion of the second ring of 2 ring fiber into the tubal ostium, under direct hysteroscopic vision (Figure 2). This trial was approved by ethical committee.

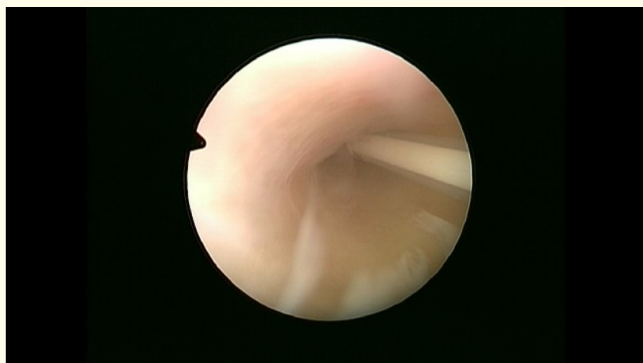

Figure 2: Ostium catheterization.

specimens were submitted to hysteroscopic procedure with 2.9 mm optics and Bettocchi system, with saline as distension media. The contact thermometer [TESTO 922 - with resolution of 0,1°C (-50 to +199,9°C)] was placed immediately before LASER activation, remaining during the whole procedure, and the highest temperature reached was recorded (Figure 3).

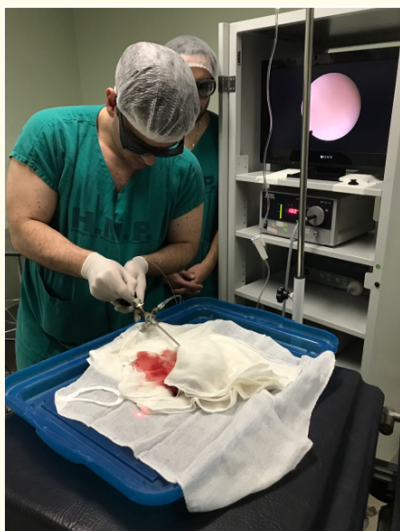


Figure 3A: Performing Hysteroscopy.

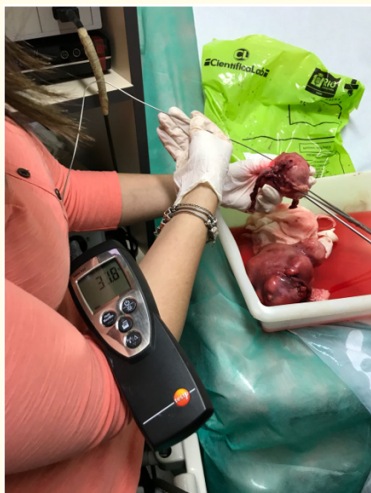

Figure 3B: Thermometer reading.

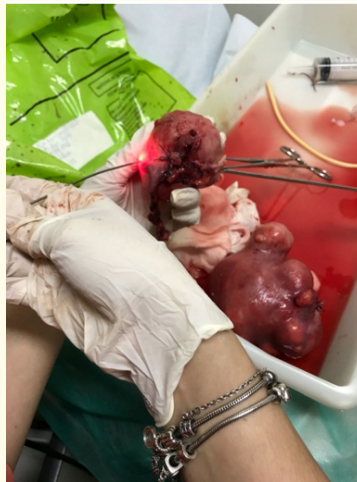

Figure 3C: Thermometer positioning.

The temperature of the tube serosa was measured by thermometer with contact probe, to evaluate how much the thermal energy progresses and what the maximum temperature reached during the procedure. After the procedure, the specimen was stored in formalin and sent to histopathology.

All the pieces had tubal permeability tested before and after the procedure, using a foley tube with saline injection using a 60 ml urological syringe.

Histopathological evaluation were perform Hematoxylin and eosin stain in 2 micra tissues slices.

Patients signed the consent form.

Results

In all Tubes (13), bilateral tubal patency was identified before the procedure. After the procedure, the saline was obstructed in 11 of the 12 tubas submitted to photocoagulation. In two of the tubas the procedure cannot be performed because in one of them the tubal ostium was not identified due to multiple fibroids in the cavity and in the other there was a striking tubal injury during the hysterectomy and it was not feasible to perform the procedure in this (one case of 100J and the other on 300 Joules).

The maximum temperature reached on the serosa during 100 Joules photocoagulation was 53°C, ranging from 45°C to 53°C, reaching 85°C with 300 Joules.

Under hysteroscopic vision it was possible to identify a change in the peri-ostial endometrial color, with characteristic signs of coagulation (Figure 4). Macroscopy did not show significant changes in tubal serosa in 100J applications, however, with 300J there was marked coagulation of all segments (Figure 5).

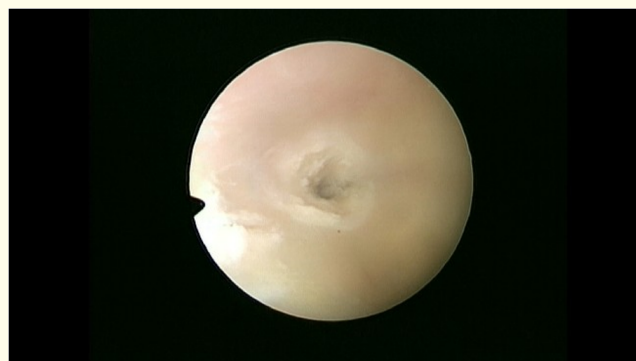

Figure 4: Left ostium after procedure.

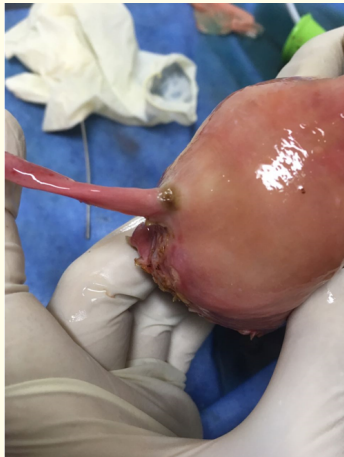

Figure 5: Macroscopic View Of tube after 300J of Photocoagulation.

The histopathological analysis identified a focus of necrosis in 07 of the 12 tubes, ranging from 0.2 mm to 0.4mm. The tube submitted to 300J showed marked necrosis, with reduction in tubal lumen and edema (Figure 6A). The normal tube lumen has 0.6 to 0.8 mm (Figure 6B).

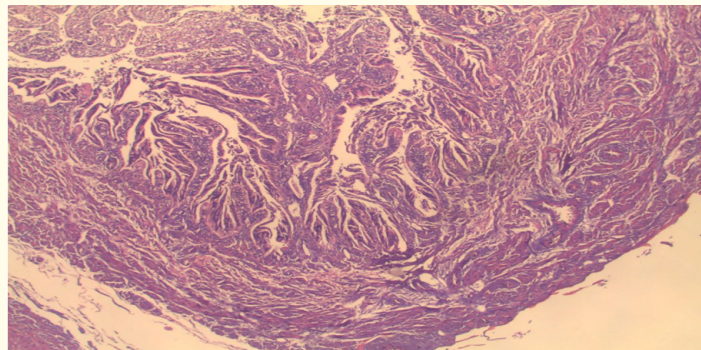


Figure 6A: Reduction of Tube lumen after 300 Joules, necrosis at peritoneal wall. H&E 40X, 2 micra slices.

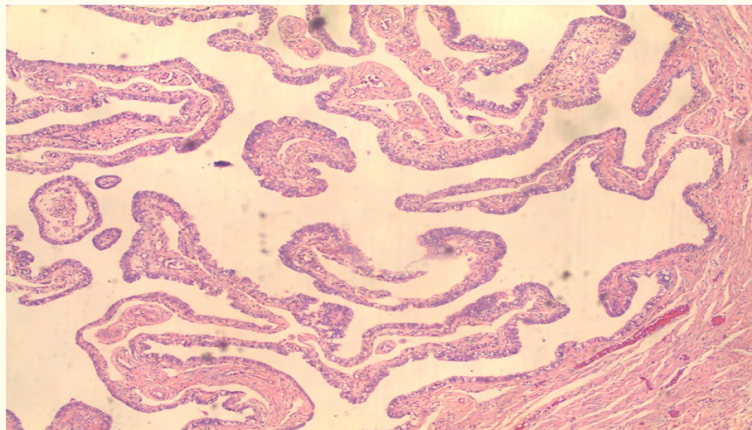


Figure 6B: Normal tube lumen, H&E 40X, 2 micra slices.

Discussion

The ELVeS 2Ring Radial fiber from Biolitec was developed for endovascular use in the treatment of varicose veins. It has two independent rings, which radially emit the waves carried by the fiber, reaching a 360 degree dispersion angle. It is an atraumatic fiber, flexible, with a diameter of 1.27 mm. These characteristics were important in the choice of this fiber for the design, since the flexibility and low diameter would allow the catheterization of the tubal ostium, and the two rings would lead to a greater extension of tubal mucosa submitted to the thermal action of LASER.

In 11 tubes (91.6%) there was obstruction of the saline solution after the procedure. This finding was not corroborated by lumen obstruction in the histological analysis, probably due to edema or reduction of lumen, and there was insufficient pressure for the passage of saline in the post-procedure test.

In the tubes submitted to 100 Joules there was thermal safety in the procedure, i.e. the temperature in the serosa immediately above the photocoagulation reached safe levels (max 53°C), and for a few seconds, which is of paramount importance for the viability of the procedure. In the *in vivo* patient, the tuba is positioned in the pelvic cavity, being surrounded and even supported on intestinal loops and or ovaries. In order for the procedure to be performed hysteroscopically without laparoscopic control, it is mandatory that the external temperature of the tuba does not reach high levels, which would lead to thermal damage in intestinal loops and risk of severe injury and sepsis. When applied 300 joules, there was a marked rise in external temperature, reaching 85°C, with evident coagulation of the tube in this region, and a probable risk of injury to adjacent organs (Figure 5).

In the histopathological analysis, however, there was small necrosis in only 6 of the 11 tubes (54.5%) submitted to 100 joules, without immediate lumen obliteration. The tuba submitted to 300 Joules evidenced important thermal lesion in the micro and macroscopy.

We believe that tubal lumen obliteration will be related to the action of fibroblasts on the tissue recovery caused by thermal damage in endosalpinge. This is a slow, *in vivo* process that requires tissue perfusion and cellular regeneration, with fibrosis and lumen occlusion. By defining a safe limit of energy, we should plan an *in vivo* study, in animal models or even in humans, with laparoscopic control for example, to evaluate the cicatricial response after 30 - 60 days of the procedure and evaluate whether or not there will be fibrosis and tubal obstruction.

This trial was performed in *ex vivo* specimens, therefore it is not possible to assume that it will have the same behavior at *in vivo* tissue.

Conclusion

This preliminary trial opens a door for laser tubal occlusion by hysteroscopy. The laser proved, in *ex vivo* tissue, to perform tubal lumen reduction and, with 100 Joules, to be safe to pelvic structures. Besides that, 100 joules laser application started necrosis process in more than 50% of the tubes, what probably will lead to posterior tubal obliteration *in vivo*, by fibrosis process.

Authors' Contributions

BRRF drafted the manuscript. BF carried out the Hysteroscopies. BRL participated in the design of the study and performed the statistical analysis. L carried out the histopathological analysis. All authors read and approved the final manuscript.

Competing Interests

The laser fibers were donated by Biolitec.

Bibliography

1. Lara-Domínguez, *et al.* "Outpatient hysteroscopic polypectomy: bipolar energy system (Versapoint®) versus diode laser-randomized clinical trial". *Gynecological Endocrinology* 32.3 (2016): 196-200.
2. Theivacumar NS., *et al.* "Factors influencing the effectiveness of endovenous laser ablation (EVLA) in the treatment of great saphenous vein reflux". *European Journal of Vascular and Endovascular Surgery* 35.1 (2008): 119-123.
3. Spörri S., *et al.* "Diode laser assisted transcervical tubal sterilization: an *in vivo* study in rabbits". *Lasers in Surgery and Medicine* 29.4 (2001): 379-385.

Volume 8 Issue 7 July 2019

© All rights reserved by Bernardo Portugal Lasmar, *et al.*