

Primary Giant Calculus in Female Urethral Diverticulum: Report of a Rare Case

Ahmet Tevfik Yoldemir*

Department of Obstetrics and Gynecology, Marmara University, Turkey

***Corresponding Author:** Ahmet Tevfik Yoldemir, Associate Professor, Department of Obstetrics and Gynecology, Marmara University, School of Medicine, Istanbul, Turkey.

Received: January 3, 2015; **Published:** January 8, 2015

Abstract

Urethral diverticulum occurs in approximately 0.5-6% of women. Stone formation occurs in 1.5-10% of women with urethral diverticulum. Primary (native) urethral calculi occur rarely. In this case, 47 year-old woman suffering from recurrent urinary infections for the last 2 years referred to our clinic. Physical examination was normal except for a solid mass, measuring 3x3 cm in size, under the anterior vaginal wall mucosa, located at 3 cm to the external urethral orifice. Local excision of the mass was performed. Urethral calculus was removed after the incision was continued to the lumen of the diverticulum. After removing the calculi, the communication between the diverticulum and the urethral lumen was detected as the Foley catheter was seen through the vaginal incision.

Keywords: Urethral Diverticulum; Urethral calculus; Recurrent urinary infections

Introduction

In women, urethral diverticulum occurs in approximately 0.5-6% of the general population. Stone formation occurs in 1.5-10% of urethral Diverticulum [1] showing us that urethral calculi in women are extremely rare. Urethral calculi originating from the kidneys or the bladder may settle in the urethra because of a diverticulum or a stricture along the flow of the urine. Primary (native) urethral calculi (composed of magnesium ammonium phosphate) occur rarely and are frequently associated with a congenital urethral diverticulum [2].

The most common symptoms of urethral diverticulum are post-micturition dribbling, dysuria and dyspareunia. Marsupialization, endoscopic transurethral diverticulectomy and excision of urethral diverticula with/without bladder neck suspension are surgical interventions available for the patients with significant symptoms. We present a case of a 47-years old woman who had a primary giant calculus in her urethral diverticulum.

Case Report

A 47-year-old woman was seen in our outpatient clinic, suffering from recurrent urinary infections for the last 2 years. In her past medical history she had no history of abdominal or flank pain, sexual or urogynecological symptoms. Physical examination was normal except for a solid mass, measuring 3x3 cm in size, under the anterior vaginal wall mucosa, located at 3cm to the external urethral orifice. She had no stress incontinence on straining. A foley catheter was passed easily, revealing that there was no obstruction within the urethral lumen.

Plain x-ray of the lower abdomen demonstrated no calcification in the kidneys or the bladder. A renal ultrasound was performed and no significant evidence of hydronephrosis or renal calculi was detected. Translabial ultrasound revealed normal findings. The urinary

sediment was within normal limits and urine culture was negative for bacteria. Pelvic Magnetic Resonance Imaging (MRI) demonstrated a vaginal cystic mass. We planned to perform a local excision of the mass.

The patient was operated under general anesthesia and a 18 Fr Foley catheter was applied. A 3-cm long, longitudinal incision was made through the anterior vaginal wall over the bulge of the stone (Figure 1). Urethral calculus was removed after the incision was continued to the lumen of the diverticulum. After removing the calculi, the communication between the diverticulum and the urethral lumen was detected as the Foley catheter was seen through the vaginal incision (Figure 2). The diverticulum was dissected with the periurethral tissue. Diverticulectomy was performed. The defect in the urethral lumen was closed with 4-0 vicryl sutures. Cystoscopy was performed and the urethral lumen was intact. The vaginal mucosa was closed in two layers with 2-0 vicryl sutures. A 18 Fr Foley catheter drainage was obtained for 7 days.

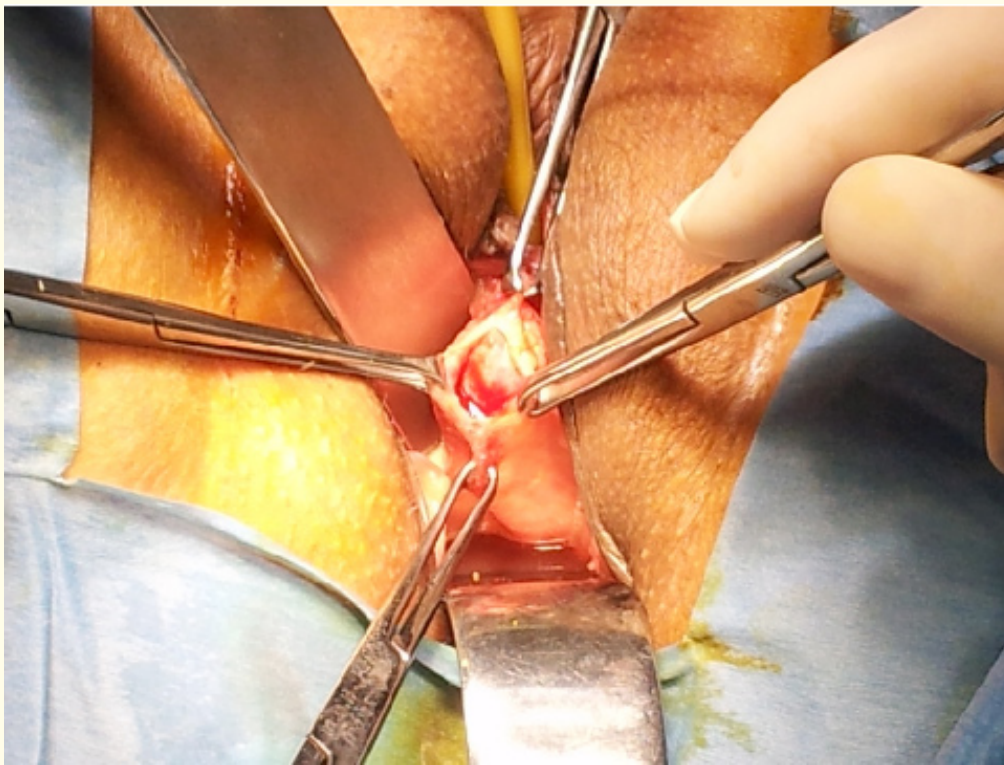


Figure 1: Longitudinal incision through the anterior vaginal wall over the bulge of the stone.

The stone was solid, dirty yellow, with a flat surface, 34 x 31 x 29 mm in size, and 29 grams in weight (Figure 3). Stone analysis revealed that the calculus was composed of magnesium ammonium phosphate. Her postoperative course was normal during the 3 months of follow-up. A postoperative uroflowmetry demonstrated no incontinence or voiding disorder (peak flow rate: 27 mL/sec, residual urine volume: 15 mL).

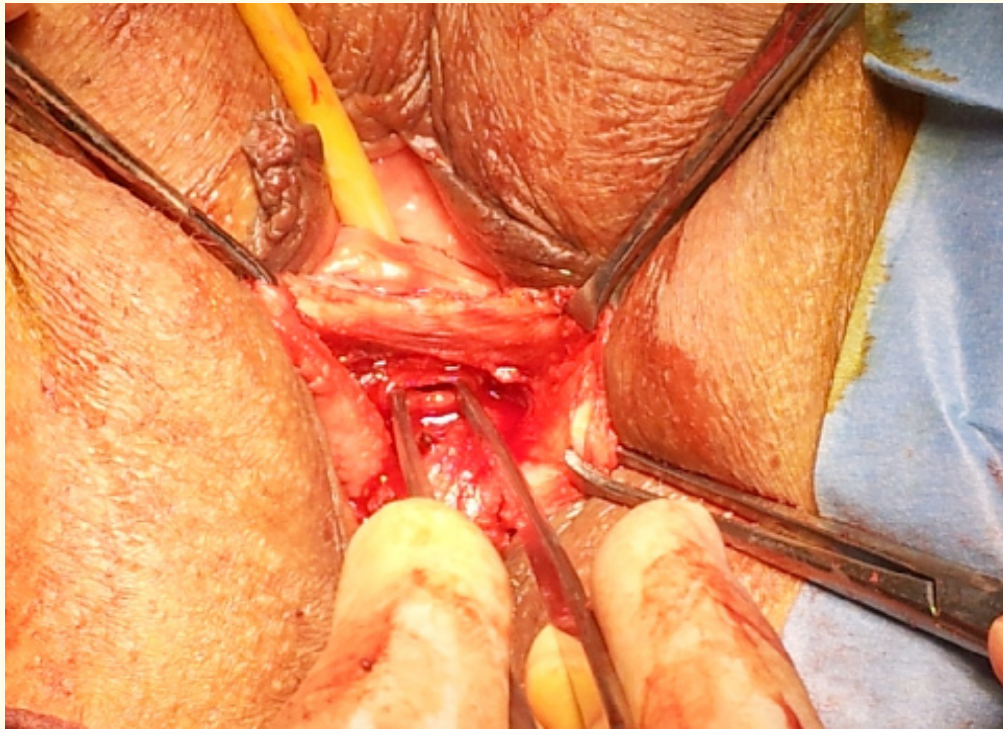


Figure 2: The communication between the diverticulum and the urethral lumen.

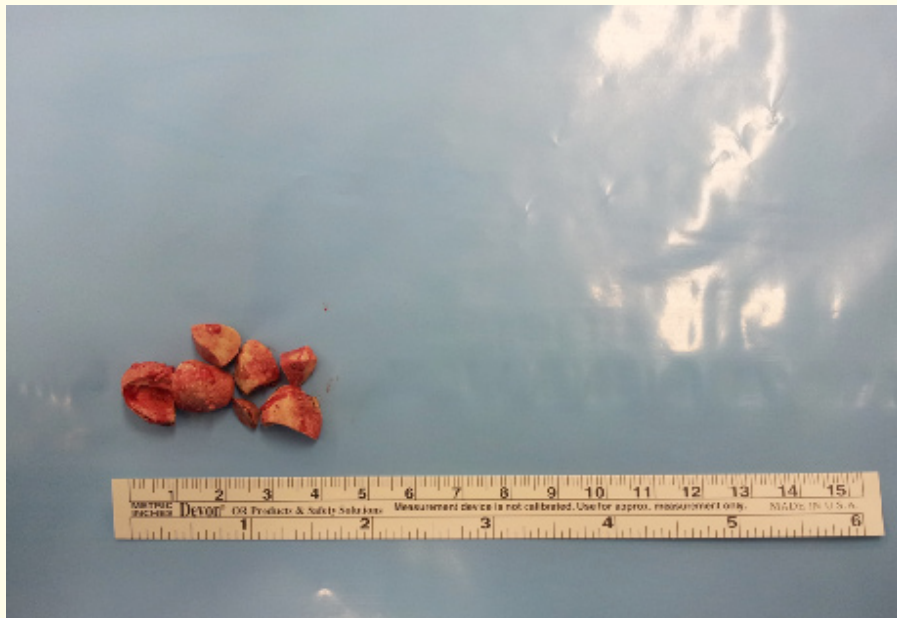

Figure 3: The stone, 29 grams in weight.

Discussion

Urethral calculi are % 90 native (those formed de novo in the urethra) or migratory (those formed in the bladder or kidney with secondary descent) [3]. Most native calculi form in association with chronic stasis and urinary infection, either within a urethral diverticulum or proximal to a urethral obstruction [4]. Recurrent infections of the paraurethral glands, obstetric trauma, vaginal surgery and iatrogenic collagen injection are responsible for the etiology [5].

Urethral calculi are rare and usually seen in men with an urethral stricture or Diverticulum [6]. Urethral calculi oftenly originate from the kidneys or the bladder and during the flow of the urine, calculi (composed of calcium oxalate and phosphate) may settle in the urethra due to a diverticulum or a stricture. Primary urethral calculi (composed of magnesium ammonium phosphate) occur rarely and are frequently associated with a congenital urethral diverticulum. In women, urethral diverticulum occur in approximately 0.6-6% of the general population [5]. Stone formation occurs in 1.5-10% of urethral diverticulum [1] showing us that urethral calculi in women are extremely rare.

Post-micturition dribbling (25% of general population), dysuria, dyspareunia (10% of general population), chronic pelvic pain and recurrent urinary infections are the most common symptoms of urethral diverticulum; but calculi located in a diverticulum may show no urine outflow disorders. In our case the woman had no urinary symptoms. Because the clinical presentation of urethral calculi is variable and nonspecific, it frequently makes correct diagnosis more challenging to identify in women. General awareness of this condition, detailed history, physical examination and appropriately selected radiologic imaging are essential for the diagnosis. None of the diagnostic tools we used for the differential diagnosis of our case confirmed the diagnosis. Diverticulum with calculus may also be presented asymptotically (20% of general population), which was the situation in our case. In any case of persistent urinary symptoms unresponsive to therapy, urethral diverticulum should be examined [7].

Urinary incontinence (60% of UD), urinary recurrent infection (30% of UD) [7], urinary obstruction, calculus formation, nephrogenic adenoma and malign degeneration are the main complications of urethral diverticulum [2]. The woman in our case had no urinary flow obstruction but a painless vaginal mass. Malignity occurs due to inflammation and chronic irritation, resulting in repeated hematuria and non-calcified filling defect (adenocarcinomas are the most common histologic type) [2,8].

The most important diagnostic finding of an urethral calculus is the palpable hard mass on the anterior vaginal wall lining the urethra [5], which apparent during the vaginal examination of the woman in our case. Structures which should be differentiated from urethral diverticula are ureteroceles, inclusion cysts, malign neoplasms of urethra or vagina, ectopic ureter, Bartholin's gland cysts and Gartner's duct cysts. Cystourethrography may be necessary to confirm the calculus in the urethral diverticulum; unless the calculus doesn't obliterate the opening of the diverticulum [3]. We did not perform this because there was no obvious obstruction in our case. Positive-Pressure Urethrography, Voiding Cystourethrography, Ultrasonography and MRI are currently used to confirm the diagnosis of the urethral diverticulum. MRI suggested the diagnosis of Bartholin's gland cyst in our case.

Conclusion

Patients having urethral diverticulum with non-significant symptoms may be followed and offered conservative treatments such as antibiotics, anticholinergics, aspiration and manual postvoid decompression. Marsipualization, endoscopic transurethral diverticulectomy and excision of urethral diverticula with/without bladder neck suspension are surgical interventions available. Excision of urethral diverticula with attention to the urethral patency can be achieved easily with relief of symptoms after the operation.

Bibliography

1. Skyggebjerg KD. "Female urethral diverticulum with calculus". *Acta Obstetrica et Gynecologica Scandinavica* 65.7 (1986): 797-798.
2. Aragona F, et al. "Stone formation in a female urethral diverticulum: review of the literature". *International Urology and Nephrology* 21.6 (1989): 621-625.
3. Larkin GL and JE Weber. "Giant urethral calculus: a rare cause of acute urinary retention". *The Journal of Emergency Medicine* 14.6 (1996): 707-709.
4. Ginsberg P and LH Finkelstein. "Urethral diverticulum with calculi: report of a case". *The Journal of the American Osteopathic Association* 82.8 (1983): 588-590.
5. Lee JW and MM Fynes. "Female urethral diverticula". *Best Practice & Research: Clinical Obstetrics & Gynaecology* 19.6 (2005): 875-893.
6. Suzuki Y, et al. "A case of primary giant calculus in female urethra". *International Urology and Nephrology* 29.2 (1997): 237-239.
7. Ganabathi K, et al. "Experience with the management of urethral diverticulum in 63 women". *Journal of Urology* 152.5 Pt 1 (1994): 1445-1452.
8. Seballos RM and RR Rich. "Clear cell adenocarcinoma arising from a urethral diverticulum". *Journal of Urology* 153.6 (1995): 1914-191.

Volume 1 Issue 1 January 2015

© All rights are reserved by Ahmet Tevfik Yoldemir.