

## Results of Laser-Based Treatment for Perianal Fistulae

**EV Denisenko\***

*Vitebsk State Medical University, Belarus*

**\*Corresponding Author:** EV Denisenko, Vitebsk State Medical University, Belarus.

**Received:** August 30, 2021; **Published:** September 09, 2021

### Abstract

This work evaluates the results of using laser-based destruction for the treatment of perianal fistulae. A prospective study was carried out on 27 patients with perianal fistulae (14 men, 13 women). The surgery involved closure of the internal fistula opening with sutures, insertion of a laser light guide into the external opening of the fistula and destruction of the latter. This minimally invasive procedure allows to manage the fistula without traumatic incisions and to perform anesthesia with non-narcotic analgesics, as well as to reduce the procedure duration and recovery time.

**Keywords:** *Fistula; Perianal Fistula; Treatment for Fistula*

### The Urgency of the Problems

A perianal fistula is a long-term inflammatory process represented by a fistulous passage in the paraproctium that opens into the rectal lumen with an external fistula opening (most often represented by the anal crypt) and an internal fistula opening (on the perineal skin, perianal area, buttocks or vagina in women). The problem of paraproctitis is urgent. The prevalence of chronic paraproctitis reaches 23 cases per 100,000 people [1,4]. Chronic paraproctitis makes up 25 - 30% of rectal diseases [2,5,6]. It is more frequent in men and occurs in young and middle aged patients [1]. With regard to the anal gland, fistulae are classified into intrasphincteric (45%), transsphincteric (30%), suprasphincteric (5%) and extrasphincteric (2%) [3,7]. Currently, the choice of surgical treatment for pararectal fistulas is a subject of discussion because of various fistula configurations.

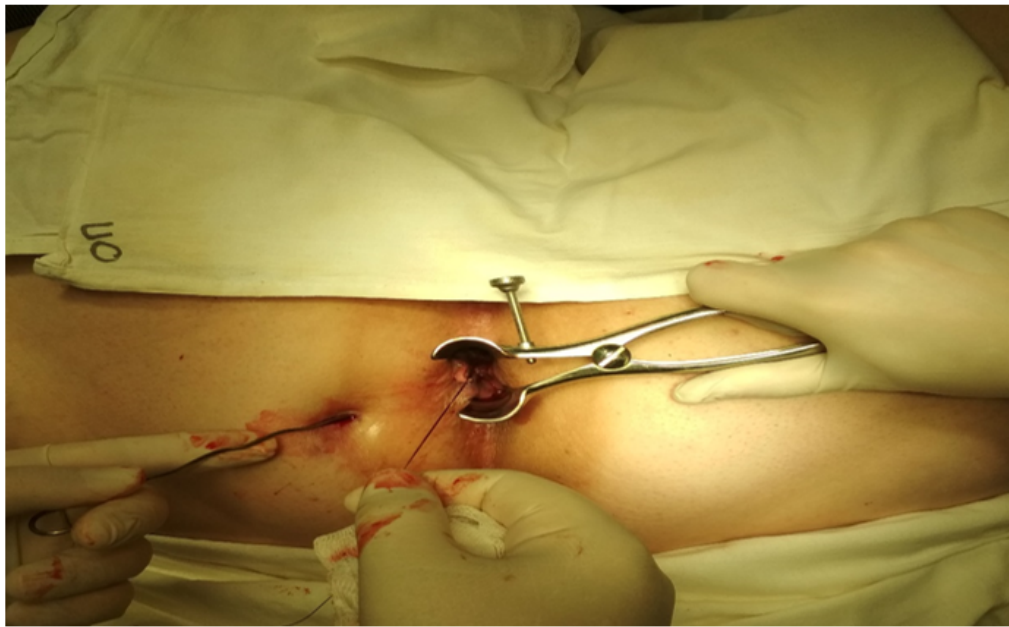
### Purpose of the Study

To evaluate the results of using laser-based destruction for the treatment of perianal fistulae.

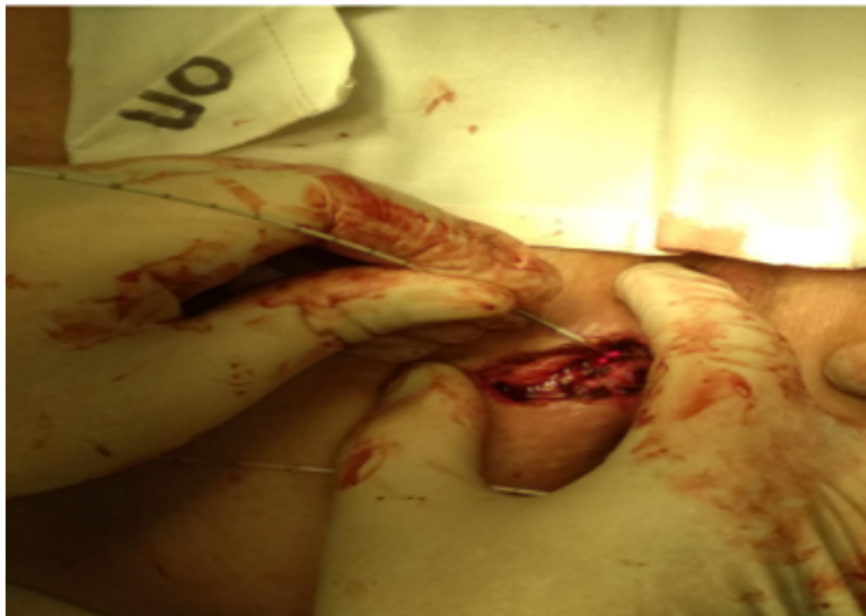### Materials and Methods

Between September 2019 and February 2021, a prospective study was carried out on 27 patients aged 22 - 71 (the mean age was 50.4 ± 12.4 years (M ± σ)), 14 males and 13 females. The procedure was performed under spinal anesthesia. Anoscopy and fistula revision were carried out with a bulbous-end probe (Figure 1).

Fistula destruction was performed using a radial laser light guide (with the wave length of 1560 nm, and the power capacity of 10W, Figure 2).



*Figure 1: Fistula revision with a bulbous-end probe.*

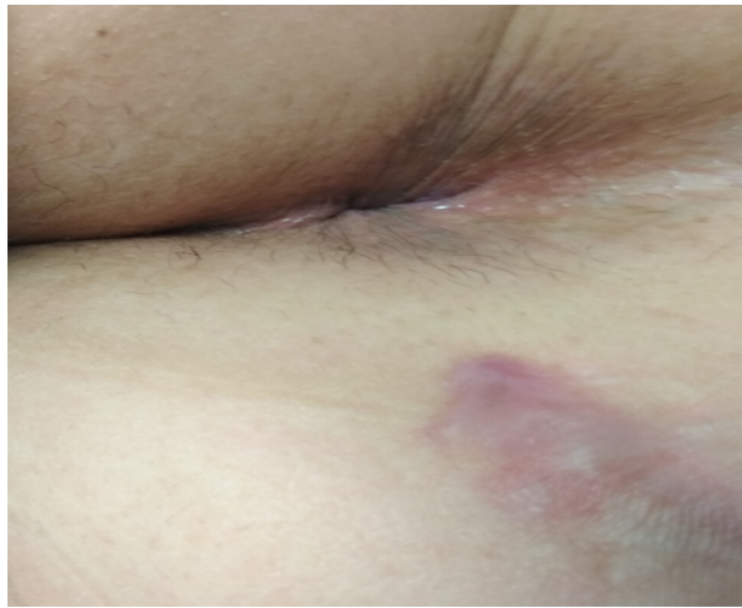

*Figure 2: Fistula destruction using a radial laser light guide.*

The laser light guide was introduced through the external to the internal orifice. Then the destruction of the fistula was performed while the light guide was withdrawn to its external orifice. All patients received the planned amount of interference. The following efficiency criteria were analyzed: duration of the surgical procedure, duration and intensity of pain sensation, length of hospital stay, complications in the early postoperative period, disease recurrence. PSPP software was used to perform the statistical analysis of data.

### Results and Discussion

On average, the surgical procedure lasted  $17.7 \pm 4.5$  minutes ( $M \pm \sigma$ ). The average hospital stay length was  $6.5 \pm 2.7$  days ( $M \pm \sigma$ ). In the early postoperative period, anesthesia was managed with non-narcotic analgesics (Ketanov 1.0 v/m for pain relief); no narcotic analgesics were required. No complications were observed in the early postoperative period. The wounds were closed within  $15 \pm 2.3$  days (Figure 3).



**Figure 3:** The result of laser-based destruction of the perianal fistula 15 days after the procedure.

Over the whole observation period and during the survey in March 2021, six disease recurrences were found. Disease recurrences are caused by the large diameter of the fistula with tortuosity of its channel.

### Conclusion

This minimally invasive treatment technique for perianal fistulae can be described as promising. This is attributable to the fact that when it is used, the pain is not intense. The surgical procedure and hospital stay duration is reduced. No complications are observed in the early postoperative period during the evaluation period.

### Bibliography

1. IS Bogormistrov., *et al.* "Khirurgicheskie metody lecheniya ekstraspinkrternykh i transpinkrternykh svischey pryamoy kishki". *Russian Journal of Gastroenterology, Hepatology, Coloproctology* 25.4 (2015): 92-100.
2. AM Madaminov., *et al.* "Sposob khirurgicheskogo lecheniya transspinkrternykh i ekstraspinkrternykh svischey pryamoy". *kishki Vestnik KRSU* 15.7 (2015): 99-101.
3. YuA Shelygin., *et al.* "Klinicheskie rekomendatsii". *Koloproktologia* (2015): 528.
4. KW Göttgens., *et al.* "Long-term results of mucosal advancement flap combined with platelet-rich plasma for high cryptoglandular perianal fistulas". *Diseases of the Colon and Rectum* 57.2 (2014): 223-227.
5. P Giamundo. "Closure of fistula-in-ano with laser--FiLaC™: an effective novel sphincter-saving procedure for complex disease". *Colorectal Disease* 16.2 (2014): 110-115.
6. Gecim IE., *et al.* "Endoscopic pilonidal sinus treatment combined with crystalized phenol application may prevent recurrence". *Diseases of the Colon and Rectum* 60.4 (2017): 405-407.
7. SR Hokkanen. "Prevalence of anal fistula in the United Kingdom". *World Journal of Clinical Cases* 7.14 (2019): 1795-1804.

**Volume 8 Issue 10 October 2021**

**©All rights reserved by EV Denisenko.**