

## Pancreatic Primitive Hydatid Cyst: A Case Report and a Literature Review

**Gutierrez Camila\*, Gil Ramiro, D'Andrea Ricardo and Granero Lucas**

*Departamento de Cirugía, Servicio de Cirugía General, Nuevo Hospital San Roque, Córdoba Capital, Argentina*

**\*Corresponding Author:** Gutierrez Camila, Departamento de Cirugía, Servicio de Cirugía General, Nuevo Hospital San Roque, Córdoba Capital, Argentina.

**Received:** April 15, 2021; **Published:** May 17, 2021

### Abstract

Hydatidosis is a parasitic disease, endemic to our region, caused by the microorganism *Echinococcus granulosus*. Its most frequent location is hepatic and pulmonary, this presentation being often silent for many years due to the elasticity of the tissues in which it sits. The pancreatic commitment is infrequent even in endemic areas, being in our center, the first case reported.

**Keywords:** *Pancreatic Hydatid Cyst; Echinococcus; Pancreas*

### Abbreviations

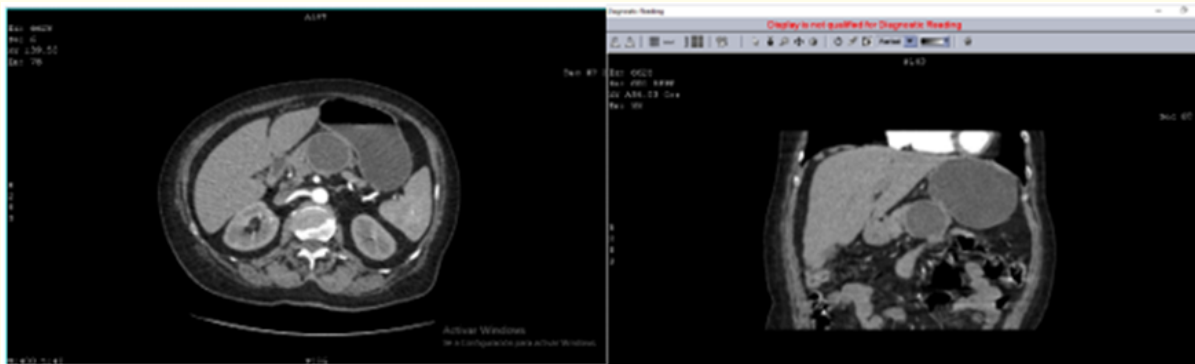
CT: Computed Tomography; NMR: Nuclear Magnetic Resonance

### Introduction

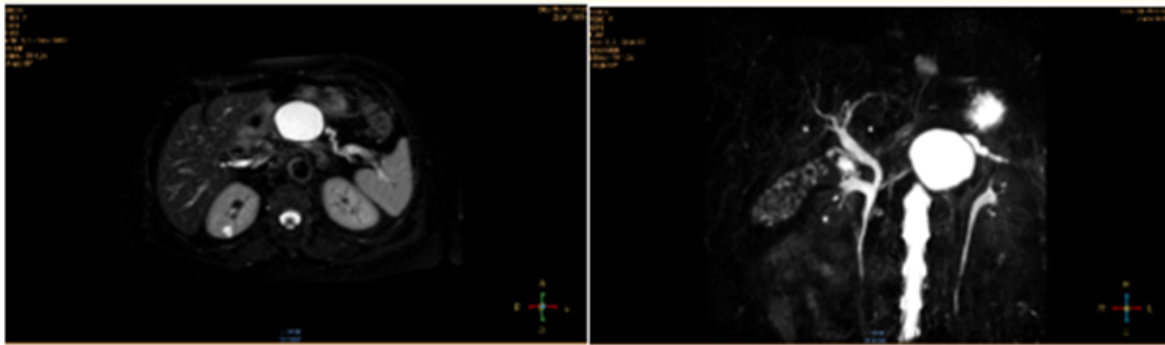
Hydatidosis is a disease that frequently affects the liver and lung, however other less frequent forms have been described such as brain, kidney, muscle, heart, bone and pancreas representing less than 10% of the total [1,2]. The pancreatic location is unusual, with descriptions in the bibliography of 0.2 to 2% of the total. Of these, the most common form is solitary cysts in the head 50%, body 30% and tail 20% [3].

### Clinical Case

A 60-year-old female patient is presented who consulted for abdominal pain located in the epigastrium of insidious onset, progressive, moderate intensity. An abdominal ultrasound shows a cyst in the body of the pancreas, for which a triphasic abdominal tomography (CT) is indicated (Figure 1) and then magnetic resonance imaging (MRI) with intravenous contrast (Figure 2); Reporting at the caudal corporeal level, unilocular cystic formation with thin walls 48 x 56 mm in diameter with caudal atrophy and dilatation of the Wirsung duct. Negative ELISA test for hydatidosis is also reported.

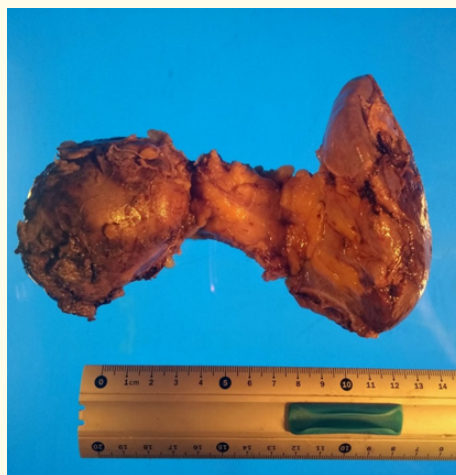

**Figure 1:** CT arterial phase axial and coronal section, showing a solid-cystic tumor in the body and tail of the pancreas measuring approximately 5 x 5 cm.



**Figure 2:** T2 MRI of the abdomen, axial section and non-contrast biliary reconstruction showing a lesion in the distal pancreas.

The patient continued with an increase in symptoms for which a surgical procedure was decided, performing a caudal corporeal pan-creatotomy plus splenectomy by video laparoscopy (Figure 3 the surgical specimen is detailed).



**Figure 3:** Surgical specimen for corporocaudal pancreatectomy and splenectomy.

The patient presented good postoperative evolution, drainage was removed on the fifth and discharged on the seventh day without complications.

The pathological anatomy study reported: her pancreatic hydatid cyst, with chronic perilesional inflammatory reaction. Figure 4 shows the microscopy of the lesion.

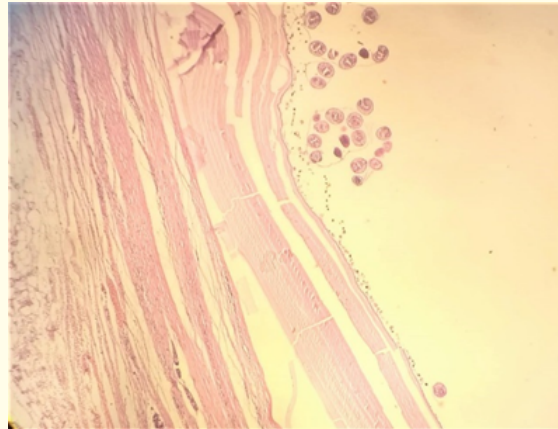


Figure 4: Microscopy, reports pancreatic hydatid cyst.

## Discussion and Conclusion

Hydatidosis or cystic echinococcosis (CS) is a zoonosis caused by the larval stage of the *Echinococcus granulosus* basket, responsible for significant morbidity and mortality throughout the world [1].

Infection by this parasite has a cosmopolitan geographical distribution and cases have been described on all continents, the regions with the highest prevalence worldwide are: Europe, Asia (Mediterranean region, Russia and the People's Republic of China), Africa (north-east region), Australia and South America.

In South America, the disease exists in most countries, but Argentina, Bolivia, Brazil, Peru and Uruguay are those where hydatidosis constitutes an important Public Health problem [2].

In Argentina, hydatidosis is widespread throughout the national territory and is more prevalent in rural areas, especially in sheep and goat rearing areas. It is estimated that approximately 30% of the national territory is the seat of the zoonotic cycle of *Echinococcus granulosus* [2]. During 2010, 385 cases of hydatidosis throughout the country were notified to the National Health Surveillance System, Córdoba being one of the most affected provinces [2].

In South America, few cases have been reported, the last being in Chile 2008, and in Lima 2016 [4,5].

Several ways of arrival of the parasite to pancreatic tissue have been described, the most accepted is the hematogenous route, crossing the hepatic and pulmonary filter [6].

The usual presentation is in the fifth or sixth decade of life, with epigastric or asymptomatic pain, sometimes associated with anorexia and weight loss; due to its slow growth, described in the bibliography of approximately 0.3 to 2 cm per year [7]. They can also present jaundice, choloria and acholia if the location is cephalic.

Diagnosis is based on epidemiologic history, clinical findings, imaging studies, and serology. Ultrasound is the first study for the diagnosis of parasitosis located in the abdomen (number, size and vitality of cysts) and also allows the visualization of cysts in other organs; However, CT and MRI are the main studies to determine with certainty the characteristics of the lesions [8].

ELISA and Western Blot serological studies confirm the imaging diagnosis, however they are not always confirmatory, being only 85% positive, since there is a percentage of false negatives; Furthermore, the specificity of these tests is limited due to cross-reactions with other pathologies [8].

The Gold Standard for diagnosis is confirmatory histology.

Treatment options include medical treatment, percutaneous drainage (PAIR) and laparoscopic or conventional open surgery. These depend mainly on the location, size and symptoms of each patient [9]. If the cyst is located distally, the best approach is laparoscopic with splenic preservation; In the case that it is not possible due to technical difficulty or invasion of the hilum, the spleen is resected with subsequent immunological care [5].

In our case, the patient underwent a laparoscopic corporocaudal pancreatectomy with splenectomy, due to its location and the lack of diagnostic confirmation [5].

Before and after the surgical approach, oral antiparasitic therapy with Albendazole should be established for 2 to 4 weeks, thus reducing the appearance of recurrences and the risk of intra-surgical dissemination in the event of cyst rupture [7]. Albendazole treatment and its resection is the most recommended therapy worldwide [9].

Post-surgical complications are rare, among them the most frequent is pancreatic fistula, biliary leak, abscess, surgical wound infection and disease recurrence, the latter being reported in 10% worldwide [7].

In conclusion, we can say that pancreatic hydatid disease is rare but must be included among the differential diagnoses in our region, since this disease is an endemic entity in our province. All patients with pancreatic cysts should be investigated for their epidemiology and serology requested to confirm it. If this is negative, the diagnosis should not be ruled out until histological confirmation is obtained.

Regarding the approach, we always recommend performing it by video laparoscopy by specialized surgeons, since it presents better tolerance and faster recovery of patients; thus reducing the hospital stay and associated morbidity offered by minimally invasive surgery.

### Bibliography

1. Faraj W., *et al.* "Laparoscopic resection of pancreatic hydatid disease". *Surgery* 139.3 (2006): 438-441.
2. Enfermedades infecciosas, hidatidosis. Guia para el manejo. Ministerio de salud de la nación Argentina (2012).
3. Dahniya MH., *et al.* "The imaging appearances of hydatid disease at some unusual sites". *British Journal of Radiology* 74.879 (2001): 283-289.

4. Csendes J., *et al.* "Quiste hidatídico pancreático. Reporte de un caso". *Revista Chilena de Cirugía* 60.2 (2008): 158-161.
5. Revoredo Rego F., *et al.* *Revista de Gastroenterología del Perú* 36.3 (2016): 264-268.
6. Krige JE., *et al.* "Primary hydatid cysts of the pancreas". *South African Journal of Surgery* 43.2 (2005): 37-40.
7. Akbulut S., *et al.* "Hydatid cyst oh the pancreas: report of an undiagnosed case of pancreatic hydatid cyst and brief literature review". *World Journal of Gastrointestinal Surgery* 6.10 (2014): 190-200.
8. Uribarren Berrueta T. "Hidatidosis, equinococosis o quiste hidatídico". Departamento de Microbiología y Parasitología Facultad de Medicina de México (2015).
9. Trigui A., *et al.* "Hydatid cyst of the pancreas about 12 cases". *Annali Italiani di Chirurgia* 84.2 (2013): 165-170.

**Volume 8 Issue 6 June 2021**

**©All rights reserved by Gutierrez Camila., *et al.***