

## Locor-Regional Pelvic Relapse of Edge and Anal Canal Epidermoid Carcinoma

Osmaldy Alpizar Quesada<sup>1\*</sup>, Regla de la Caridad Espinosa Luis<sup>2</sup> and Dayan Cervantes Pelaez<sup>3</sup>

<sup>1</sup>Especialista de Primer Grado en Coloproctología, Especialista de Primer Grado en Medicina General Integral, Profesor Instructor, Hospital General Provincial Docente "Dr. Antonio Luaces Iraola", Ciego de Ávila, Cuba

<sup>2</sup>Especialista de Primer Grado en Coloproctología, Hospital General Provincial Docente "Dr. Antonio Luaces Iraola", Ciego de Ávila, Cuba

<sup>3</sup>Especialista de Primer Grado en Coloproctología, Profesor Instructor, Hospital Oncológico Provincial Docente "Maria Curie", Camagüey, Cuba

**\*Corresponding Author:** Osmaldy Alpizar Quesada, Especialista de Primer Grado en Coloproctología, Especialista de Primer Grado en Medicina General Integral, Profesor Instructor, Hospital General Provincial Docente "Dr. Antonio Luaces Iraola", Ciego de Ávila, Cuba.

**Received:** March 09, 2020; **Published:** March 29, 2021

### Abstract

**Introduction:** Pelvic relapse is a condition that significantly affects the quality of life of patients operated on for rectal and anal cancer. Surgical treatment with curative intent of this entity presents a high morbidity in the short and long term. Despite the patient having been treated at first with curative intent and an adequate surgical technique, when relapse occurs it is common that the lesion cannot be resected given its relationship with the lateral wall of the pelvis.

**Objective:** To present the case of a patient with locoregional pelvic relapse of squamous epidermoid carcinoma of the anal rim and canal, due to the complexity of this type of surgical intervention.

**Case Presentation:** 58-year-old white female patient with a history of previous surgery for squamous epidermoid carcinoma of the rim and anal canal where a Milles-type abdominoperineal amputation was performed. She attended the Coloproctology consultation 18 months after the surgical intervention, reporting a sensation of a perineal mass. On physical examination, two perineal tumors were found. The results of the laboratory tests were normal. Soft tissue ultrasound and computerized axial tomography confirmed the existence of tumors. By histological analysis a squamous epidermoid carcinoma was diagnosed. Radical resection of both tumors, 10 cm of the posterior aspect and both lateral aspects of the vagina, bilateral skin flaps in V and vaginal plasty were performed.

**Conclusion:** The best alternative for the treatment of pelvic relapse is radical tumor surgery following oncological principles. Palliative procedures are indicated for the relief of symptoms and a better quality of life for the patient.

**Keywords:** Pelvic Relapse; Squamous Cell Carcinoma

### Introduction

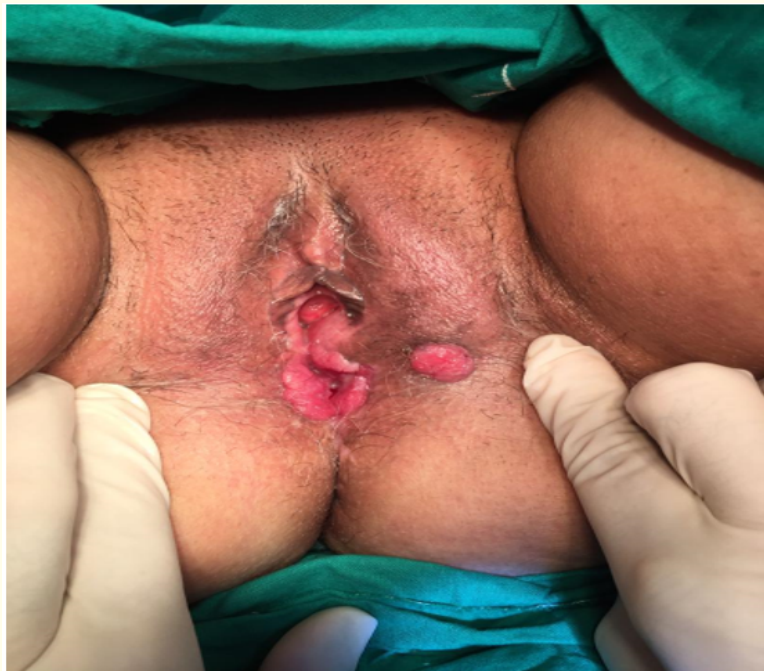Pelvic relapse is a condition that significantly affects the quality of life of patients operated on for rectal and anal cancer [1,2]. The incidence of this entity ranges between 3% and 45% 5 years after surgery [3]. The curative surgical approach requires extensive resections and presents high morbidity in the short and long term. Despite the patient having been treated at first with curative intent and an

adequate surgical technique, when relapse occurs it is common that the lesion cannot be resected given its relationship with the lateral wall of the pelvis. It is important to remove the tumor and possible locoregional lymphatic drainage [4,5]. After extensive resections, reconstruction should be as physiological as possible. For proper repair, the use of synthetic or biological flaps and prostheses is necessary [6]. Palliative surgeries do not have better survival rates and are generally associated with high rates of morbidity and mortality [7].

This work aims to present the case of a patient with a diagnosis of locoregional pelvic relapse of squamous epidermoid carcinoma of the anal rim and canal, due to the complexity of this type of surgical intervention and the importance of adequate surgical management to reduce the morbidity and mortality rates.

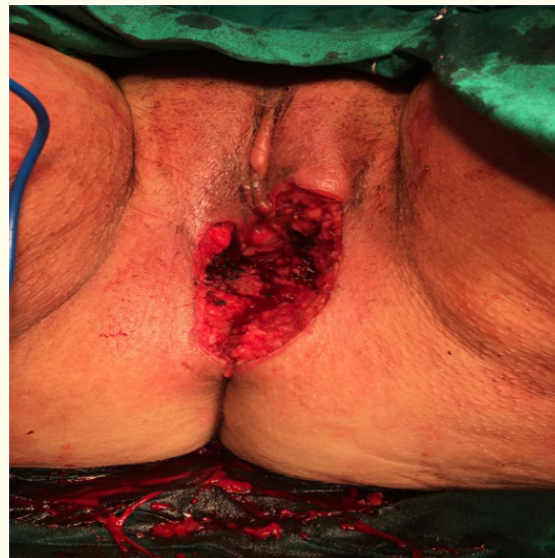
**Presentation of the Case**

**Case presentation:** A 58-year-old white female patient with a history of previous surgery for stage III A squamous cell carcinoma of the rim and anal canal. She received treatment with chemoradiotherapy and subsequently a Milles-type abdominoperineal amputation was performed. She attended the Coloproctology consultation 18 months after the surgical intervention, reporting a sensation of a perineal mass. Physical examination revealed a tumor with an irregular surface and a hard consistency, measuring approximately 5 centimeters on the posterior and left side of the vagina, and another tumor with the same characteristics of 1 centimeter on the skin of the anterior perineum (Figure 1).



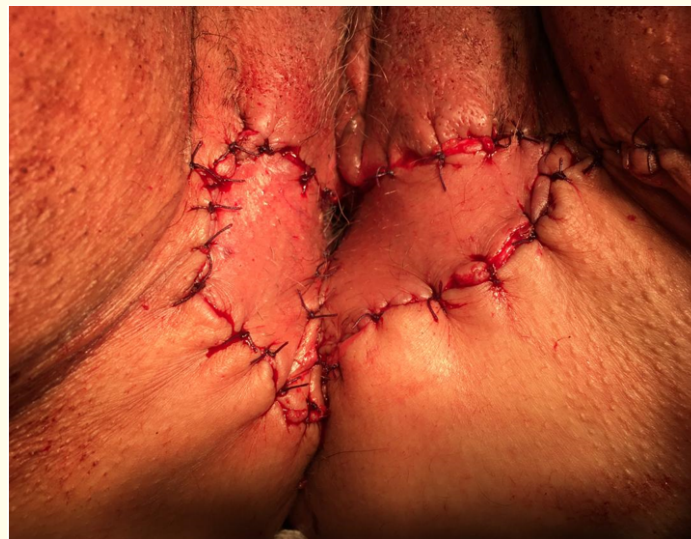**Figure 1:** Physical examination. Note tumor on the left and posterior side of the vagina and tumor in the anterior perineum’.

The results of the laboratory tests were normal. Soft tissue ultrasound reported the presence of 2 irregular and heterogeneous tumors in the perineum measuring 5 x 7 centimeters and 2 x 3 centimeters respectively. The computerized axial tomography confirmed the existence of two perineal tumors with the measurements and the location indicated in the ultrasound and increased uptake of contrast media. By histological analysis a squamous epidermoid carcinoma was diagnosed. Radical resection of both tumors was performed, 10 centimeters of the posterior aspect and both lateral aspects of the vagina (Figure 2).



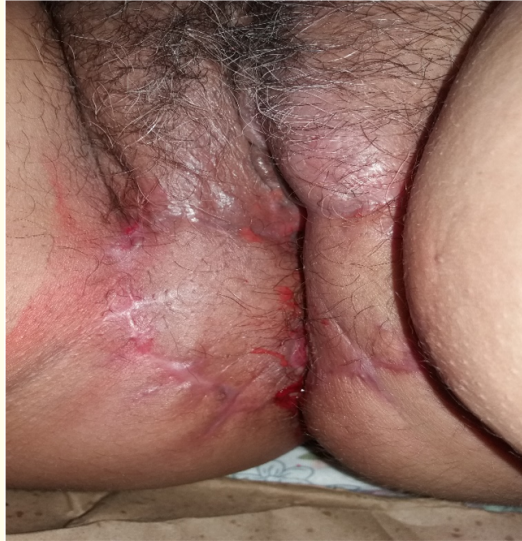*Figure 2: Surgical approach. Note resection of the posterior wall and both lateral vaginal walls.*

Bilateral V skin flaps and vaginal plasty were necessary (Figure 3).



*Figure 3: Surgical approach. Note the bilateral V-shaped skin flaps.*

The patient evolved satisfactorily and after 8 weeks postoperative, full recovery from the surgery performed was observed (Figure 4).



**Figure 4:** Postoperative recovery. Note healing of the surgical wound.

## Discussion

Locoregional recurrence of rectal and anal cancer after curative surgery of the primary tumor constitutes a great therapeutic challenge for colorectal surgeons. Radical resection continues to prove to be the only curative option for this entity [5,6]. Prior to total excision of the mesorectum, recurrence ranged from 20% to 40% [7,8]. The association of surgical treatment with neoadjuvant cancer treatment has influenced the decrease in the percentage of recurrence between 2.6 and 10% [8,9]. In most cases, recurrence occurs in patients The first 2 years after surgery of the primary tumor, although it can present later in up to 36% of cases [10].

A change in the location pattern of pelvic recurrences has been observed, since total excision of the mesorectum leads to less centrally located recurrence, with a predominance of lateral and posterior recurrences [11]. Median survival after diagnosis of local recurrence is 7 months without treatment, with a 5-year survival of less than 5%. However, overall survival under multidisciplinary treatment can reach 40%.

Between 15 and 20% of patients present metastasis at the time of diagnosis and 30% will develop distant metastases after radical surgery. Currently, the only curative treatment is radical resection, with the aim of achieving complete excision, associated or not with specific cancer treatment [12].

Palliative surgeries do not have better survival rates and are generally associated with high rates of morbidity and mortality [7].

### Conclusion

The best surgical alternative for pelvic relapses continues to be radical surgery following oncological principles. Resection should be done en bloc. Palliative surgeries do not have better survival rates and are generally associated with high rates of morbidity and mortality, these are reserved for selected cases with the aim of alleviating symptoms and improving the quality of life of patients.

### Bibliography

1. Bhangu A., *et al.* "Indications and Outcome of Pelvic Exenteration for Locally Advanced Primary and Recurrent Rectal Cancer". *Annals of Surgery* (2013).
2. Cunningham JD., *et al.* "Salvaje therapy for pelvic recurrence following curative rectal cancer resection". *Diseases of the Colon and Rectum* 40 (1997): 393.
3. Ferreira F., *et al.* "Reintervención en la recidiva del cancer colo-rectal". In: Eugenio Américo Bueno Ferreira, Samir Rasslan Hernando Abaunza Orjuela, Favio de Oliveira Ferreira. (Org.). *Problemas complejos en cirugía abdominal*. 1ed. Sao Paulo: Atheneu 1 (2003): 135-146.
4. Kim J. "Pelvic exenteration: surgical approaches". *Korean Medical Journal Information* 28.6 (2012): 286-293.
5. Patt Y Peters R., *et al.* "Palliation of pelvic recurrence of colorectal cancer with intra- arterial 5-fluoracil and mitomycin". *Cancer* 56 (1985): 2175.
6. Boyle KM., *et al.* "Surgery for locally recurrent rectal cancer". *Diseases of the Colon and Rectum* 48 (2005): 929-937.
7. García-Granero E., *et al.* "Extended resection and pelvic exenteration in distal third rectal cancer". *Cirugía Española* 92.1 (2014): 40-47.
8. Bouchard P and Efron J. "Management of recurrent rectal cancer". *Annals of Surgical Oncology* 17 (2010): 1343-1356.
9. Rahbari NN., *et al.* "Surgery for locally recurrent rectal cancer in the era of total mesorectal excision". *Annals of Surgery* 253 (2011): 522-533.
10. Palmer G., *et al.* "A population based study on the management and outcome in patients with locally recurrent rectal cancer". *Annals of Surgical Oncology* 14 (2007): 447-454.
11. Bakx R., *et al.* "Management of recurrent rectal cancer: A population based study in greater Amsterdam". *World Journal of Gastroenterology* 14 (2008): 6018-6023.
12. Klose J., *et al.* "Impact of anatomic location on locally recurrent rectal cancer: Superior outcome for intraluminal tumour recurrence". *The Journal of Gastrointestinal Surgery* 112 (2015): 3-31.

**Volume 8 Issue 4 April 2021**

**©All rights reserved by Osmaldy Alpizar Quesada., *et al.***