

Combined Acquired Abdominal and Transdiaphragmatic Intercostal Hernia: A Case Report

Salam Abou Rafeh¹, Dana Semaan¹ and Ayman Obeid^{2*}

¹*Lebanese American University School of Medicine, Byblos, Lebanon*

²*Rafic Hariri University Hospital, Beirut, Lebanon*

***Corresponding Author:** Ayman Obeid, Rafic Hariri University Hospital, Beirut, Lebanon.

Received: October 12, 2020; **Published:** January 30, 2021

Abstract

Background: Intercostal hernias are rare types of hernias occurring mainly due to trauma to the chest wall. There are two main types, acquired abdominal intercostal hernia and transdiaphragmatic intercostal hernia. The occurrence of each one alone is uncommon, however the parallel presentation of both types in the same patient is highly unusual.

Case Report: A 40 years old male presented with a one year history of a bulge over the left chest wall almost 7 years after penetrating and blunt trauma to the left chest wall. He was found to have both an acquired abdominal intercostal hernia and a transdiaphragmatic intercostal hernia. Both defects were repaired successfully through a laparotomy with reduction of hernia contents and repair using a prosthetic mesh.

Conclusion: The diagnosis of intercostal hernias should be considered in patients presenting with a swelling on the chest wall particularly after any form of trauma to the area. Imaging may guide diagnosis however it is mostly clinical. Most cases need surgical repair.

Keywords: *Intercostal Hernia; Acquired Abdominal Intercostal Hernia (AAIH); Transdiaphragmatic Intercostal Hernia (TDIH)*

Introduction

Intercostal hernia is a rare complication seen after traumatic or iatrogenic loss of a rib segment resulting in a defect in the thoracoabdominal wall. This causes herniation of fascial layers between the ribs that may be empty or contain abdominal organs [1]. A review of the literature reveals two distinct types of intercostal hernias: acquired abdominal intercostal hernia (AAIH) and transdiaphragmatic intercostal hernia (TDIH) [2]. These two entities are distinct in their etiologies, clinical presentation, and management. There are no reports of concurrent AAIH and TDIH in the literature. There are less than 40 cases of TDIH reported in the literature [3] and 19 cases of AAIH [2]. This report presents a case of combined AAIH and TDIH seen concomitantly in one patient.

Case Presentation

This is a forty years old male, victim of a wartime casualty, presenting with a bulging mass over the left chest that has been increasing in size during the past year. In 2012 the patient sustained a penetrating trauma from an explosive device. At the time he underwent a life-saving left lateral thoracotomy and splenectomy through the same incision at field military facility. Due to his extensive injuries at the time he also had partial resection of the 7th, 8th and 9th left ribs. In 2014 the patient underwent a midline laparotomy at a different hospital for a ventral hernia repair. In August of 2019 the patient presented to our hospital with a bulge in the left chest overlying the thoracotomy incision scar. The bulge has been present for the past year and was slowly increasing in size, however it was soft, non-painful and easily reducible (Figure 1). Chest X-ray showed a defect over the left chest wall at the mid-axillary line with what appeared to be bowel loops protruding through the defect (Figure 2).

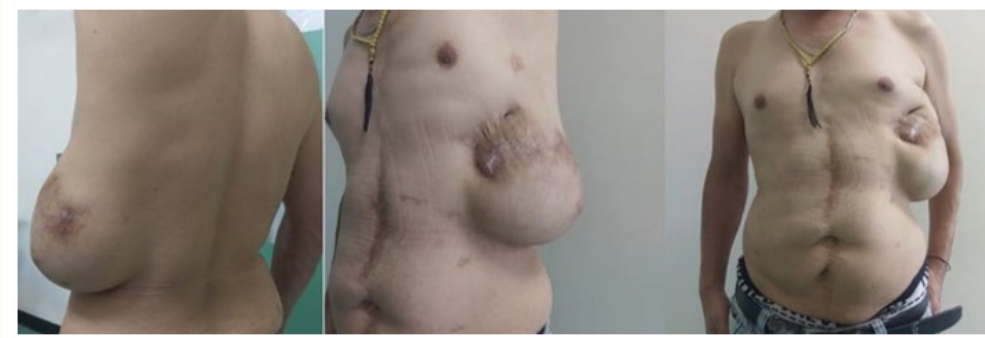

Figure 1: Preoperative pictures showing a left sided hernia across the left chest wall overlying a surgical scar.

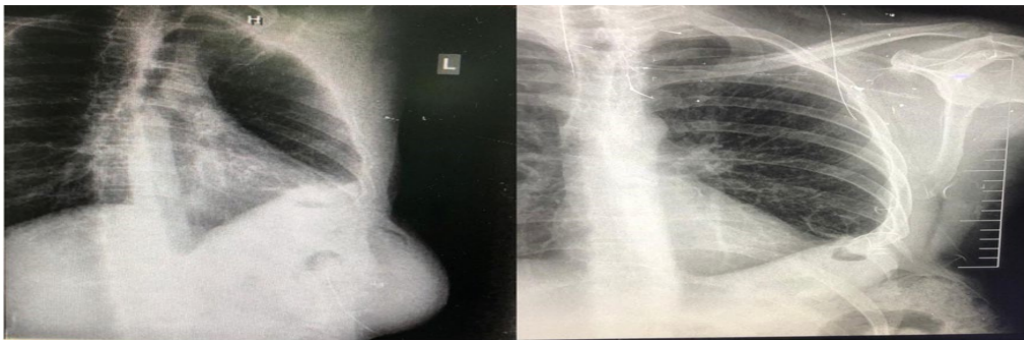


Figure 2: Chest X-ray showing a defect in the left chest wall containing what appears to be bowel loops.

CT scan of the chest and abdomen revealed a left thoracic cage defect with a neck of 10 cm containing the transverse colon, jejunal loops and their associated mesentery (Figure 3 and 4).

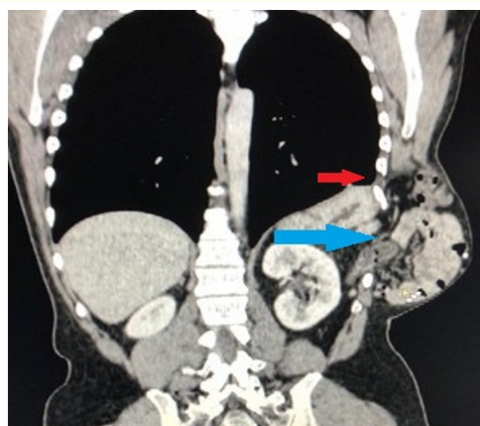


Figure 3: CT scan of the chest and abdomen showing AAIH with protrusion of the transverse colon, small bowel loops and the stomach (blue arrow); and TDIH with omentum herniating through diaphragmatic defect into the same cavity (red arrow).

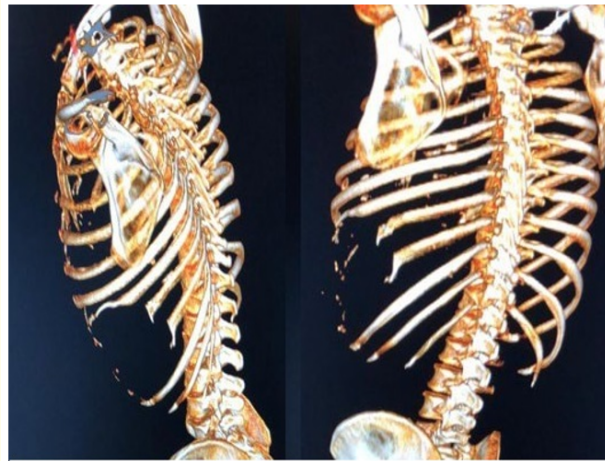


Figure 4: Reconstruction of the chest wall from the CT scan showing the remnants of the 8th, and 9th ribs.

The repair was done using an indirect approach along the previous laparotomy scar. The peritoneal cavity showed significant adhesions which were lysed to visualize the defect. The stomach, small bowel loops, transverse colon, and omentum were seen in the defect. After reducing the hernia contents the defect was measured to be 10 x 15 cm along the midshafts of partially excised 8th and 9th left ribs (Figure 5).

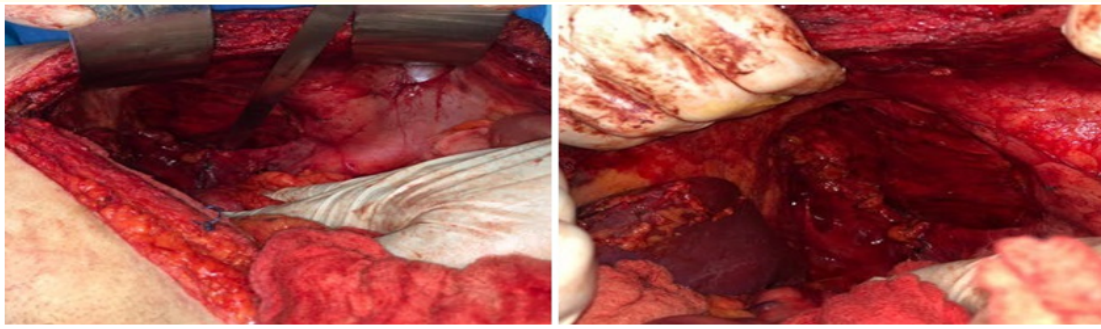


Figure 5: The defect measuring 10 x 15 cm after reduction of the contents.

A 3 cm diaphragmatic hernia was noted to contain omentum which was also reduced and closed primarily with prolene sutures (Figure 6).

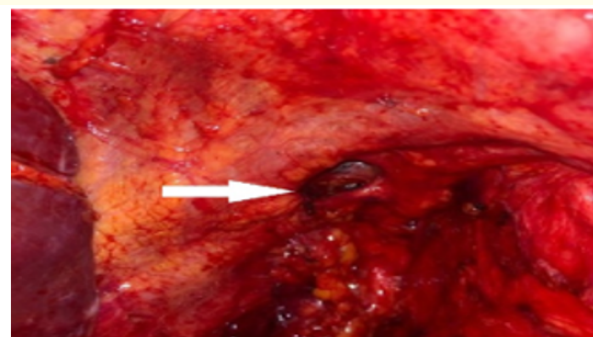


Figure 6: A 3 cm diaphragmatic defect was found that contained omentum.

The large defect was covered with a 25 x 20 cm composite dual Parietex™ mesh with 5 cm overlap of the defect, this also covered the diaphragmatic hernia (Figure 7).

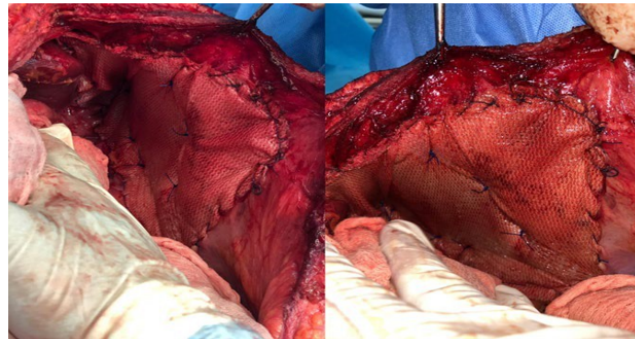


Figure 7: 25 x 20 cm composite dual Parietex™ mesh over the defect.

A drain was inserted in the left upper quadrant and the incision was closed in layers. The patient tolerated the procedure well and was discharged home on postoperative day 7 without the drain. The patient was seen in clinic at 15 days (Figure 8) and 3 months and 6 months (Figure 9) post-surgery. His wound was healing well and there were no signs of recurrence.

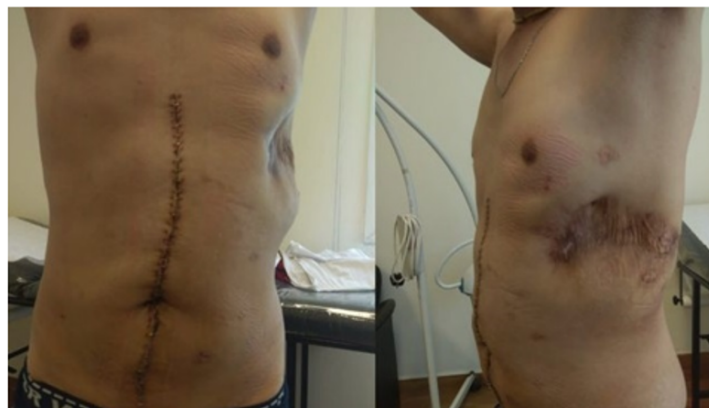

Figure 8: Patient at 15 days post-surgery.

Discussion

Intercostal hernias are rare entities, as such their classification has changed throughout the years. The current classification depends on the presence of a diaphragmatic hernia. Acquired abdominal intercostal hernias occur when viscera protrude directly through a weakness in the chest wall in presence of an intact diaphragm, while a transdiaphragmatic intercostal hernia is defined as either abdominal or thoracic viscera protruding through a defect in the diaphragm [2]. In this case we encountered two separate hernia defects. An AAIH with abdominal viscera protruding through an 8th and 9th ribs defect as well as TDIH with omentum protruding through a diaphragmatic defect, directing supero-laterally and sparing the pleural space. Both herniations were sited in the same subcutaneous cavity overlying the left lateral chest wall.

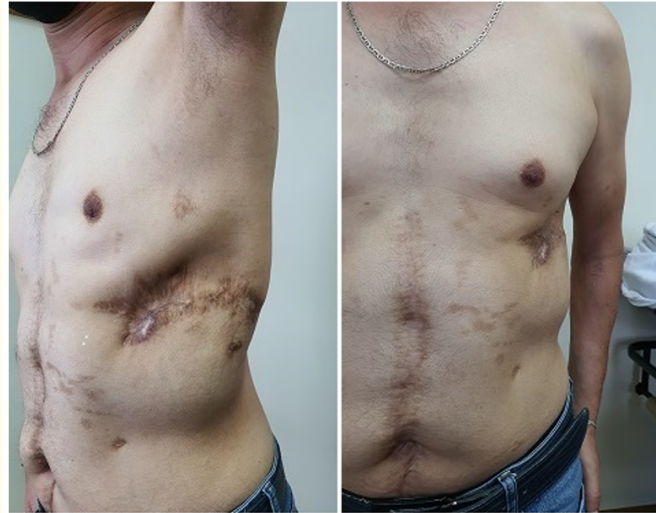

Figure 9: Patient at 6 months post-surgery.

There are 19 reported cases of AAIH in the literature [2], while Benizri., *et al.* states there are less than 40 cases of TDIH reported [3]. However, in a review of the world literature Sharma., *et al.* found only 11 reported cases of TDIH [4]. The causes of both types of intercostal hernias include blunt or penetrating trauma, bouts of violent coughing, and congenital diseases that cause weakness of the chest wall musculature such as Ehler-Danlos syndrome [1,5,6].

Clinical features of AAIH include a reducible swelling on the chest wall which can cause discomfort or pain, however most cases are asymptomatic [2]. Most cases of AAIH are not recognized immediately and only become clinically apparent after several months or years. Erdas., *et al.* reported a mean time between the inciting trauma if any and hospital admission for AAIH was 24.4 months with a range between same day and 20 years after trauma [2]. Patients with TDIH present with a reducible soft tissue mass in the chest wall that increases with the Valsalva maneuver [4,7]. TDIH is suspected when there is an increase in the size on inspiration and a decrease on expiration, while the opposite suggests a pulmonary intercostal hernia [4]. Like AAIH, patients with TDIH present with signs and symptoms of hernia at an average of 5 months with duration ranging between immediately after the trauma to 36 years after the initial insult [7]. Both AAIH and TDIH can be diagnosed via physical exam and clinical presentation, however chest x-rays and CT scans are often needed to confirm diagnosis and plan the surgical approach [2,7].

Most AAIH and TDIH should be repaired. As Erdas., *et al.* showed, 15% of AAIH can result in strangulation of hernia contents [2]. TDIH also have a high risk of strangulation [8]. Even if asymptomatic, repair of AAIH and TDIH may be done because of cosmetic distress to the patient [8]. For asymptomatic patients or elderly patients who are not surgical candidates, conservative management can be considered [8].

There are multiple surgical techniques to repair AAIH and TDIH. Both can be repaired via either direct or indirect approaches. A direct approach involves an incision directly above the hernia, while an indirect approach involves either an abdominal laparotomy, thoracotomy, or laparoscopy [2,8,9]. An abdominal approach with a laparotomy is preferred for acute trauma patients with suspected diaphragmatic injury that causes an intercostal hernia (TDIH) [8].

Because intercostal hernias are a rare entity there is no consensus on one type of surgical approach that is superior to the others. There is also ambiguity on whether reinforcement with a mesh should be undertaken in these types of hernias. Reports in the literature state

that the use of mesh should be routine when repairing these hernias as it can be extrapolated from the repair of other hernia types that the use of mesh will decrease the risk of recurrence [2,9].

Conclusion

Intercostal hernias are uncommon and usually result from trauma to the chest wall. It is important to be familiar with this condition as the diagnosis and management of patients with intercostal hernias may be challenging. There are no reported cases of concomitant AAIH and TDIH in the literature making this case out of the ordinary.

Bibliography

1. Abunnaja S., *et al.* "Acquired Abdominal Intercostal Hernia: A Case Report and Literature Review". *Case Reports in Surgery* (2014): 1-5.
2. Erdas E., *et al.* "Acquired abdominal intercostal hernia: case report and systematic review of the literature". *Hernia* 18.5 (2014): 607-615.
3. Benizri E., *et al.* "Post-traumatic transdiaphragmatic intercostal hernia: report of two cases". *Surgery Today* 43.1 (2012): 96-99.
4. Sharma O and Duffy B. "Transdiaphragmatic Intercostal Hernia: Review of the World Literature". *Journal of Trauma and Acute Care Surgery* 51.6 (2001): 1219.
5. Rogers F., *et al.* "Traumatic Transdiaphragmatic Intercostal Hernia Secondary to Coughing". *The Journal of Trauma: Injury, Infection, and Critical Care* 41.5 (1996): 902-903.
6. De Weerd L., *et al.* "A large abdominal intercostal hernia in a patient with vascular type Ehlers-Danlos syndrome: a surgical challenge". *Hernia* 16.1 (2010): 117-120.
7. Biswas S and Keddington J. "Soft right chest wall swelling simulating lipoma following motor vehicle accident: transdiaphragmatic intercostal hernia. A case report and review of literature". *Hernia* 12.5 (2008): 539-543.
8. Kalles V., *et al.* "Posttraumatic Transdiaphragmatic Intercostal Hernia: Report of a Case and Review of the Literature". *International Surgery* 100.3 (2015): 444-449.
9. Dan D., *et al.* "Laparoscopic repair of a rare acquired abdominal intercostal hernia". *International Journal of Surgery Case Reports* 5.12 (2014): 1041-1043.

Volume 8 Issue 2 February 2021

©All rights reserved by Ayman Obeid., *et al.*