

TaTME and Laparoscopic Restorative Proctocolectomy with Ileal Pouch Anal Anastomosis in a Patient with Familial Adenomatous Polyposis and Synchronous Colorectal Cancer. Case Report

Juan Manuel Sotelo*, Romina Di Vietro, Javier Oviedo and Rodrigo Moran Azzi

Colorectal Surgery Division, Sanatorio Güemes of Buenos Aires, C.A.B.A, Buenos Aires, Argentina

***Corresponding Author:** Juan Manuel Sotelo, Colorectal Surgery Division, Sanatorio Güemes of Buenos Aires, C.A.B.A, Buenos Aires, Argentina.

Received: September 25, 2020; **Published:** November 28, 2020

Abstract

Introduction: Familial adenomatous polyposis (FAP) is a hereditary autosomal dominant syndrome characterized by the development of hundreds to thousands of adenomatous polyps in the colon and rectum during the second decade of life. Due to complete penetrance and the large number of adenomas, the risk of malignancy is almost 100%, hence the importance of the diagnosis and prophylactic surgical treatment at the right time.

Presentation of Case: A 42 years old patient with FAP diagnosis arrived to the emergency department with lower gastrointestinal hemorrhage that required a red blood cells transfusion. A standard colonoscopy and virtual colonoscopy were performed and three synchronous colorectal tumors were diagnosed. A laparoscopic restorative proctocolectomy with ileal pouch anal anastomosis (IPAA) using transanal total mesorectal excision was performed. After 8 weeks the loop ileostomy reversal was performed. Currently the patient reports good quality of life.

Discussion: Nowadays the laparoscopic surgery is considered the best option, due to presenting similar results as open surgery, maintaining the benefits of the mini-invasive approach. At the same time the development of the laparoscopic transanal total mesorectum excision (TaTME), adds a new tool for special cases.

Conclusion: We consider that due to the low prevalence of FAP and the complexity of its treatment, the experience of the surgeon plays a very important role. TaTME with a previous intersphincteric dissection is a safe and effective procedure in experienced hands.

Keywords: *Familial Adenomatous Polyposis; Colorectal Cancer; Laparoscopic Colorectal Surgery; TaTME*

Introduction

Familial adenomatous polyposis (FAP) is a hereditary autosomal dominant syndrome, caused by a mutation in the APC gene, which mainly affects people with a family history of the disease. However, up to 25 - 30% may develop the mutation “*de novo*” [1].

It is characterized by the development of hundreds to thousands adenomatous polyps in the colon and rectum in the early stages of life, usually appearing at puberty. While most patients are asymptomatic, in children under 20 years old, the usual clinical presentation is hematochezia associated with diarrhea [2,3].

There is a less aggressive variant, the attenuated familial adenomatous polyposis (AFAP), that is characterized by the presence of 10 to 100 adenomatous polyps, late development of adenomas, and a lower risk of cancer [1].

Approximately 70% of diagnoses are made by colonoscopy and 25% by genetic screening. Less than 5% are diagnosed by extraintestinal manifestations [2], such as gastroduodenal polyps (which may progress to adenocarcinoma) and desmoid tumors, both present difficult management and high mortality [4,5].

As it is a hereditary condition, with complete penetrance, this patients should be treated with a prophylactic surgery, otherwise almost 100% of patients will develop colorectal cancer between the age of 40 to 50 years old [1-3].

There are different surgical options and techniques, depending on the patient's condition, age, gender, type of polyposis, comorbidities, sphincter function, extra intestinal manifestations or the presence of colorectal cancer [1,6].

There is a lot of available evidence that has shown that in colorectal cancer, laparoscopic surgery presents similar morbidity, mortality and oncological outcomes as open surgery, keeping the benefits of the mini-invasive approach [7].

Aim of the Study

The aim of this paper is to present a case of FAP in a patient with a synchronous colorectal cancer, treated by transabdominal and transanal laparoscopic approach.

Case Presentation

A 41-year-old man with familial adenomatous polyposis diagnosed 9 years ago, but he refused to receive surgical treatment at the time for personal reasons. He did not know the family history of the disease.

He was admitted to the emergency department presenting low gastrointestinal bleeding, with a hemoglobin (hb) of 5.8 g/dl, requiring red blood cells transfusion.

The patient reported significant weight loss and a history of long time diarrhea.

A colonoscopy was performed, identifying a large tumor at 15 centimeters from the anal margin and multiple rectal polyps. Biopsies informed tubular adenomas with high grade dysplasia. The upper endoscopy was normal.

We decided to perform virtual colonoscopy to complete the colonic study, finding a synchronic lesion in the right colon. Systemic staging was completed without evidence of metastatic disease.

Due to poor nutritional status with albumin of 2.2 g/dl and total proteins of 4.2 g/dl, he received complementary parenteral nutrition (PN).

Surgery was decided. Mechanical bowel preparation was given along with oral antibiotics (metronidazole and neomycin) the day before surgery.

Patient was placed in a modified Lloyd Davies position following general anesthesia. The procedure started with the abdominal part using five trocars. Complete colonic mobilization was performed and total mesorectal excision was continued, just as the transanal approach was beginning. An anal retractor was placed to achieve adequate view of the dentate line and just above it, the mucosa was replaced by polyps. Due to this finding, we decided to start with an intersphincteric dissection. Then we placed the transanal platform and advanced the dissection towards to cephalic, communicating both dissections. The complete surgical specimen was retrieved by transanal route (Figure 1). The standard stapled ileal J pouch was made (Figure 2) and handswen ileoanal anastomosis was performed. Drainage was placed in the pelvic and Brooke style ileostomy was performed (Figure 3). The total duration of the surgical procedure was approximately 280 minutes.

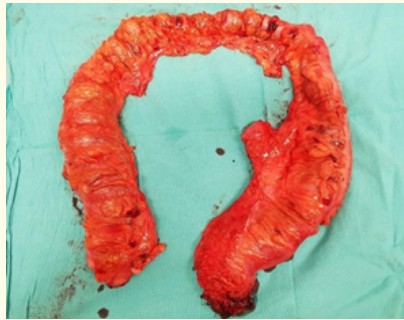

Figure 1: Total proctocolectomy specimen.

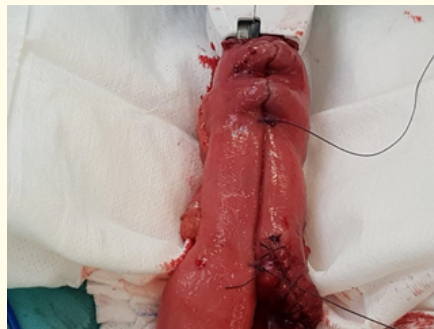


Figure 2: Standard stapled ileal J pouch.

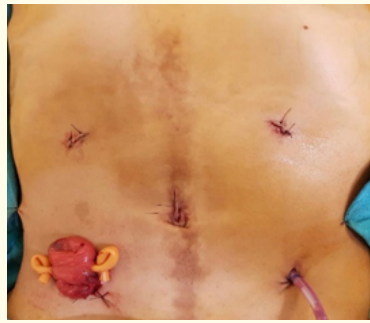


Figure 3: Brooke style ileostomy and pelvic drain externalized by trocar orifices.

The immediate postoperative period (POP) was carried out in the intensive care unit, starting with oral intake in the first 4 hours with good tolerance, and restarted PN. On the third day, the patient presented with functional ileus, so oral intake was suspended and a nasogastric tube was placed. On day five oral intake was resumed with good tolerance. The patient remained hospitalized until completing 21 days of PN, in order to improve his nutritional status. His discharge albumin was 3.8 g/dl and total proteins was 7.1 g/dl.

The histopathology reported more than 100 polyps covering the colon and rectum and three synchronous adenocarcinomas, in the cecum, rectosigmoid junction and mid rectum. Ninety-three lymph nodes were isolated and four had metastatic disease. Stage pT3 pN2a (Figure 4 and 5).

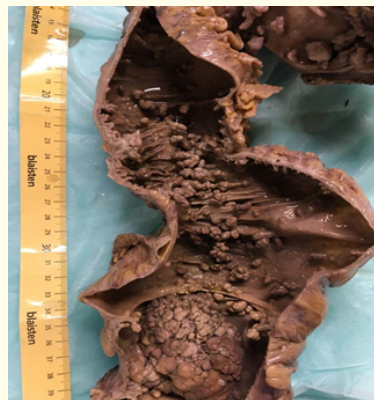

Figure 4: Specimen fixed with formalin. Multiple isolated and confluent polyps with normal mucosa areas.

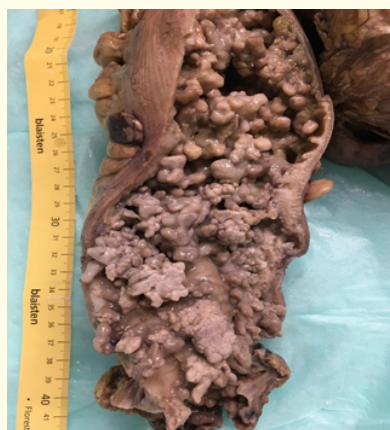

Figure 5: Specimen fixed with formalin. Large confluent polyps that completely replace normal mucosa.

The patient refused the adjuvant chemotherapy treatment.

Two months later, after rectoscopy and contrasting study of the pouch, ileostomy was closed and the patient was discharged in 48 hours.

Currently, the patient reports good quality of life, with 4 to 6 bowel movements per day and no pouch complications.

Discussion and Conclusion

The hereditary characteristic of FAP makes family genetic counseling and endoscopic study very important, in order to diagnose the disease early, offer appropriate surgical treatment, according to the patient's characteristics and avoid the development of colorectal cancer [1,6].

In this case, the patient did not know about the existence of a family history and even though he had been diagnosed endoscopically 9 years ago, surgery was refused and no follow up was done. Due to the progression of the disease, he developed an acute lower gastrointestinal bleeding that required his hospitalization and study, diagnosing synchronous colorectal neoplasia.

After diagnosis, the management of patients with FAP is a real challenge, even for the most experienced surgeons. It is important to put special emphasis on how surgical treatment could influence the quality of life of these patients. Options include total colectomy with end ileostomy or ileorectal anastomosis, total proctocolectomy with end ileostomy and restorative proctocolectomy with or without mucosectomy and ileal pouch with ileoanal anastomosis (IPAA) [1,6].

Despite being complex procedures, with a longer surgical time and a higher learning curve, laparoscopy has shown comparable results to open surgery in terms of morbidity and mortality, as well as in oncological and functional outcomes, with lower bleeding rates, faster recovery, shorter hospital stays and less surgical site infection [7-10].

As these are young and fertile patients, series such as those of Panis, *et al.* and Bemelman, *et al.* have shown lower infertility and higher pregnancy rate in favor to laparoscopic approach [11,12].

Currently, transanal total mesorectal excision (TaTME) is a promising technique for rectal cancer treatment. It is under evaluation and the results from prospective randomized studies, such as COLOR III, are expected to analyze safety of the technique and long term oncological outcomes [13,14].

The Ambe, *et al.* series evaluated 8 patients who underwent prophylactic laparoscopic restorative proctocolectomy with IPAA using TaTME, concluding that it is a safe and effective option [15].

According to the available evidence and the good surgical results obtained, since this is a case of FAP with a large number of polyps in the rectum near the anal margin, without extraintestinal manifestation and with 3 synchronous tumors, one of them in the middle rectum, we consider that the technique and approach used were adequate.

Conflict of Interests

No conflicts of interest.

Bibliography

1. Campos FG. "Surgical treatment of familial adenomatous polyposis: Dilemmas and current recommendations". *World Journal of Gastroenterology* 20 (2014): 16620-16609.
2. Kennedy RD, *et al.* "The natural history of familial adenomatous polyposis syndrome: A 24 year review of a single center experience in screening, diagnosis, and outcomes". *Journal of Pediatric Surgery* 49 (2014): 82-86.
3. Oviedo RJ, *et al.* "CASE REPORT - OPEN ACCESS International Journal of Surgery Case Reports Emergency total proctocolectomy in an uninsured patient with Familial Adenomatous Polyposis Syndrome and acute lower gastrointestinal hemorrhage in a community hospital: A case report". *International Journal of Surgery Case Reports* 26 (2017): 166-169.
4. Walter T, *et al.* "Management of desmoid tumours: A large national database of familial adenomatous patients shows a link to colectomy modalities and low efficacy of medical treatments". *United European Gastroenterology Journal* 5.5 (2017): 735-741.
5. Campos FG, *et al.* "Advanced duodenal neoplasia and carcinoma in familial adenomatous polyposis: outcomes of surgical management". *The Journal of Gastrointestinal Oncology* 8 (2017): 877-884.
6. Chittleborough TJ, *et al.* "Dispelling misconceptions in the management of familial adenomatous polyposis". *ANZ Journal of Surgery* 87 (2017): 441-445.
7. Sun J and Xing S. "Short-term outcome of laparoscopic surgery versus open surgery on colon carcinoma: A meta-analysis 16 (2019): 4645-4659.
8. Larson DW, *et al.* "Laparoscopic-Assisted vs. Open Ileal Pouch-Anal Anastomosis: Functional Outcome in a Case-Matched Series". *Diseases of the Colon and Rectum* 48.10 (2005): 1845-1850.
9. Vitellaro M, *et al.* "Short-term and long-term outcomes after preventive surgery in adolescent patients with familial adenomatous polyposis". *Pediatric Blood and Cancer* 67 (2020): 1-6.
10. Bemelman WA, *et al.* "A Randomized Trial of Laparoscopic versus Open Surgery for Rectal Cancer". *The New England Journal of Medicine* (2015).
11. Beyer-Berjot L, *et al.* "A total laparoscopic approach reduces the infertility rate after ileal pouch-anal anastomosis: A 2-center study". *Annals of Surgery* 258 (2013): 275-282.
12. Bartels SAL, *et al.* "Significantly increased pregnancy rates after laparoscopic restorative proctocolectomy: A cross-sectional study". *Annals of Surgery* 256 (2012): 1045-1048.
13. Tsai CLDA and Veltcamp TWAKM. "Clinical outcomes and case volume effect of transanal total mesorectal excision for rectal cancer: a systematic review". *Techniques in Coloproctology* 20 (2016): 811-824.

14. Deijen CL, *et al.* "COLOR III: a multicentre randomised clinical trial comparing transanal TME versus laparoscopic TME for mid and low rectal cancer". *Surgical Endoscopy* 30 (2016): 3210-3215.
15. Ambe PC and Möslein HZG. "Initial experience with ta TME in patients undergoing laparoscopic restorative proctocolectomy for familial adenomatous polyposis". *Techniques in Coloproctology* (2017): 3-6.

Volume 7 Issue 12 December 2020

©All rights reserved by Juan Manuel Sotelo, *et al.*