

Clinical Management of Malignancy-Related Ascites

Mohammad-Salar Hosseini^{1,2*}

¹*Student Research Committee, Faculty of Medicine, Tabriz University of Medical Sciences, Tabriz, Iran*

²*Research Center for Evidence-Based Medicine, Tabriz University of Medical Sciences, Tabriz, Iran*

***Corresponding Author:** Mohammad-Salar Hosseini, Student Research Committee, Faculty of Medicine, Tabriz University of Medical Sciences, Tabriz, Iran.

Received: October 15, 2020; **Published:** October 22, 2020

Abstract

Malignancy-related ascites, also known as malignant ascites, is the accumulation of fluids in the peritoneal cavity due to malignancy. Since the management of malignancy-related ascites is a challenge, and the knowledge around this subject is narrow among the clinicians, we aim to provide a practically useful algorithm for clinical approach and management of this medical issue.

Keywords: Ascites; Chylous Ascites; Malignant Ascites; Peritoneal Neoplasms; Peritoneovenous Shunt

The accumulation of fluids in the peritoneal cavity, known as ascites, is generally an accompanying symptom of portal hypertension and cirrhosis. However, a considerable number of patients develop ascites due to malignancies. The malignancy-related ascites, also clinically known as malignant ascites, is typically observed in the patients with malignancies of breast, lung, colon, ovary, pancreas, liver, and lymphoma. The patients are usually diagnosed after the compression of the nerves due to the expansion of the tumor; stretch of the abdominal wall due to the increase in intraperitoneal pressure, and stretch of the liver capsule as a result of the tumor grow or inflammation of the liver, presenting with symptoms like increase in abdominal circumference, anorexia, weight loss, and most importantly, abdominal pain [1].

Diagnosis is based on the clinical manifestations, followed by diagnostic paracentesis and ascitic fluid analysis, evaluation of serum albumin, and imaging [1,2]. Peritoneal fluid culture, ascitic glucose and triglyceride, differential cell count, and cytology tests are performed as well. The fluid from the paracentesis is used to perform an ascitic fluid analysis, but beforehand, the general appearance of the fluid could reveal some information. An uninfected ascitic fluid is clear, whereas the ascitic fluid in a patient with peritoneal carcinomatosis may be turbid due to the presence of the cells. A milky fluid usually indicates a high level of triglyceride, which is suggestive of chylous ascites.

Generally, depending on the serum-ascites albumin gradient (SAAG = (serum albumin) - (albumin level in the ascitic fluid)), the ascites are classified to high SAAG (≥ 1.1 g/dL) or low SAAG (< 1.1 g/dL). Malignancy-related ascites could be high SAAG or low SAAG regarding the underlying cause. For instance, a high SAAG usually represents portal hypertension, while a low SAAG rules it out [3]. An overview of the clinical approach to the malignancy-related ascites is illustrated in figure 1. Low SAAG ascites are typically observed in peritoneal carcinomatosis and malignancy-related chylous ascites, where positive cytology suggests the peritoneal carcinomatosis and high triglyceride levels in ascitic fluid (usually over 200 mg/dL) are suggestive of chylous ascites [4]. The high SAAG ascites could be a consequence of massive liver metastases, hepatocellular carcinoma (HCC), or malignancy-related Budd-Chiari syndrome. Further approach to high SAAG

ascites is more based on the patient’s medical history, imaging findings, and invasive methods. Although the total ascitic fluid protein is less than 2.5 g/dL in these patients, in patients with early Budd-Chiari syndrome, the ascitic fluid protein is more than 2.5 g/dL. Therefore, different values of ascitic fluid protein may be observed in patients with Budd-Chiari syndrome. Even though the tumor markers, such as Alpha-fetoprotein, CEA, CA-125, and CA 19-9, have low specificity in the diagnosis of malignancies, they could help to identify the primary site of the tumor [5]. The imaging usually contains an abdominal ultrasound. For further evaluation, a computed tomography or magnetic resonance imaging could be performed as well.

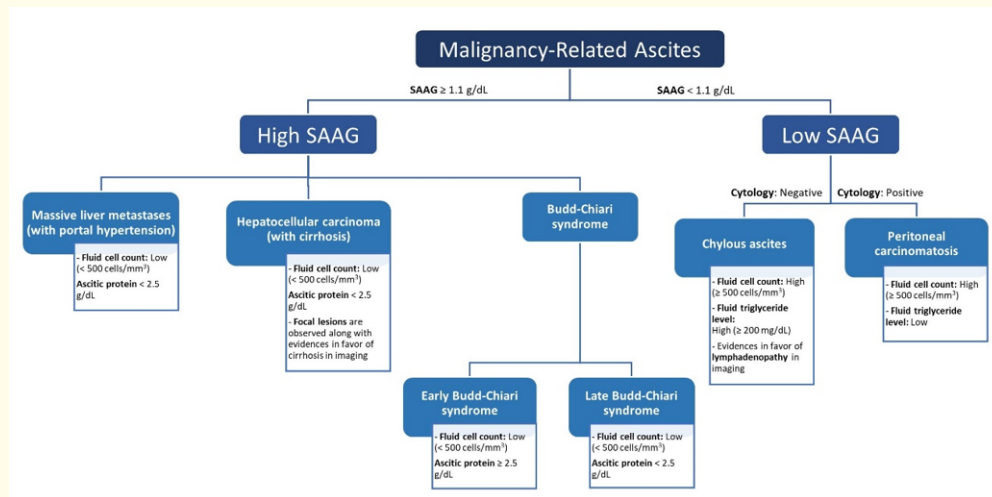


Figure 1: The clinical approach to the malignancy-related ascites, the differential diagnoses, and the specific characteristics. *SAAG: Serum-Ascites Albumin Gradient.

Since the lymphatics are obstructed, and the circulating blood volume is reduced, the renin-angiotensin-aldosterone system is triggered, which leads the body to sodium retention. Therefore, the general approach to the treatment of ascites contains two principle steps: retention of sodium intake to less than 500 to 5000 mg/d (the optimal target of less than 2000 mg/d) and prescribing diuretics [6]. However, the general management of ascites is not effective in the case of malignancy-related ascites. Malignancy-related ascites are usually managed by serial paracentesis and transcutaneous drainage. The persistent cases are also managed with peritoneovenous shunts. As paracentesis rapidly relieves the patients’ symptoms, it should be considered at the first-line of treatment. Meanwhile, it should be considered that serial large-volume paracentesis (LVP) without an appropriate fluid replacement could result in hypotension and renal failure [2]. The risk of secondary peritonitis should be considered either [1]. Diuretics are also considered among the treatment options, but they are reported to have less efficacy in malignancy-related ascites, especially in patients with peritoneal carcinomatosis [7]. The unresponsive cases could benefit from peritoneovenous shunts. There are different types peritoneovenous shunts available, including the LeVein, the Hyde, and the Denver where the LeVein and the Denver are more regularly used [7]. The peritoneovenous shunt drains the ascitic fluid from the peritoneum into the superior vena cava (SVC). Some novel treatment methods have been suggested in the treatment of malignant ascites, including monoclonal antibody therapy and immunotherapy with intraperitoneal interferons, some of which have shown promising results but none of them are clinically available yet [8]. Most of the mentioned treatments are in favor of palliative care and symptomatic management of malignancy-related ascites, resulting in fewer symptoms and improved conditions. Treating the underlying malignancy, is the main treatment of the malignancy-related ascites.

Since the patients with malignancy-related ascites usually have a poor prognosis, an early and accurate diagnosis is essential. Therefore, a rapid determination of the underlying cause and defining an appropriate patient-centered therapy is mandatory.

Bibliography

1. Runyon BA, *et al.* "Malignancy-related ascites" (2017).
2. Hodge C and Badgwell BD. "Palliation of malignant ascites". *Journal of Surgical Oncology* 120.1 (2019): 67-73.
3. Bindu C and Nayak U. "Clinical study of ascites with special reference to serum-ascites albumin gradient". *International Journal of Medical Science and Public Health* 3.2 (2014): 169-173.
4. Bhardwaj R, *et al.* "Chylous ascites: a review of pathogenesis, diagnosis and treatment". *Journal of Clinical and Translational Hepatology* 6.1 (2018): 105.
5. Sangisetty SL and Miner TJ. "Malignant ascites: a review of prognostic factors, pathophysiology and therapeutic measures". *World Journal of Gastrointestinal Surgery* 4.4 (2012): 87.
6. Baki J, *et al.* "Do Nutritional Interventions Improve the Outcomes of Patients with Cirrhosis and Ascites: a Systematic Review of Randomized Trials". *Current Hepatology Reports* 19.2 (2020): 71-77.
7. Becker G, *et al.* "Malignant ascites: systematic review and guideline for treatment". *European Journal of Cancer* 42.5 (2006): 589-597.
8. Iwamura T, *et al.* "Novel pegylated interferon- β as strong suppressor of the malignant ascites in a peritoneal metastasis model of human cancer". *Cancer Science* 108.4 (2017): 581-589.

Volume 7 Issue 11 November 2020

© All rights reserved by Mohammad-Salar Hosseini.