

## Every Radiologically Diagnosed Hemangioma is Not benign: Reporting a Case of Malignant Mesenchymoma

**Sutariya Vaibhavkumar K\***

*Professor, Department of Gastrointestinal Surgery and Liver Transplantation, Smt. G. R. Doshi and Smt. K. M. Mehta Institute of Kidney Diseases and Research Centre and Dr. H. L. Trivedi Institute of Transplantation Sciences, Civil Hospital Campus, Asarwa, Ahmedabad, Gujarat, India*

**\*Corresponding Author:** Sutariya Vaibhavkumar K, Professor, Department of Gastrointestinal Surgery and Liver Transplantation, Smt. G. R. Doshi and Smt. K. M. Mehta Institute of Kidney Diseases and Research Centre and Dr. H. L. Trivedi Institute of Transplantation Sciences, Civil Hospital Campus, Asarwa, Ahmedabad, Gujarat, India.

**Received:** September 12, 2020; **Published:** October 22, 2020

### Abstract

Malignant mesenchymoma, known as undifferentiated embryonal sarcoma of liver (UESL), is a rare tumor being diagnosed in older children and infrequently in young adults. This tumor is having dismal prognosis if not diagnosed and treated in time. Malignant mesenchymoma, also known as undifferentiated embryonal sarcoma of liver, is many times difficult to differentiate from other benign hepatic liver lesions. Here, we report a case of malignant mesenchymoma presenting in a twenty five year old male patient.

**Keywords:** Malignant Mesenchymoma; Undifferentiated Embryonal Sarcoma (UES); Hemangioma

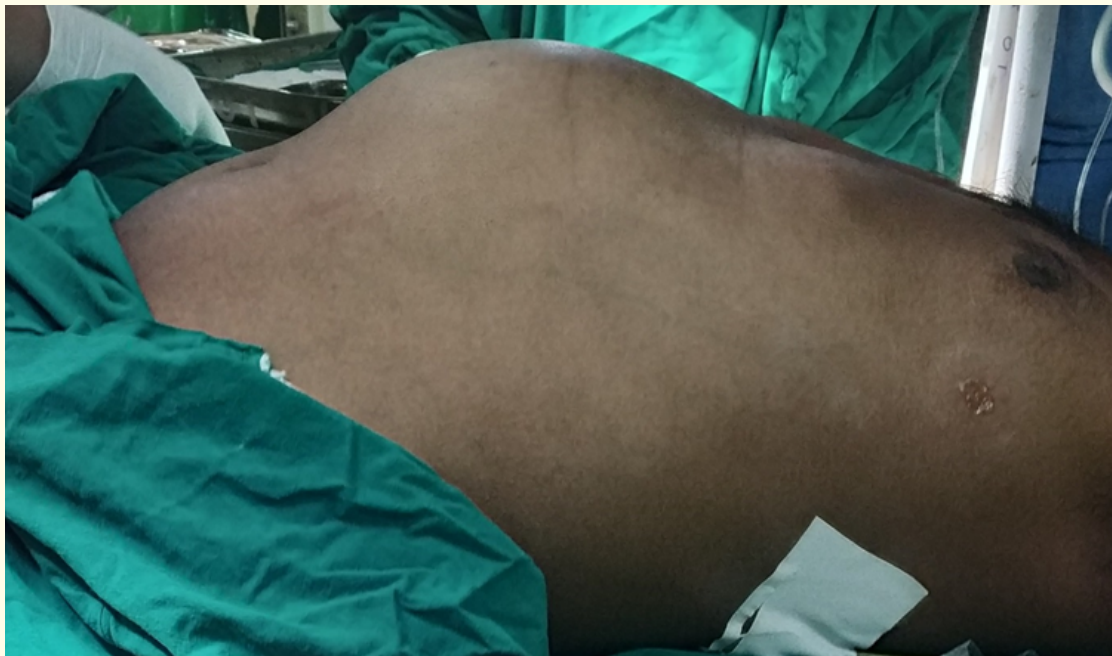
### Introduction

Malignant mesenchymoma of liver is an extremely rare tumor being diagnosed mostly in children aged between 6 to 10 years of age but infrequently in adults. Mesenchymoma was first described in 1946 and renamed as malignant mesenchymoma by Stout. It has been recognized as a special clinical entity by Stocker and Ishak in 1978 [1]. Malignant mesenchymoma is also known as undifferentiated embryonal sarcoma of liver (UESL). Approximate incidence of such clinical entity is 0.2% of all primary liver tumor [2]. Malignant mesenchymoma presents with non-specific symptoms and is very difficult to differentiate from other space occupying lesions of liver. Here, we present a case of malignant mesenchymoma which has been misdiagnosed as hemangioma.

### Case Report

A 25 year old male presented with severe upper abdominal pain and nausea for 15 days. On examination, patient was found to have lump in upper abdomen with firm consistency and smooth margins. Except for abdominal discomfort occurring in between, patient's past history was not significant. Patient's laboratory parameters were: hemoglobin- 10.1 gm/dl, white blood cell count- 8930/cmm, Total serum bilirubin- 0.6 mg/dl, direct bilirubin- 0.3 mg/dl and indirect bilirubin- 0.3 mg/dl, Alanine aminotransferase- 30 U/L, Aspartate amino transferase- 31U/L, Serum alkaline phosphatase- 73 U/L, Total serum proteins- 6.1 gm/dl, albumin- 3.2 gm/dl, globulin- 2.9 gm/

dl, International normalized ratio for prothrombin time- 1.36, random blood sugar- 142 mg/dl, serum creatinine- 1.2 mg/dl. Alpha fetoprotein level, carbohydrate antigen 19-9 level, and carcinoembryonic antigen level were within normal limits. Ultrasonography of abdomen revealed heterogeneous echotexture lesion of 15.5 cm X 14 cm X 16.5 cm in right lobe of liver with internal vascularity suggestive of atypical hemangioma. Computed tomography scan was suggestive of similar size lesion suggestive of hemangioma. Magnetic resonance imaging of abdomen shows 15 cm X 17 cm X 17 cm size round to oval mass with well-defined margins and partial exophytic component. It appears hyper intense on T2, hypointense on T1 with no evidence of restriction. On post contrast scan, it showed progressive discontinuous peripheral centripetal nodular contrast enhancement. It did not show evidence of washout of contrast on delayed phase. Patient was diagnosed to have giant atypical hemangioma. Patient was subjected to enucleation of hemangioma. Operation was uneventful and patient was discharged after 7 days of surgery. Histopathology report revealed 3.5 kilogram oval tumor measuring 24 cm X 16 cm X 15 cm in size with smooth outer surface. On cut section multiple cysts filled with blood clots and solid areas measuring 13 cm X 8 cm found. Microscopic examination showed spindle to round cells with marked pleomorphic malignant giant cells. Areas of hemorrhage and necrosis were evident. Capsule is free of tumor. On immunohistochemistry staining, vimentin was positive and desmin was focally positive. Patient was identified to have malignant mesenchymoma. Patient has been subjected to doxorubicin, vincristine, and ifosfamide based chemotherapy. Patient has expired 12 months after surgery.



**Figure 1:** Presentation with lump in abdomen.

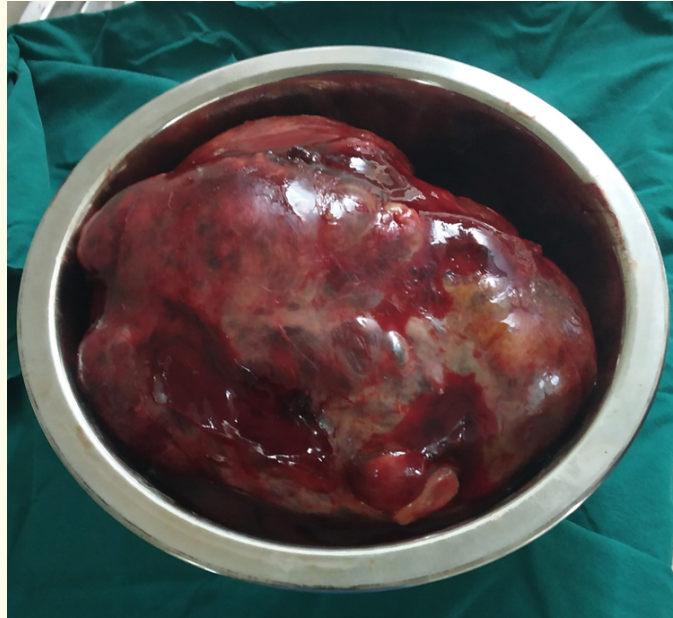


Figure 2: 3.5 kilogram oval tumor.

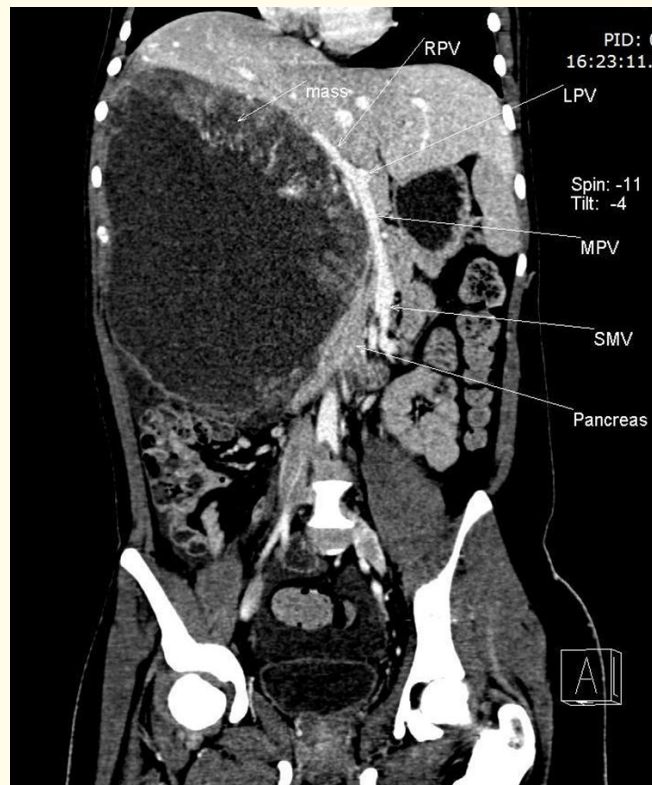
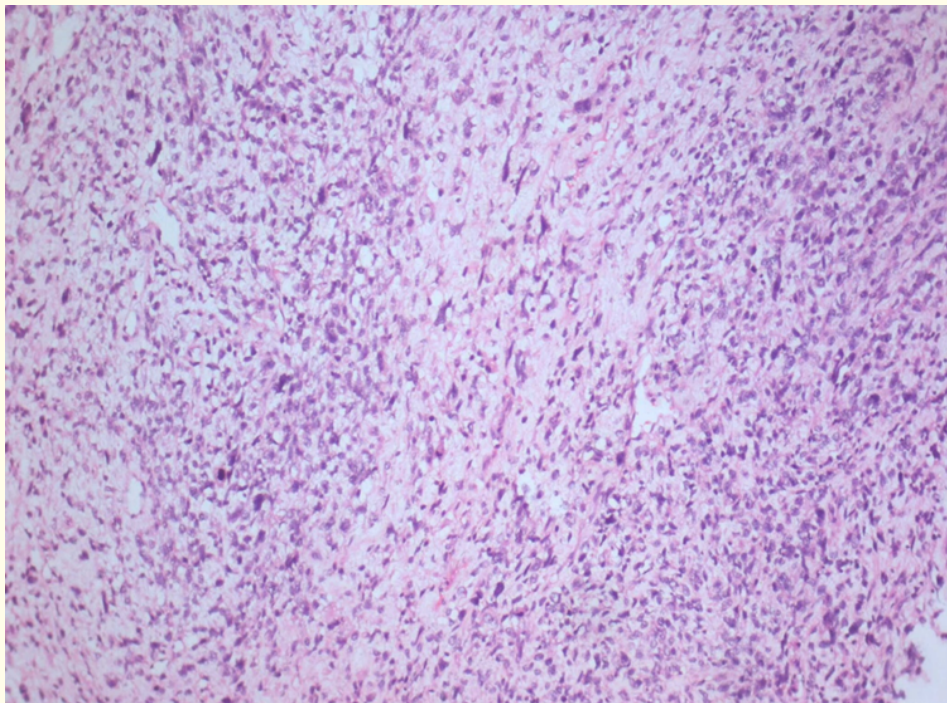
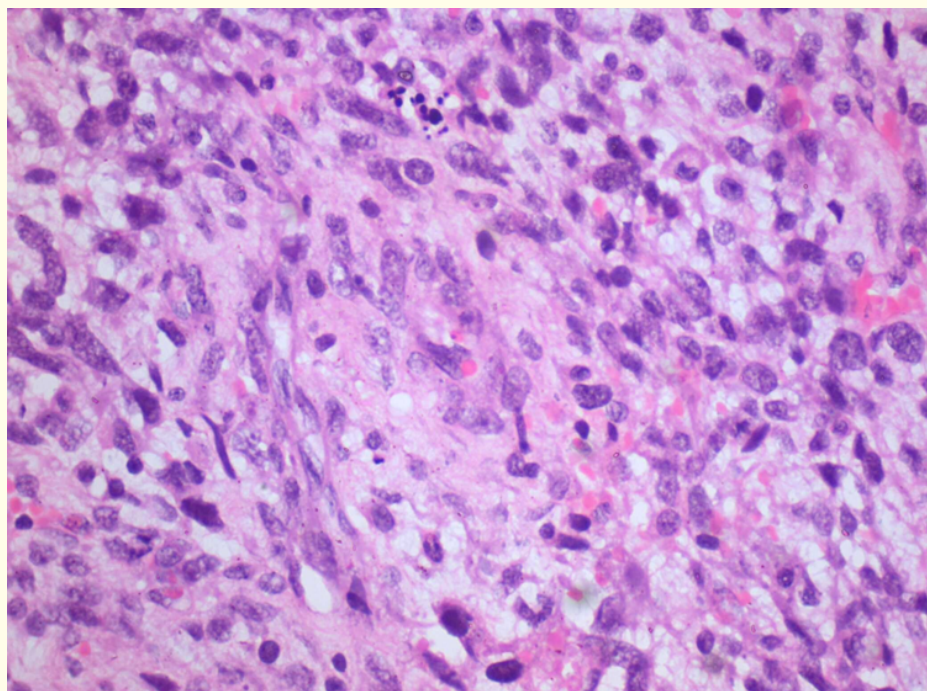


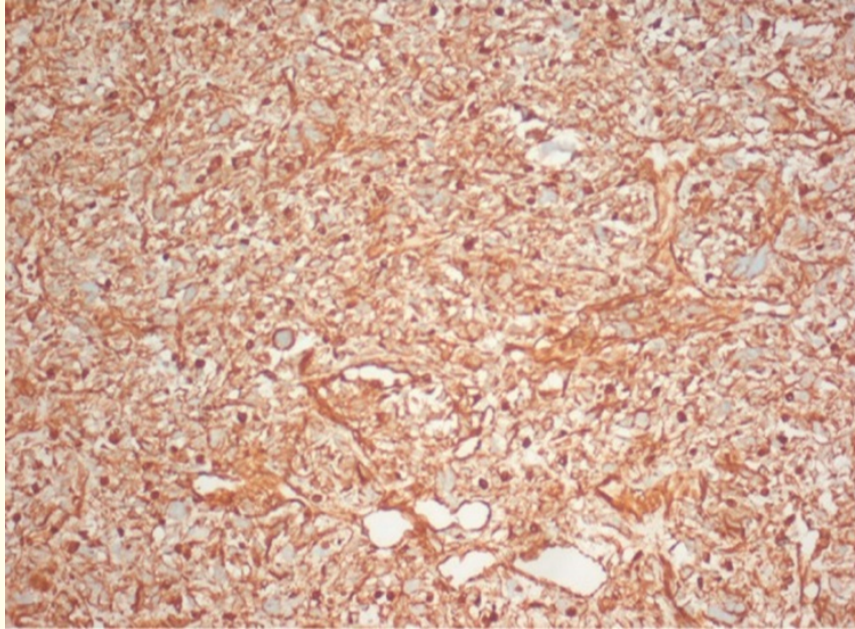
Figure 3: CECT scan image of tumor.



**Figure 4:** Tumor cells with necrotic areas, H&E stain x 100.



**Figure 5:** Tumor comprising spindle cells, H&E stain x 100.



**Figure 6:** Tumor cells diffusely positive for vimentin, IHC x 100.

## Discussion

Malignant mesenchymoma is a very rare hepatic tumor usually occurring in children aged between 6 to 10 years of age, presenting in adults extremely infrequently. Primary mesenchymal tumors of liver are very rare as compared to carcinoma arising from hepatocytes or cholangiocytes. Very few cases of malignant mesenchymoma have been reported in adult patients with slight preference to females.

Patients with malignant mesenchymoma have nonspecific symptoms like abdominal mass, abdominal pain, and vomiting. Occasionally spontaneous rupture of tumor may result in intraperitoneal hemorrhage due to rapid growth of tumor [4]. Unlike hepatocellular carcinoma and cholangiocarcinoma, there is no hepatitis, cirrhosis, disturbance of hepatic function, or elevation of tumor markers. Out of all reported patients, only 9.8% of patients have raised alpha fetoprotein level and only 1.9% have raised CA 125 level. One case of erythropoietin secreting malignant mesenchymoma has been reported [5]. Thus, preoperative diagnosis is based on ultrasonography and computed tomography scan only. Tumor appears as a solid mass on ultrasonography. Computed tomography demonstrates it as a large mass solid or cystic. Misleading cyst like appearance on CT scan as compared to ultrasonography is useful in preoperative diagnosis. The cytological features of tumor on fine needle aspiration along with radiological and other clinical relevant findings may help in diagnosing this rare clinical entity [6-8]. In our case, it was not possible to do fine needle aspiration in view of hemangioma like appearance of the lesion on CT scan as well as MRI. Thus, we have subjected patient to enucleation. High index of doubt is to be kept in older children and young adults with large cystic space occupying lesion of liver. Microscopic examination of tumor shows undifferentiated spindle cells,

inconspicuous nucleoli, hyperchromatic nuclei, and eosinophilic cytoplasm surrounded by myxoid matrix. Immunohistochemically, it may express histiocytic, muscular or epithelial markers commonly vimentin and alpha 1 antitrypsin suggesting origin from primitive stem cell [9,10]. As in our case, malignant mesenchymoma has been misdiagnosed as liver abscess, hydatid cyst and primary liver cancer [11].

Tumor behaves as a highly aggressive neoplasm; in the past, median survival was < 1 year following diagnosis. In recent times, early diagnosis, upfront resection, adjuvant chemotherapy, and multiagent chemotherapy has improved long term survival rate. Chemotherapy is based on vincristine, actinomycin, ifosfamide, and doxorubicin. Current one year and two year survival in patients with malignant mesenchymoma is 61% and 55% respectively, with a median survival of 29 months. However, recurrence is reported in 32% of patients completely treated by resection and adjuvant chemotherapy [12].

### Conclusion

To conclude, early diagnosis, upfront surgery, and adjuvant chemotherapy are the main stay of management of malignant mesenchymoma.

### Bibliography

1. Stocker JT and Ishak KG. "Undifferentiated (embryonal) sarcoma of the liver: report of 31 cases". *Cancer* 42 (1978): 336-348.
2. Liver Cancer Study Group of Japan. "Primary liver cancer in Japan. Clinicopathologic features and results of surgical treatment". *Annals of Surgery* 211 (1990): 277-287.
3. Sakellariadis T, et al. "Undifferentiated embryonal sarcoma of the liver mimicking acute appendicitis. Case report and review of the literature". *World Journal of Surgical Oncology* 4 (2006): 9.
4. Lin JM, et al. "Undifferentiated sarcoma of the liver: a case study of an erythropoietin-secreting tumor". *International Journal of Surgical Pathology* 22 (2014): 555-558.
5. Kaur J, et al. "Fine needle aspiration cytology of undifferentiated (embryonal) sarcoma of liver in an adult male". *Diagnostic Cytopathology* 38 (2010): 547-548.
6. Faraj W, et al. "Primary undifferentiated embryonal sarcoma of the liver mistaken for hydatid disease". *World Journal of Surgical Oncology* 8 (2010): 58.
7. Kalra N, et al. "Undifferentiated embryonal sarcoma of liver in an adult masquerading as complicated hydatid cyst". *Annals of Hepatology* 10 (2011): 81-83.
8. Lee KH, et al. "Undifferentiated embryonal sarcoma of the liver in an adult patient". *Clinical and Molecular Hepatology* 22 (2016): 292-295.
9. Kiani B, et al. "Immunohistochemical analysis of embryonal sarcoma of the liver". *Applied Immunohistochemistry and Molecular Morphology* 14 (2006): 193-197.

10. Bisogno G., *et al.* "Undifferentiated sarcoma of the liver in childhood: a curable disease". *Cancer* 94 (2002): 252-257.
11. Yanzhuo Li., *et al.* "Pre-operatively misdiagnosed undifferentiated embryonal sarcoma of the liver: analysis of 16 cases". *Annals of Translational Medicine* 22 (2015): 353.
12. Lenze F., *et al.* "Undifferentiated embryonal sarcoma of the liver in adults". *Cancer* 112 (2008): 2274-2282.

**Volume 7 Issue 11 November 2020**

**©All rights reserved by Sutariya Vaibhavkumar K.**