

Common Symptom : Rare Cause

Ramesh Satarkar^{1*} and Dinesh Kulkarni²

¹*Satarkar Gastroenterology Center, Aurangabad, India*

²*Saurabh Eye Care and Histopathology Center, Aurangabad, India*

***Corresponding Author:** Ramesh Satarkar, Satarkar Gastroenterology Center, Aurangabad, India.

Received: September 21, 2020; **Published:** October 15, 2020

Abstract

Hematochezia is a common and often a warning symptom of colonic malignancy especially in patients above 45 year of age. We present a case of Renal Cell Carcinoma (RCC) metastasizing to colon and presenting as hematochezia. The patient had nephrectomy for RCC two years prior to this presentation. RCC is characterized by metastases to unusual sites, late metastases more than five years after the initial illness. It is extremely uncommon to have metastatic lesions in colon. Only a handful of cases with colonic metastases of RCC are described in the literature. In this report, we hope to alert clinicians to the possibility of colonic metastasis, as a cause for hematochezia in patients with a past history of RCC, regardless of the time since nephrectomy.

Keywords: Hematochezia; Colonic Metastases; Renal Cell Carcinoma

Abbreviation

RCC: Renal Cell Carcinoma

Introduction

Hematochezia or bleeding per rectum is a significant symptom, which always has an organic cause. Especially in patients above 45 year of age, it can be harbinger of colonic malignancy. The pattern of bleeding, quantity, associated symptoms are important to predict the possible etiology of hematochezia. Sometimes the cause can be rare and a surprise like rapid upper gastrointestinal bleeding, Meckel's diverticulum or very rarely metastases to the colon. Colonic metastases are rare and are described in Renal Cell Carcinoma [1], Breast carcinoma [2], Lung carcinoma [3] and Hepatocellular Carcinoma [4]. Most of these are case reports. These lesions can masquerade as primary colonic cancer. The diagnosis is based on histopathology of the tissue obtained during colonoscopic examination or surgery. Only when viewed in context of past history and the histology, exact diagnosis is possible. The entire management plan changes once a metastatic disease is diagnosed rather than primary colonic cancer. Hence the importance. Especially in case of RCC and breast cancer metastases can occur years after the primary disease was diagnosed.

Case Report

Mr. B. S. a 52 year old man was referred for colonoscopy in December 2017, with history of bleeding per rectum, left iliac pain and weight loss of one month duration. Blood was mixed in stool, fresh, approximately 25 to 30 ml each time. Bowel frequency was 2 - 3 per day with sense of incomplete evacuation. Pain in left iliac fossa was dull aching; boring in character relieved partially by defecation and was not referred. He lost nearly 4 kg weight in one month. No history of fever, vomiting. He was operated for renal cell carcinoma two years

back and did not receive any chemo or immunotherapy. No history of Diabetes Mellitus, Hypertension or any other illness. He appeared well nourished, looked pale. There was no jaundice, lymphadenopathy, edema or any other positive finding. Colonoscopy was done. It revealed an intraluminal mass lesion approximately 5 cm in length, non-circumferential in the descending colon (Figure 1).

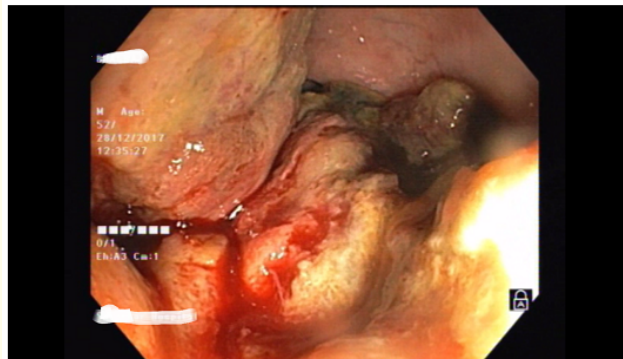


Figure 1: Colonoscopic image showing fleshy, lobulated mass in descending colon.

The lesion compromised the lumen significantly however the scope could be negotiated beyond with efforts. The endoscope could be passed up to transverse colon, beyond which presence of residue in lumen prevented further passage of scope. Biopsies were taken from the lesion. The lesion was friable.

The histology of the lesion showed colonic tubules with ulceration and tumor mass beneath, arranged in glandular pattern separated by fibrous septae and invading muscularis propria (Figure 2). The tumor tissue was arranged in glandular pattern lined by columnar cells with hyper-chromatic nuclei and clear cytoplasm indicative of renal cell carcinoma (Figure 3).

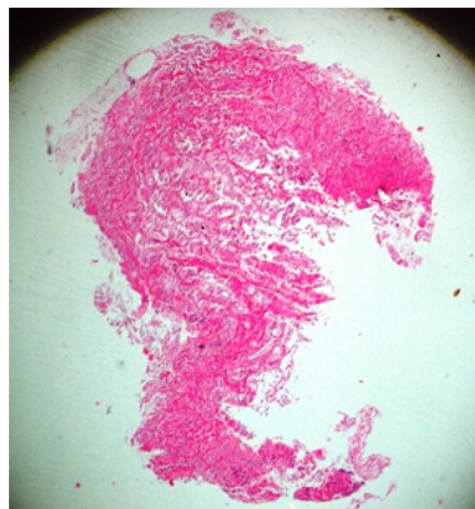


Figure 2: Showing colonic tubules with ulceration and beneath tumor mass arranged in glandular pattern separated by fibrous septae and invading muscularis propria (H & E 5x X 10x).

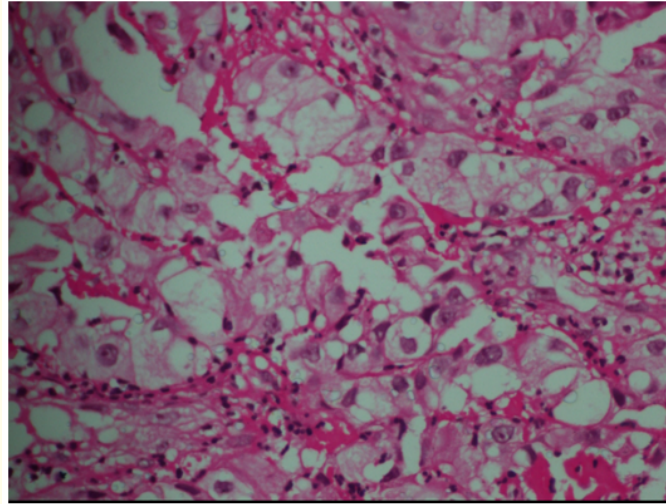


Figure 3: Section shows tumor tissue arranged in glandular pattern lined by columnar cells with hyper chromatic nuclei and clear cytoplasm (H & E 40x X 10x).

The patient went back to the referring surgeon who referred him to an oncologist. He was treated with chemotherapy but succumbed to his illness 4 months later.

Discussion

Cancers of the kidney account for 4% of all newly diagnosed malignancies in men and 3% in women, and most of them are renal cell carcinomas (RCCs) [5]. Kidneys receive 25% of circulating blood volume. Renal cell carcinomas are hyper vascular tumors associated with multiple arteriovenous shunts. Considering this, renal cell carcinoma has a high hematogenous spreading potential. Approximately one-third of patients with RCC present with metastasis at the time of diagnosis, frequently in such vascular-rich organs as the lung and liver. In order of frequency, renal cell carcinoma commonly metastasizes to lung, bone, liver, brain and skin, while metastases to the head and neck region are rarer (8 - 14%), the thyroid accounting for a large percentage of cases [6]. In general, a secondary tumor may be caused by direct extension, peritoneal implantation, lymphatic metastasis or hematogenous spread. The hypothesis proposed by Stephen Paget in 1889, that metastasis depends on cross-talk between selected cancer cells (the 'seeds') and specific organ microenvironments (the 'soil'), still holds good today. The potential of a tumor cell to metastasize depends on its interactions with the homeostatic factors that promote tumor-cell growth, survival, angiogenesis, invasion and metastasis.

In the gastrointestinal tract small as well as large intestine have been described as sites of metastases. Most of the literature reports a single or few cases. A series published by Graham [7] stated only 4% of RCC metastasize to the small intestine, while a more recent Mayo Clinic 50-year review found only 3 cases of small intestinal metastasis in RCC, which did not include cases of direct tumor extension [8].

The colon is an unusual location for metastases for renal cell carcinoma, and less than 15 patients are recorded in the literature [1,9-17] The sites of colonic metastasis also vary; although most commonly, the sigmoid, splenic flexure, transverse colon and hepatic flexure are involved.

Furthermore, the prognosis for non-surgically treated disease in metastatic patients is poor [18,19].

Conclusion

In a patient with history of RCC, any malignant lesion in the gastrointestinal tract or elsewhere could be metastatic RCC and should be evaluated accordingly. This can happen years after nephrectomy for RCC. The entire treatment plan changes accordingly. Surgery followed by chemotherapy and immunotherapy remain the treatments of choice.

Conflict of Interest

There are no conflicts of interest.

Bibliography

1. Valdespino-Castillo, *et al.* "Renal cell carcinoma with colon metastases: an infrequent site for metastases". *Cirugia Y Cirujanos* 76.4 (2008): 339-342.
2. Ali Wadah, *et al.* "Colonic metastasis from a breast carcinoma, an unusual colonoscopic finding". *British Journal of Medical Practitioners* 9.1 (2016): 47-50.
3. Parker Nathaniel, *et al.* "Colonic Metastasis of Lung Adenocarcinoma: A Case Report". *Cureus* 11.3 (2019).
4. Ou Tzu-Ming, *et al.* "Hepatocellular carcinoma with colonic metastasis". *Singapore Medical Journal* 55.6 (2014): e93.
5. Jemal Ahmedin, *et al.* "Cancer statistics, 2010". *CA: A Cancer Journal for Clinicians* 60.5 (2010): 277-300.
6. Spreafico R, *et al.* "Parotid metastasis from renal cell carcinoma: a case report and review of the literature". *ACTA Otorhinolaryngologica Italica* 28.5 (2008): 266.
7. Graham Albert P. "Malignancy of the kidney, survey of 195 cases". *The Journal of Urology* 58.1 (1947): 10-21.
8. Low Donald E, *et al.* "Embolic mesenteric infarction: a unique initial manifestation of renal cell carcinoma". *Surgery* 106.5 (1989): 925-928.
9. Ruiz JL, *et al.* "Renal cell carcinoma: late recurrence in 2 cases". *European Urology* 20 (1991): 167-169.
10. Thomason Philip A, *et al.* "Solitary colonic metastasis from renal-cell carcinoma 17 years after nephrectomy". *Diseases of the Colon and Rectum* 34.8 (1991): 709-712.
11. Tokonabe Shigeki, *et al.* "Solitary colonic metastasis of renal cell carcinoma seven years after nephrectomy: a case report". *International Journal of Urology* 3.6 (1996): 501-503.
12. Avital Shmuel, *et al.* "Localization of monoclonal antibody CC49 in colonic metastasis from renal cell carcinoma". *European Journal of Surgical Oncology* 24.2 (1998): 149-151.
13. Yetkin G, *et al.* "Solitary colonic metastasis of renal cell carcinoma". *Acta Chirurgica Belgica* 108.2 (2008): 264-265.
14. Jadav Alka M, *et al.* "Solitary colonic metastasis from renal cell carcinoma presenting as a surgical emergency nine years post-nephrectomy". *World Journal of Surgical Oncology* 8.1 (2010): 54.
15. Milović Novak, *et al.* "Rare locations of metastastatic renal cell carcinoma: A presentation of three cases". *Vojnosanitetski Pregled* 70.9 (2013): 881-886.
16. Vo Elaine, *et al.* "Solitary colon metastasis from renal cell carcinoma nine years after nephrectomy: A case report". *International Journal of Surgery Case Reports* 27 (2016): 55-58.

17. Zhang Fangyuan., *et al.* "Asynchronous abdominal wall and sigmoid metastases in clear cell renal cell carcinoma: A case report and literature review". *Asian Journal of Urology* 6.2 (2019): 210-214.
18. Guðmundsson Eiríkur., *et al.* "Metastatic potential in renal cell carcinoma \leq 7 cm: Swedish Kidney Cancer Quality Register data". *European Urology* 60.5 (2011): 975-982.
19. Stewart Suzanne B., *et al.* "Evaluation of the National Comprehensive Cancer Network and American Urological Association renal cell carcinoma surveillance guidelines". *Journal of Clinical Oncology* 32.36 (2014): 4059.

Volume 7 Issue 11 November 2020

©2020. All rights reserved by Ramesh Satarkar and Dinesh Kulkarni.