

Perforated Gastric Ulcer Related to SARS Cov-2 (COVID-19)

José Alberto Martínez Valdes^{1*}, José Nicolás García Martín del Campo², Xóchitl Serna Velázquez³, Christopher Jairo Rubio Álvarez¹, Héctor Armando Miranda Blasnich¹, Luis Andrés Sáenz Romero¹, Ana Isabel Rodríguez Venegas¹, Roxana Islas Mendoza¹, Alberto Uriel Garnica Rosales¹, Alan Roberto Vázquez Rebollo¹ and Daniel Ramírez León¹

¹General Surgeon, Department of General Surgery at "Ticomán General Hospital" General Hospital of the Secretary of Health of Mexico City, National Autonomous University of Mexico, Mexico City, Mexico

²Colon and Rectum Surgeon and General Surgeon, Department of General Surgery at "Ticomán General Hospital" General Hospital of the Secretary of Health of Mexico City, National Autonomous University of Mexico, Mexico City, Mexico

³Bachelor of Nursing and Obstetrics, Surgical Department at "Dr. José María Rodríguez" State Health Institute of Mexico, National Polytechnic Institute, México City, México

***Corresponding Author:** José Alberto Martínez Valdes, General Surgeon, Department of General Surgery at "Ticomán General Hospital" General Hospital of the Secretary of Health of Mexico City, National Autonomous University of Mexico, Mexico City, Mexico.

Received: July 04, 2020; **Published:** August 29, 2020

Abstract

Introduction: The coronavirus disease (COVID-19), caused by the Severe Acute Respiratory Syndrome of Coronavirus (SARS-Cov-2), has rapidly become a pandemic, mainly affecting the respiratory system. However, it has been shown to also affect other systems such as circulatory, integumentary, renal, hepatic and digestive, having endothelial injury as a common factor, the latter with repercussions on the surgical area, since surgeons have had to quickly react to this unprecedented clinical challenge, systematically reusing the operating rooms.

There is no specific recommended antiviral treatment for COVID-19, and there is no vaccine currently available. Treatment is symptomatic and oxygen therapy represents the main treatment intervention for patients with a severe infection. However, in patients with acute abdomen data, the treatment remains the same: surgery combined with specific treatment of the disease by COVID-19.

In this paper, we mention 2 clinical cases of patients who presented with acute abdomen data secondary to minor curvature perforated gastric ulcer, with a positive test for COVID-19.

Purpose: To present 2 clinical cases from the Ticomán General Hospital, Secretary of Health, to the surgical community on the presentation and association of gastric ulcers related to SARS Cov-2 (COVID-19).

Results: 2 clinical cases of male patients, who arrived with acute abdomen data of one week of evolution with nausea, emesis, fever, dry cough, and respiratory distress, tests for COVID-19 were taken and resulted positive. However, since it is an acute abdomen, surgical management is decided, finding in both patients perforated gastric ulcers on the minor curvature of the stomach, performing closure in dual plane with placement of a Graham patch, of which one of the patients is currently in torpid evolution, and the other one died 12 hours postoperatively.

Discussion: An outbreak of cases with inexplicable lower respiratory infections detected in Wuhan, China was first reported in December 31st 2019. Unable to identify the causative agent, these first cases were classified as "pneumonia of unknown etiology", later

on January 11, 2020, it was announced that this disease was caused by Coronavirus (COVID-19) caused by the Severe Acute Respiratory Syndrome of Coronavirus (SARS-Cov-2), with subsequent spread worldwide.

Currently, according to the latest studies, there is no evidence of a specific antiviral treatment or vaccine for COVID-19. Oxygen therapy represents the main pillar as treatment for this type of patient, being the symptomatic treatment. Preclinical studies at the time of this publication suggest that Remdesivir could be effective for both prophylaxis and treatment of COVID-19 infections. There are multiple reports on the gastrointestinal manifestations of this disease, presenting as an acute abdomen, for these patients with acute abdomen data, in which excluding surgical pathologies is not possible, the treatment remains the same: surgery with specific treatment of the COVID-19 disease.

Conclusion: It is a truly unknown clinical entity for the medical community and even in the world literature there is no specific bibliographic support that lead us to believe that patients are really suffering from perforated gastric ulcers secondary to infection by SARS Cov-2 (COVID-19), but ischemic lesions that could be related to our cases of interest have been identified and reported, hence the importance of presenting these cases to the medical and surgical communities.

Keywords: *Stomach; Minor Curvature; Gastric Ulcer; Perforation; SARS Cov-2; COVID-19; Acute Abdomen*

Introduction

Coronavirus disease (COVID-19), caused by the Severe Acute Respiratory Syndrome of Coronavirus (SARS-Cov-2), has rapidly become a global pandemic, mainly affecting the respiratory system. However, it has been shown that it also affects other systems such as the circulatory, integumentary, renal, hepatic and digestive, having endothelial injury as a common denominator.

Treatment is symptomatic and oxygen therapy represents the main treatment intervention for patients with severe infection. There are multiple reports on the gastrointestinal manifestations of this disease, presenting as an acute abdomen, for these patients with acute abdomen data, in which excluding surgical pathologies is not possible, the treatment remains the same: surgery with specific treatment of the COVID-19 disease.

Purpose of the Study

To present 2 clinical cases from the Ticomán General Hospital, Secretary of Health, to the surgical community on the presentation and association of gastric ulcers related to SARS Cov-2 (COVID-19).

Case Report

Case 1

A 59-year-old male patient who was admitted to the emergency room in April 14, showing symptoms of colic-type abdominal pain, located in the hypogastrium, intensity 8/10 with irradiation to the mesogastrium and epigastrium, accompanied by nausea, with no emesis and fever, as well as productive cough for 15 days, accompanied by dyspnea from small efforts, self-medicated with pain relievers, unspecified antacids, not having improved, reason why he came to this unit for evaluation. Laboratory test were taken upon admission reporting leukocytes 9.3×10^3 , neutrophils 95%, lymphocytes 2.6%, erythrocytes 5.4×10^6 , Hemoglobin 14.2 g/dl, Hematocrit 52%, platelets 389×10^3 , glucose 151 mg/dl, creatinine 5.85 mg/dl, Alkaline Phosphatase 56 U/L, AST 31 U/L, ALT 62 U/L, uric acid 11.6 mg/dl, BT: 0.7 mg/dl, BD: 0.3 mg/dl, BI: 0.4 mg/dl, sodium 128 mmol/L, potassium 4.2 mmol/L, chlorine 93 mmol/L, BUN 59 mg/dl, urea 126 mg/dl.

Chest X-ray: An increased bronchoalveolar structure is observed, with flow cephalization, as well as bilateral parahilar infiltrate (Figure 1).

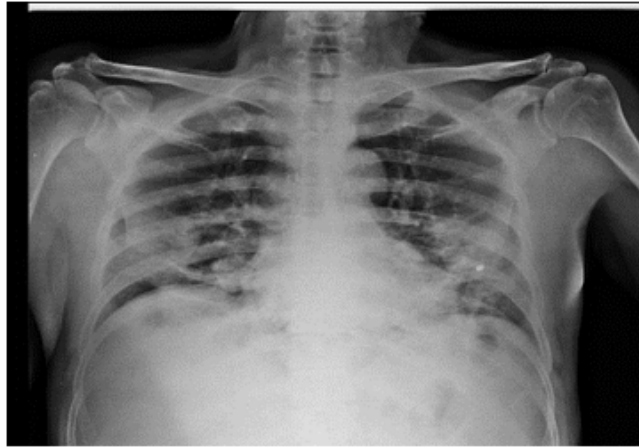


Figure 1: Chest X-ray upon patient admission.

Arterial gasometry: 15.04.20: pH7.4, pCO₂ 17 mmHg, pO₂ 52 mmHg, HCO₃ 10.8 mEq/L, EB: -13 mmol/L, lactate 1.8. mg/dl.

General urine test: 15.04.20: Brown, cloudy urine, pH 5.5, glucose 50 mg/dl, negative nitrites, moderate cells, bacteria +++, granular casts, yeasts.

Ultrasound of the liver and biliary and abdominal tracts: Normal liver, gallbladder 8.6 x 3.9 cm with regular edges, sharp walls, no thickening of its wall (2 mm), common bile duct 0.19 mm, portal vein 7 mm, left kidney with regular edges of dimensions 10 x 7.8 x 6.8 cm, right kidney with regular edges, without evidence of tumor or abscesses of dimensions 12.8 x 5.4 x 5.8 cm.

Clinically, the patient was conscious, oriented, with adequate integument coloration, poor hydration, neck with no adenomegaly, chest auscultation in both lung fields showing bilateral interscapulo-vertebral rales, precordium with normal heart sounds, no added noises, a globose abdomen resulting from an adipose panniculus, normoactive peristalsis, with data on an acute abdomen, thus surgical management was decided on April 15, when exploratory laparotomy was performed, finding a perforated type Johnson III gastric ulcer, 2 x 2 cm, free liquid, 1300 cc abdominal cavity, grade III spleen lesion, therefore, a dual plane primary closure was performed in minor stomach curvature and splenectomy. Taking a Gastric Ulcer Biopsy where micro-thrombi were observed in the micro cuts with Hematoxylin and eosin and Masson's Trichome stain, with no evidence of the existence of *H. pylori* (Figure 2).

The following days after the postoperative period, the patient presented torpid evolution, showing fever quantified up to 38.7°C, dry cough, respiratory distress, desaturating up to 84% to ambient air, thus a chest X-ray is taken (Figure 3) in which general opacity is observed in both lung fields, as well as an increase in the bronchoalveolar structure. Under this situation, a TRMC-19 Questionnaire was carried out resulting on a score of 48 points, which was classified as high risk. Subsequently, the test was carried out by reverse transcriptase polymerase chain reaction (RT-PCR), resulting positive, which confirmed the SARS-Cov 2 (COVID-19) diagnosis. Likewise, secondary to the coughing attacks, the patient shows contained eventration with purulent drainage requiring multiple surgical washes. Therefore, the patient currently maintains an open abdomen status with a Bogota bag, with supportive treatment for COVID-19, complying with antibiotic therapy, irrigation wound care and pain relievers. The patient was discharged after being hospitalized for 40 days, showing

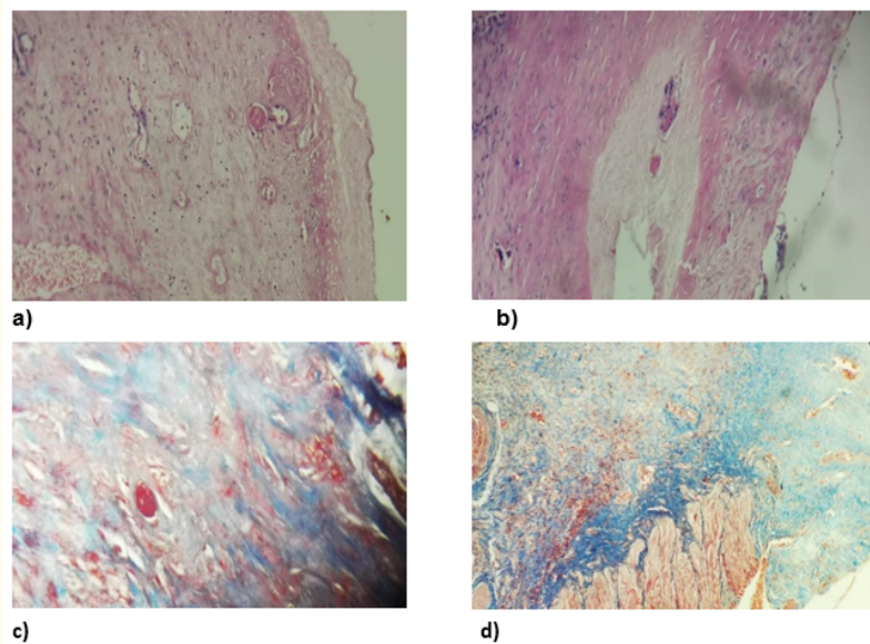


Figure 2: Micro cuts with H&E stain observing micro thrombi (a and b), Micro-cuts with Masson's Trichome stain, observing micro thrombi (c and d). Obtained from: Gastric tissue. Ticoman General Hospital.

remarkable improvement with oxygen saturations of up to 90% with the help of home oxygen and follow-up of open abdomen through wound management clinic.

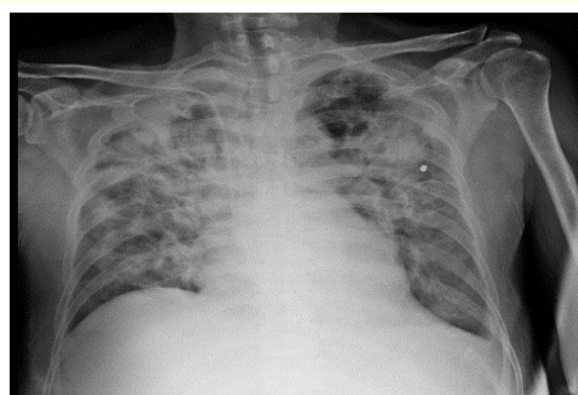


Figure 3: Chest X-ray on the 5th postoperative day.

Case 2

72-year-old male who arrived to the emergency room on May 7, 2020 with abdominal pain located on the left flank with migration to the right iliac fossa, nausea, vomiting, hyporexia, abdominal distention, as well as absence of gas, bowel movements in 72 hours; 24 hours later, the patient shows dry cough, dyspnea, asthenia, adynamia, arthralgias.

Upon physical examination, he was conscious, disoriented, skin and mucosa with good coloration, poor hydration, neck with no adenomegaly, chest with fine bibasal crackles, predominantly left, saturating up to 80% of the precordial environment with decreased heart sounds, a globose abdomen, with abdominal wall with marmorated changes, absence of peristalsis on auscultation, palpation with decreased temperature, positive Von Blumberg sign, on percussion with tympanism in the colic structure.

Laboratory tests are taken on admission reporting leukocytes 2.5×10^3 , neutrophils 81.4%, Hemoglobin 16.5 g/dl, Hematocrit 48%, platelets 174×10^3 , TP 11.4 seg, TPT 33.5 seg, INR 1.05, glucose 119 mg/dl, creatinine 2.77 mg/dl, CK MB 1.5 U/L, myoglobin 500 U/L, Troponin I 0.05 U/L, D-Dimer 4760 mcg/ml, procalcitonin > 10 ng/dl, sodium 130 mmol/L, chlorine 91 mmol/L, potassium 3.8 mmol/L, BT: 1.1 mg/dl, BD: 0.5 mg/dl, BI: 0.6 mg/dl.

Gasometry: 07.05.20 pH 7.31, pCO_2 27 mmHg, pO_2 58 mmHg, HCO_3 13.6 mEq/L, EB: -11.2 mmol/L, lactate 5.8 mg/dl.

Chest X-ray: 07.05.20 Bilateral lattice pattern (Figure 4).

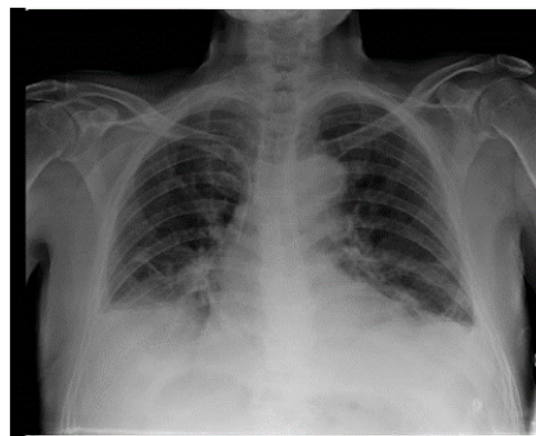


Figure 4: Chest x-ray at admission.

Due to the referred symptomatology of the patient, it was decided to carry out a TRCM-19 questionnaire resulting on a score of 49 points with high suspicion for COVID-19. At that time patient showed data on acute abdomen, presenting data on septic shock, therefore, emergency surgery was decided, performing Exploratory Laparotomy with the following findings: Perforated gastric ulcer Johnson I, liquid free of gastric content of 2500 cc, multiple chemical burns on the liver, omentum, intestinal loops, and free food remains in the omentum transcavity, for which gastric ulcer closure is performed in dual plane, with Placement of Graham’s Patch plus cavity lavage, gastric tissue biopsy is taken where micro thrombi are observed in Hematoxylin and eosin and Masson’s Trichome stain, with no evidence of the existence of *H. pylori* (Figure 5).

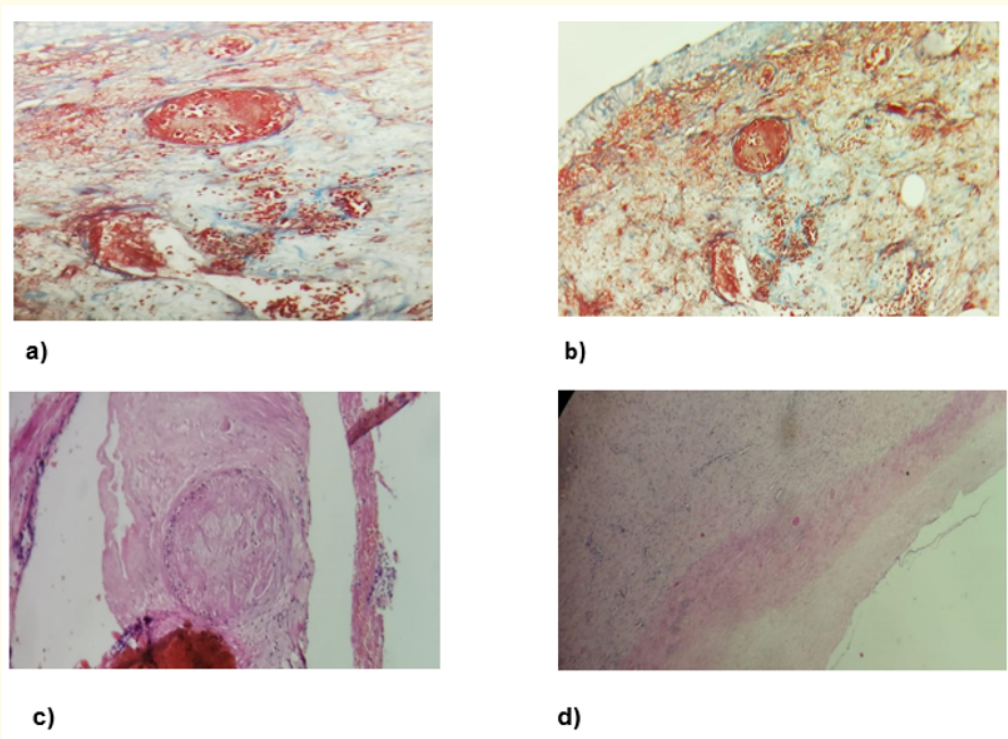


Figure 5: Micro cuts with H&E stain observing micro thrombi (a and b), Micro-cuts with Masson's Trichome stain, observing micro thrombi (c and d). Obtained from: Gastric tissue. Ticoman General Hospital.

The patient is discharged from the operating room in a state of septic shock, under midazolam-based sedation of 100 mg in 100 cc of saline at a dose of 10 cc per hour, norepinephrine 8 mg in 100 cc of 5% glucose solution, at a dose of 20 cc per hour, intubated with fan parameters: Volume control mode, FR: 12, Tidal 390, PEEP 5, Peak 15, FiO₂ 80%, Saturation% 95%; developing with bad clinical and biochemical evolution, resulting in the death of the patient at 02:34 hours on 05.09.20, with a gasometry on May 08 showing pH 6.8, PO₂ 46, pCO₂ 46, pO₂ 61, lactate 8.2, HCO₃ 9.5, Saturation 39%. Given the rush of the events, it was not possible to take RT PCR, however, due to the patient's clinical data, the imaging study, pathology results, and TRCM-19 questionnaire result, it was classified as COVID-19 diagnosis.

Discussion

An outbreak of cases with inexplicable lower respiratory infections detected in Wuhan, China was first reported in December 31st 2019 [1]. Unable to identify the causative agent, these first cases were classified as "pneumonia of unknown etiology"; Currently the etiology is attributed to a new virus belonging to the coronavirus family (CoV). On January 11, 2020 it was announced that this disease was caused by Coronavirus (COVID-19) caused by the Severe Acute Respiratory Syndrome Coronavirus (SARS-Cov-2), with subsequent spread worldwide [2].

Initially, the new virus was referred to as 2019-nCoV. Later on, experts from the International Committee on Taxonomy of Viruses (ICVT) named it SARS-CoV-2 virus, since it is very similar to the one that caused the SARS outbreak (SARS-CoV) [2].

CoVs are positive-stranded RNA viruses that feature crown-like spikes when seen with an electronic microscope (coronam is the Latin term for crown) due to the presence of glycoproteins at the tip of the envelope. The Orthocoronavirinae subfamily, of the Coronaviridae family, is classified into four CoV genera: Alphacoronavirus (alphaCoV), Betacoronavirus (betaCoV), Deltacoronavirus (deltaCoV), and Gammacoronavirus (gammaCoV). Additionally, the betaCoV genus is divided into five sub-genera or lineages [3]. It has been demonstrated that bats and rodents are probably the transmission sources of alphaCoV and betaCoV.

COVID-19 belongs to the betaCoVs category. It is round or elliptical in shape and often pleomorphic, with a diameter of approximately 60 - 140 nm. Like other CoVs, it is sensitive to ultraviolet rays and heat. Furthermore, these viruses can be effectively inactivated by lipid solvents including ether (75%), ethanol, disinfectant containing chlorine, peroxyacetic acid, and chloroform, except chlorhexidine [3].

COVID-19 has been shown to replicate primarily in airway epithelial cells via input receptors for angiotensin-converting enzyme 2 (ACE2). Histological and immunohistochemical studies in cutaneous, pulmonary, and intestinal pathology that involve microvascular injury and thrombosis, which consists of the activation of the alternate pathway and the complement's lectin pathway [4].

According to the latest studies, COVID-19 has been shown to cause diffuse alveolar damage associated with direct damage to pneumocytes, unlike other infections that cause damage due to inflammatory hyperresponsiveness and endothelial damage [5].

Clinical features of COVID-19 are variable, ranging from asymptomatic cases to severe cases characterized by respiratory failure requiring mechanical ventilation and support in an intensive care unit (ICU), to manifestations of multiple organ failure [2]:

- Mild disease: No pneumonia and mild pneumonia.
- Severe disease: Dyspnea, respiratory rate ≥ 30 /min, blood oxygen saturation (SpO_2) $\leq 93\%$, $FiO_2 < 300$ and/or lung infiltrates $> 50\%$ in 24 to 48 hours.
- Critical illness: Respiratory failure, septic shock, or multiple organ failure.

SARS-CoV-2 infects the epithelial cells of the gastrointestinal glands in the stomach, duodenum, and rectum, and, to a much lesser extent, the esophagus [6]. So gastrointestinal symptoms such as diarrhea, vomiting, and abdominal pain have been reported during the course of the disease. SARS-CoV-2 RNA was detected in the patient's stools by reverse transcriptase polymerase chain reaction (RT-PCR) on day 7 of the illness.

Assessment by polymerase chain reaction (PCR) has provided evidence of the virus in stools. The virus in the stools may be evident on manifestation and it may last the entire course of disease resolution for up to 12 days after evidence of the respiratory virus has disappeared [7].

Unlike bacterial sepsis, COVID-19 does not cause an increase in the number of leukocytes or neutrophils. It has been associated with lymphopenia in approximately 80% of patients and mild thrombocytopenia in cases of poorer prognosis [8]. Non-specific elevation of the D-Dimer is also frequent.

It is important to emphasize that procalcitonin does not rise in cases of COVID-19 infection, with procalcitonin less than 0.5 ng/ml, as found in up to 95% of cases. This is of utmost importance with respect to sepsis, where it is a fundamental marker especially in systemic bacterial infections. However, the C Reactive Protein as in the case of sepsis can be elevated with a direct relationship with the prognosis and severity of the disease [9].

Mild to moderate liver injury, including elevated transaminases, hypoproteinemia, and prolonged prothrombin time, have been described in existing clinical research on COVID-19 [10], in addition to a slight elevation in serum bilirubin. Although the mechanism of

liver injury is not fully understood, the injury may be due to direct viral infection of the hepatocytes. It is also suggested that the virus may bind to cholangiocytes through the ACE2 receptor to alter liver function [11]. Evidence from previous SARS studies indicated that the coronavirus has tropism in the gastrointestinal tract so that SARS-CoV RNA can be easily detected in stool samples from SARS patients, and electron microscopy in biopsy and autopsy samples showed active virus replications in the small and large intestines [12]. This gastrointestinal tropism may explain the frequent appearance of diarrhea in coronavirus infection; This suggests the possible tropism of SARS-CoV-2 to the gastrointestinal tract.

Hematoxylin and eosin stain showed no significant damage, but numerous infiltrating plasma cells and lymphocytes, as well as interstitial edema, were observed in the lamina propria of the stomach, duodenum and rectum. More significantly, the results demonstrated a positive stain of the ACE2 protein, mainly in the cytoplasm of gastrointestinal epithelial cells. SARS-CoV-2 has been shown to use this protein as a viral receptor for its entry process [7].

ACE2 stain is rarely seen in the esophageal mucosa probably because the esophageal epithelium is primarily composed of squamous epithelial cells, which express less ACE2 than glandular epithelial cells [8].

Based on these findings, fecal-oral transmission could be an additional route for the spread of SARS-CoV-2, so fecal-oral transmission should also be prevented to try to control the spread of the virus. Therefore, physicians must be careful to quickly identify patients with initial gastrointestinal symptoms as a possible source of infection and emphasize the recommendation of frequent handwashing [13].

So far, there is no specific antiviral treatment or vaccine recommended for COVID-19. Treatment is symptomatic and oxygen therapy represents the main treatment intervention for patients with a severe infection [2]. However, in patients with acute abdomen data, the recommended guidelines for surgical management should not be modified [14], in addition to the specific treatment of the disease by COVID-19, various safety measures have also been implemented, such as strengthening the training of health personnel on the use of Personal Protective Equipment (PPE), a greater use of alcohol-based solutions and repeated hand washes, as well as the systematic use of surgical masks and gloves [15], in order to prevent the spread of the virus among members of the surgical team and other health personnel.

Preclinical studies at the time of this publication suggest that Remdesivir, an RNA polymerase inhibitor with *in vitro* activity against multiple RNA viruses, including Ebola, may be effective for both prophylaxis and treatment of COVID-19 infections.

Regarding the use of medications that can alter the expression and/or function of the ACE2, there is not enough evidence, the only recommendations according to the studies carried out so far is to avoid administering corticosteroids and nebulizations.

The risk of SARS-Cov-2 infection during hospitalization or after digestive surgery is a real, and potentially serious, risk. Measures are necessary to minimize this risk in order to return to safe surgical activities [15].

Conclusion

Coronavirus disease (COVID-19), caused by the Severe Acute Respiratory Syndrome of Coronavirus (SARS-Cov-2), is a truly unknown clinical entity for the medical community and even in the world literature there is no specific bibliographic support that lead us to believe that patients are really suffering from perforated gastric ulcers secondary to infection by SARS Cov-2 (COVID-19), but ischemic lesions that could be related to our cases of interest have been identified and reported, hence the importance of presenting these cases to the medical and surgical communities.

It is important that the surgeon detects such symptoms in these patients and takes the necessary measures, in order for the patient to have reasonable improvement, since this cases represent an unprecedented clinical challenge.

Bibliography

1. CL Yang, *et al.* "Coronavirus disease 2019: a clinical review". *European Review for Medical and Pharmacological Sciences* 24 (2020): 4585-4596.
2. Cascella M., *et al.* "Features, Evaluation and Treatment Coronavirus (COVID-19)". Stat Pearls. Treasure Island (FL): Stat Pearls Publishing (2020).
3. Chan JF, *et al.* "Interspecies transmission and emergence of novel viruses: lessons from bats and birds". *Trends in Microbiology* 21.10 (2013): 544-555.
4. Magro C., *et al.* "Complement associated microvascular injury and thrombosis in the pathogenesis of severe COVID-19 infection: A report of five cases (2020).
5. Xu Z., *et al.* "Phatological findings of COVID-19 associated with acute respiratory distress syndrome". *The Lancet Respiratory Medicine* (2020).
6. Xiao F., *et al.* "Evidence for gastrointestinal infection of SARS-CoV-2". *Gastroenterology* (2020).
7. Cipriano M., *et al.* "Gastrointestinal Infection Could Be New Focus for Coronavirus Diagnosis". *Cureus* 12.3 (2020).
8. Guan WJ., *et al.* "China Medical Treatment Expert Group for COVID-19. Clinical characteristics of coronavirus disease 2019 in China". *The New England Journal of Medicine* (2020).
9. Balibrea JM., *et al.* "Manejo Quirúrgico de pacientes con infección por COVID-19. Recomendaciones de la Asociación Española de Cirujanos". *Cirugía Española* (2020).
10. Gu J., *et al.* "COVID-19: Gastrointestinal manifestations and potential fecal-oral transmission". *Gastroenterology* (2020).
11. Wong SH., *et al.* "Covid-19 and the Digestive System". *Journal of Gastroenterology and Hepatology* (2020).
12. Hung IF, *et al.* "Viral loads in clinical specimens and SARS manifestations". *Emerging Infectious Diseases* 10 (2004): 1550-1557.
13. Domingo JJS. "COVID-19 y aparato digestivo". *Medicina Clínica* (2020).
14. Mazuki JE., *et al.* "The Surgical Infection Society revised guidelines on the management of intra-abdominal infection". *Surg Infect (Larchmt)*. 18 (2017): 1-76.
15. Luong-Nguyen M., *et al.* "Nosocomial infection with SARS-Cov-2 within Departments of Digestive Surgery". *Journal of Visceral Surgery* (2020).

Volume 7 Issue 9 September 2020

©All rights reserved by José Alberto Martínez Valdes., *et al.*