

Experience and Results with the Modified Lift Procedure in the Treatment of Perianal Fistulas

Daniela Castillo¹ and Luis Carlos Ferrari^{2*}

¹Resident of the 3rd Year of the General Surgery of the Aconcagua and Santo Tomás Private Sanatoriums, Córdoba, Argentina

²In Charge of the Coloproctology Section of Sanatorios Aconcagua and Santo Tomás Privado de la Ciudad de Córdoba, Argentina

***Corresponding Author:** Luis Carlos Ferrari, In Charge of the Coloproctology Section of Sanatorios Aconcagua and Santo Tomás Privado de la Ciudad de Córdoba, Argentina.

Received: April 18, 2020; **Published:** August 29, 2020

Abstract

Background: The treatment of perianal fistulae which involves a considerable amount of sphincter tissue can be challenging due to the indexes of recurrence and anal incontinence reported herein. Various sphincter sparing techniques have been proposed to resolve this pathology but none in its own has demonstrated a high index of curing with good continence. The modified LIFT procedure can be a valid alternative to be implemented in the treatment of this pathology.

Objective: Evaluating prospectively the results obtained in the surgery of the perianal fistula using the modified LIFT procedure.

Design: Prospective observational study.

Patients and Method: From May 2011 to June 2014, 26 patients had consecutively surgery for perianal fistula using the modified LIFT procedure.

Results: The average age of the sample was 45,6 years of which 80.8% were male patients, 17 had an transsphincteric fistula (65.4%) and 9 had a suprasphincteric perianal fistula (34.6%). All these patients were treated with the modified LIFT procedure. The occasional opening of some of the cutaneous closures was the most frequent complication (42,3%) predominating the closure where the external opening was 8/11. Only one patient suffered from a postoperative bleeding which was stopped through a compression procedure. There were no infections and the hospital stay was of one day. The average time of wound healing was of 31.7 days. It was recurring in 4 patients (15,4%) with an index of healing of 84.6%. None of the patients showed any degree of incontinence during the different postoperative controls.

Conclusion: The modified LIFT procedure for the treatment of perianal fistulae which involves a considerable amount of sphincter tissue was feasible to be put into practice. It was less invasive than the conventional techniques causing no sphincter wounds and resulting satisfactorily at least in the initial stage if it is compared with the different series published.

Keywords: Perianal Fistula; LIFT Procedure

Introduction

A perianal fistula is a chronic inflammatory path that connects two epithelialized surfaces, in this case the anus rectal lumen with the perianal skin, which may be a single path or present secondary extensions, representing the chronic phase of the anus rectal infection and

characterized by generating purulent discharge variable presentation or repeated episodes of pain associated with the cyclical formation of abscesses and spontaneous or surgical drainage [1-5]. It has been and is, a common problem since the various human ailments could be documented; Hippocrates in 400 BC already referred to his treatment by fistulotomy or line placement, using horsehair for this purpose [1,2,6]. Currently, the “gold standard” in the surgical treatment of this pathology includes the eradication of the septic focus and of the fistulous tract (s) with preservation of sphincter function and avoiding recurrence [5-7]. When perianal fistulas are low or posterior or involve little or no sphincter tissue, treatment is based on a fistulotomy or simple fistulectomy; but when its path runs long between the sphincter bundles, the probability of generating some degree of incontinence increases almost linearly [6-8]. In order to minimize this problem, various techniques were developed, such as the endo rectal flap, the skin advancement flap, the biological plug for fistula repair, the use of fibrin glue. The first two techniques mentioned can be more or less demanding and in some situations operator dependent; In case of using the biological plug or fibrin glue, a high percentage of long-term recurrence should be added to the high cost of these [4]. In 2007, Rojanasakul, *et al.* [4] presented a technique of “intersphincteric ligation of the fistulous tract” called LIFT, in which they proposed the ligation and section of the fistulous tract in the intersphincteric space, accompanied by the treatment of the crypto glandular complex and the “systematic curettage” and closure of the external orifice. This presentation and other similar ones generated later, encouraged us to treat perianal fistulas that compromised a considerable volume of sphincter tissue with this technique [5-12]. As of May 2011, we operated on a series of patients with perianal fistula using the LIFT procedure with some modification. Its description and the results obtained are presented below.

Materials and Methods

A prospective observational study was designed that included all patients with perianal fistula undergoing surgical treatment using the LIFT procedure in two Private Institutions in Córdoba, Argentina, from May 2011 to June 2014. The type of perianal fistula was defined from the Parks classification; that is to say: type 1 or intersphincteric, type 2 or transsphincteric, type 3 or suprasphincteric and type 4 or extra-sphincteric. To this classification we could add a fifth type, superficial, called “subcutaneous” or “fistulae”. Likewise, the variables that were taken into account in the data collection form were the following: age, sex, procedure performed, presence of postoperative complications such as: bleeding, opening, infection or recurrence, defining the latter as the reappearance of suppuration through an external hole generated after healing the initial wound; the senatorial stay, the healing time; the pathological anatomy, the location of the fistula, presence or absence of incontinence. Initial postoperative controls were also collected at 15 and 30 days and until complete healing. We excluded patients who did not accept the procedure or those who had fistulas perianales subcutaneous or fistulas intersphincteric at the time of valuation intra operative. All patients underwent cardiovascular evaluation and preoperative blood tests. The pre-surgical preparation was similar to that previously described in previous presentations, as was the protocol followed the day of hospitalization.

Operative technique

Under spinal anesthesia, skin antisepsis with iodopovidone to 10%, placement of surgical fields - patient in lithotomy position; anal inspection and then placement of half-shaft anoscope. From the individualization of the external hole, through the use of hydrogen peroxide, the internal hole is individualized (Figure 1). The fistulous tract is then gently “channeled” or “tutored” using a thin, blunt-ended stylet and an arciform incision of approximately two centimeters is made in the intersphincteric skin plane. Through gentle blunt dissection maneuvers, the fistulous path of the sphincter muscle bundles is “isolated” and “pulled” with a polyglactin strand (Figure 2); the stylet is then removed and the crypto glandular complex is resected from the anus rectal canal, closing the mucosa with one or two 3 “0” polyglactin points; Subsequently, the fistulous tract is ligated and sectioned in the intersphincteric plane, by means of 3 “0” polyglactin points, resecting a segment thereof if necessary (Figure 3). An incision is then made around the external orifice and is resected along with the remaining extra-sphincteric fistulous tract. Finally, the skin incisions are closed with separate points of polyglactin 3 “0” (Figure 4). The wounds are covered with fluo gauze. Note: if you have hemorrhoids prolapsed as illustrated case, it is possible to combine this technique with a Buie procedure (Figure 5). During the postoperative stay follows intravenous hydration (EV), nothing by mouth until the other

day, ketorolac 30 mg EV every 6 hours, nalbuphine 1cc subcutaneous (SC) every 8 hours, cefalotin 1g EV every 8 hours (two doses). The sanitary discharge is granted the following day, after tolerating breakfast, indicating: ketorolac 20 mg orally (PO) every 6 hours - 5 days - tramadol 50 mg (PO) every 8 hours - 7 days - amoxicillin clavulonate 1 gram (PO) every 12 hours - 7 days; diet with high residue, warm sits baths with the addition of 10% iodopovidone to maintain the hygiene of the area and stimulate healing and postoperative control at 15 days and 30 days.

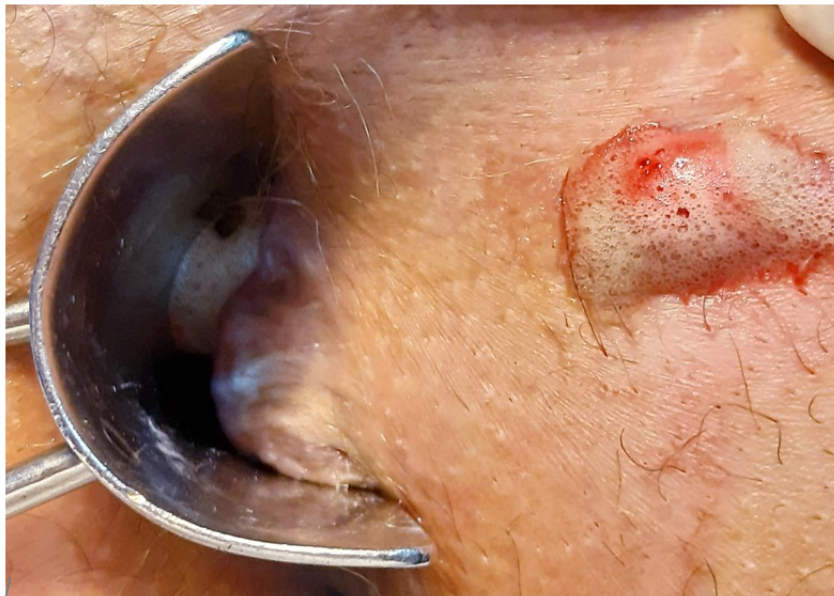

Figure 1: Individualization of the internal hole by using hydrogen peroxide.

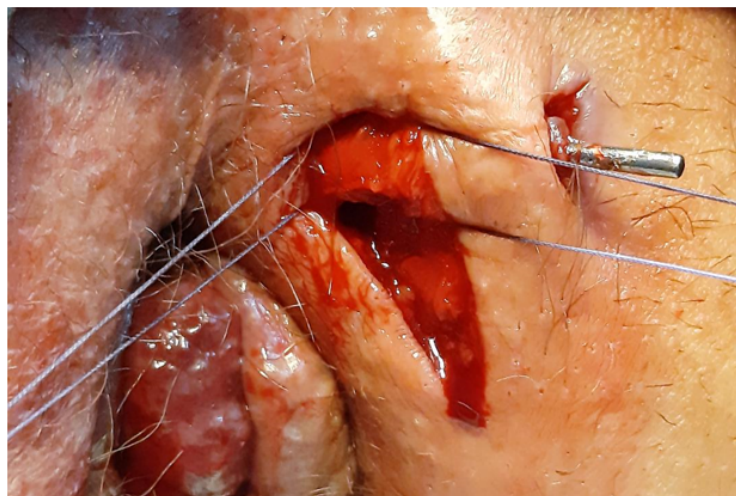

Figure 2: Marking of the intersphincteric fistulous path.

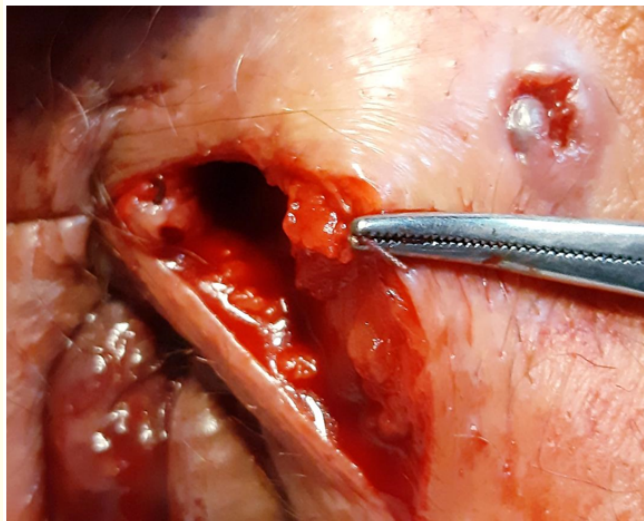


Figure 3: After ligation with a transfixion point, section of the fistulous tract.

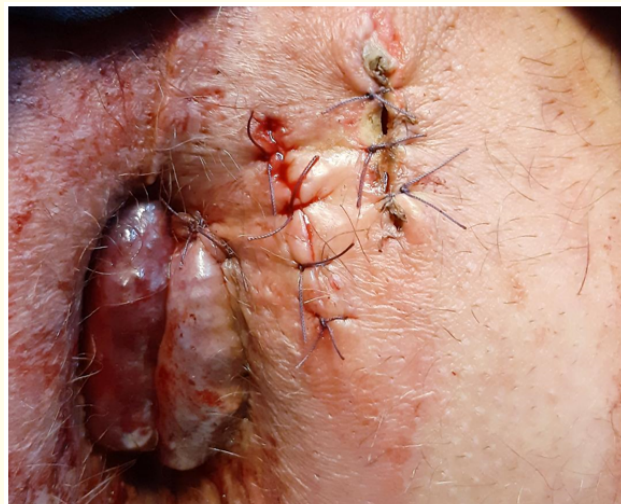

Figure 4: Closure of the skin incisions.

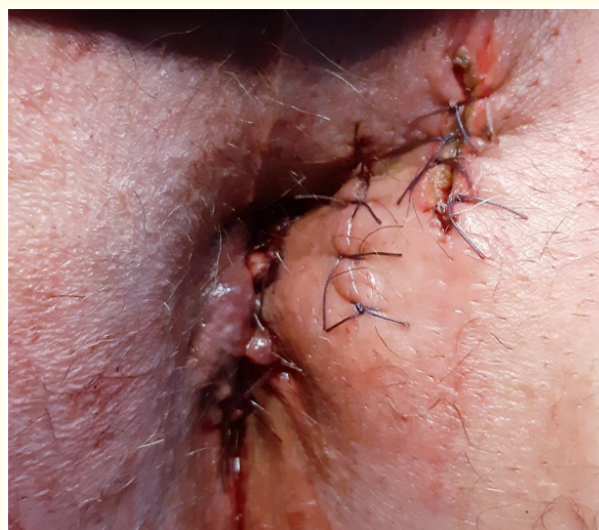

Figure 5: The LIFT Procedure was punctually completed in this case with a hemorrhoidectomy of the left hemi anus according to the Buie Technique.

Results

Between 01/05/2011 and 06/30/2016 (62 months), 41 consecutive patients with perianal fistula were surgically intervened by the same surgeon, of whom 26 underwent a LIFT procedure constituting the sample to be analyzed. The average age was 45.6 years (20/67), of which 80.8% (21/26) were male. The procedure performed was similar to that described in the original technique with the addition of resection of the extra sphincteric fistulous tract from the external orifice. Regarding the postoperative complications collected, bleeding was evident in only one patient (3.85%); it yielded with a compression bandage; the opening of some of the skin closures in eleven (42.3%) - a frank predominance of the closure where the external orifice was previously (8/11), recurrence in four (15.4%) with a percentage of cure 84.6% (22/26). There were no patients with infection. The senatorial stay was one day. The healing time was 31.7 days (25/42); This last variable was prolonged in those patients who showed opening of any of the skin wounds: 34.09 days with opening versus 27.67 days without opening. The pathological anatomy reported in all cases perianal fistula; in 17 (65.4%) they were transsphincteric fistulas and in 9 (34.6%) suprasphincteric fistulas. Regarding the location of the external hole, 7/26 (26.9%) were anterior right, 10/26 (38.5%) posterior right, 04/26 (15.3%) anterior left, and 05/26 (19.2%) posterior left. There were no patients who presented or referred during the different postoperative controls any degree of incontinence. Of the 15 excluded patients, 12 had an intersphincteric fistulous tract, so a simple fistulectomy was performed, and the remaining three did not accept the procedure, so a partial fistulectomy with latex line placement was performed.

Discussion

Currently, the management and surgical treatment of perianal fistulas, particularly those that involve a significant portion of sphincter tissue during their journey, include: removal of the septic focus, of the fistulous tract (s) with preservation of sphincter function, avoiding or decreasing the recurrence rate [9-13]. In recent years, several "sphincter-preserving" techniques have been described and are used for the treatment of these fistulas, but none of them alone has demonstrated a high cure rate with good continence [11,13,14]. Those that use advancement flaps can be technically difficult and not exempt from generating different degrees of incontinence, which in some series can affect more than 35%; On the other hand, the use of the biological plug or the fibrin glue, although initially they showed promising results over time, these were generating disenchantment due to the appearance of recurrences of more than 84% for the fibrin glue and more than 66% for the biological stopper to which it was necessary to add its high cost [9-11].

Very interested in the technique proposed by Rojanasakul and its initial results [12], we decided to develop our own experience with the LIFT procedure in two Private Institutions in the City of Córdoba, Argentina. We initially included 41 consecutive patients. We do not routinely use Nuclear Magnetic Resonance or Endo Rectal Ultrasound to assess the type of fistula presented by patients as proposed by other authors; We consider that the systematic use of these two studies would not be necessary in addition to being onerous [7,13-15]. If we consider the assessment under anesthesia that precedes the surgical act itself to be of utmost importance; When it comes to subcutaneous fistulas or intersphincteric fistulas, which do not involve or involve a minimal amount of sphincter tissue, generally a fistulotomy or a simple fistulectomy are sufficient [7-16]; 12 patients out of 41 presented this type of fistula and were resolved with a simple fistulectomy and therefore excluded from our series; and others with transsphincteric fistulas of the Parks classification [17] did not accept the procedure and were resolved with partial fistulectomy plus line placement and were also excluded.

Regarding the operative technique used, it was almost identical to that described by Rojanasakul [12]; We only added to it the resection of the extra-sphincteric fistulous tract from the external orifice as proposed by Shanwani, *et al.* since it seems to us more radical than the simple curettage [16]. Eleven patients out of the 26 in the sample (42.3%), presented partial or total opening of some of the skin wounds with frank predominance of closure of the external orifice (8/11); only one presented postoperative bleeding that was inhibited with compression maneuvers and in 4 patients (15.4%) recurrence was observed, with a cure rate of 84.6%, which is comparable to other

series in the short term [4,6,9,16]. In the retrospective work by Liu, *et al.* in an attempt to assess the long-term results of this technique [18] the 12-month cure rate was 62%. We do not have long-term data (six months or more).

During the postoperative controls, no patient reported any degree of incontinence and all were satisfied with the procedure performed, even those in which some of the skin incisions opened. Healing time was subjectively shorter and less traumatic than the conventional techniques - Fistulotomy, fistulectomy with/without placing line - but we soon established through a comparative with such techniques if this is real or is a mere impression. We have no experience in the treatment of video-assisted perianal fistulas as proposed by Mainero and that Salim and Gómez have recently been reproduced in our country [3].

Conclusion

The LIFT procedure for the treatment of perianal fistulas involving a considerable amount of sphincter tissue was feasible to carry out, less invasive, with less tissue injury, without sphincter injury and with at least satisfactory initial results comparable to the different series published by which represents to our understanding a valid alternative to consider.

Bibliography

1. Baistrocchi J. "Biological prosthesis for the treatment of complex anal fistulas". *Revista Argentina de Coloproctología* 24.1 (2013): 19-23.
2. Graziano A. "Diagnosis and treatment of benign anal affections". *Revista Argentina de Cirugia* (2004).
3. Salim LR and Gómez CA. "Treatment of complex anal fistula assisted by video. Long-term results". *Revista Argentina de Coloproctología* 29.1 (2018): 16-21.
4. Rojanasakul A., *et al.* "Total anal sphincter saving technique for fistula in ano the ligation of intersphincteric fistula tract". *Journal of the Medical Association of Thailand* 90.3 (2007): 581-586.
5. Shawki S and Wexner SD. "Idiopathic fistula in Anus". *World Journal of Gastroenterology* 17.28 (2011): 3277-328.
6. Abcarian AM., *et al.* "Ligation of intersphincteric fistula tract: Early results of a pilot study". *Diseases of the Colon and Rectum* 55.7 (2012): 778-782.
7. Sileri P., *et al.* "Ligation of the intersphincteric fistula tract (LIFT) to treat anal fistula: early results from a prospective observational study". *Techniques in Coloproctology* 15.4 (2011): 413-416.
8. García Aguilar J., *et al.* "Anal fistula surgery. Factors associated with recurrence and incontinence". *Diseases of the Colon and Rectum* 39.7 (1996): 723-729.
9. Aboulian A., *et al.* "Early results of ligation of the intersphincteric fistula tract for fistula in ano". *Diseases of the Colon and Rectum* 54.3 (2011): 289-292.
10. Bleir JIS., *et al.* "Ligation of the intersphincteric fistula tract: An effective new technique for complex fistulas". *Diseases of the Colon and Rectum* 53.1 (2010): 43-46.
11. Ooi K., *et al.* "Managing fistula in ano with ligation of the intersphincteric fistula tract procedure: the Western Hospital experience". *Colorectal Disease* 14.5 (2011): 599-603.
12. Rojanasakul A. "LIFT procedure: a simplified technique for fistula in ano". *Techniques in Coloproctology* 13.3 (2009): 237-240.

13. Mushaya C., *et al.* "Ligation of intersphincteric fistula tract compared with advancement flap for complex anorectal fistulas requiring initial seton drainage". *American Journal of Surgery* 204.3 (2012): 283-289.
14. Tan KK., *et al.* "The anatomy of failures following the ligation of intersphincteric tract technique for anal fistula: a review of 93 patients over 4 years". *Diseases of the Colon and Rectum* 54.11 (2011): 1368-1372.
15. Van Onkelen RS., *et al.* "Ligation of intersphincteric fistula tract in low transsphincteric fistulae: a new technique to avoid fistulotomy". *Colorectal Diseases* 15.5 (2012): 587-591.
16. Shanwani A., *et al.* "Ligation of the intersphincteric fistula tract (LIFT): a sphincter saving technique for fistula in ano". *Diseases of the Colon and Rectum* 53.1 (2010): 39-42.
17. Parks AG., *et al.* "A classification of fistula in ano". *British Journal of Surgery* 63.1 (1976): 1-12.
18. Liu WY., *et al.* "Long-term results of ligation of intersphincteric fistula tract (LIFT) for fistula in ano". *Diseases of the Colon and Rectum* 56.3 (2013): 343-347.

Volume 7 Issue 9 September 2020

© All rights reserved by Daniela Castillo and Luis Carlos Ferrari.