

Case of a Child with Schwachman Diamond Syndrome - Presenting with Failure to Thrive and Diarrhoea

Ahmed Kadir^{1*} and Israa Al-Agib²

¹Paediatric Gastroenterology Consultant, Royal Manchester Children's Hospital, UK

²Paediatric Trainee, Royal Manchester Children's Hospital, UK

***Corresponding Author:** Ahmed Kadir, Paediatric Gastroenterology Consultant, Royal Manchester Children's Hospital, UK.

Received: June 09, 2020; **Published:** July 06, 2020

Abstract

This case report demonstrates the diagnosis of Schwachman-Diamond syndrome in a child who was not thriving with loose stools. Children with Schwachman-Diamond syndrome can present with different signs and symptoms. Our child presented with persistent loose stools and failure to thrive. Investigations revealed pancreatic insufficiency and raised liver function test with normal full blood count. The combination of pancreatic insufficiency and raised Liver function raised the possibility of Schwachman-Diamond syndrome which was confirmed on genetic testing.

Keywords: Child; Schwachman Diamond Syndrome (SDS); Diarrhoea

Background

Swachman-Diamond syndrome (SDS) is a rare autosomal recessive disorder characterised by exocrine pancreatic insufficiency, bone marrow dysfunction, and skeletal abnormalities [1]. In the majority of children it presents with steatorrhea and failure to thrive as a result of exocrine pancreatic insufficiency [2].

Children will also have haematological abnormalities most commonly neutropenia but can have normochromic normocytic anaemia and in some children thrombocytopenia as well. Cytopenias are usually seen at an early age but can present at later stage as well [3]. Patients with SDS have an increased risk of myelodysplasia, in particular, development of acute myelogenous leukemia [4]. Children with SDS also have skeletal abnormalities due to abnormal development of growth plates. Metaphyseal dystosis is reported in around 50% of patients which is usually asymptomatic and involves the long bones [5]. Hepatomegaly occurs in around 15% of patients with deranged liver function in about 50 - 75%. These abnormalities typically occur early in life and normalise over time [6].

Case Report

A 28 week old female child was referred from a district general hospital due to failure to thrive, persistent diarrhoea and symmetrical IUGR (Intrauterine growth restriction). She was born at 37 weeks via normal delivery following induction of labour due to concerns regarding a decline in growth at 35 weeks. Birth weight of 2.14 kg (2nd centile) head circumference 32 cms (25th Centile), was discharged home on full formula feeds.

Initially seen at her local hospital in clinic at 17 weeks old, due to slow weight gain and recurrent loose motion at this time she weighed 3.92 kg and length 56 cm, failure to thrive screen was done which showed an elevated alanine aminotransferase (ALT). Our patient was regularly followed up at 4 week intervals at local hospital with minimal weight gain noted despite changes made in formula feeds. Upon her last review liver function tests showed an increasing trend otherwise biochemistry. Our child had a negative sweat test and faecal

reducing substances. Faecal elastase was undetectable and therefore was referred to tertiary paediatric gastroenterology centre. Ultrasound of abdomen showed normal liver and spleen. Chest Xray showed thinning of ribs proximally and there was a widened appearance of the distal ends of the ribs bilaterally.

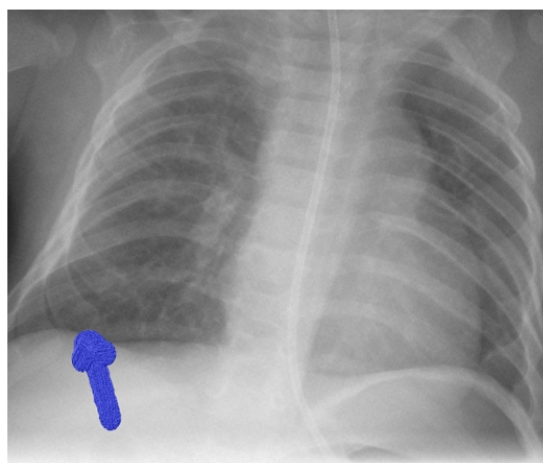


Figure 1: Chest Xray shows widened appearance of ribs distally.

Elective admission was arranged at 28 weeks of age under the gastroenterology team to assess faltering growth with low faecal elastase. We started pancreatic enzyme supplements in her feed for with fat soluble vitamin. The child was taking less amount orally hence a nasogastric tube was inserted through which the child had top ups. Genetic test later on confirmed Schwachman-Diamond syndrome.

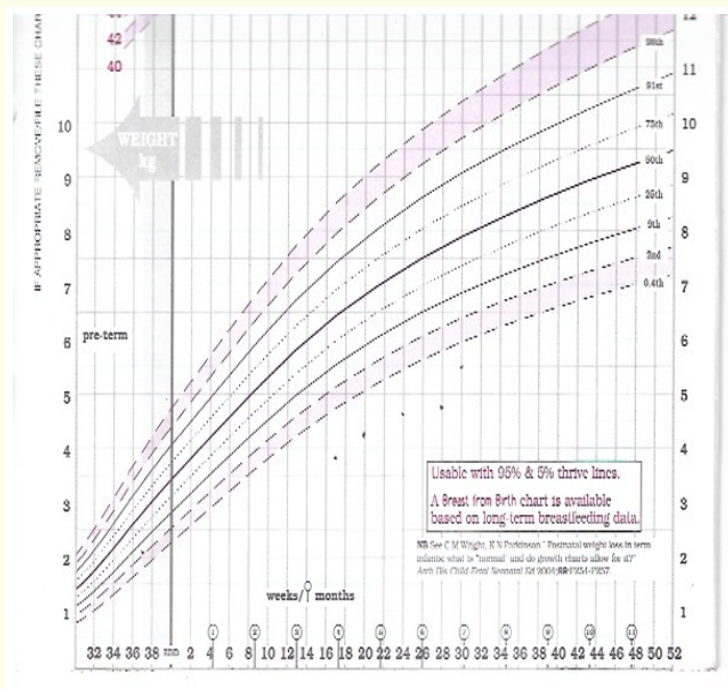


Figure 2: Growth chart of patient-demonstrating increase in weight after starting pancreatic enzyme supplement.

Child is currently thriving well on oral feeds with NG top ups, LFT's are now improving and has been under regular follow up with our haematology team.

Discussion and Conclusion

Schwachman Diamond syndrome (SDS) was first described by Bodian., *et al.* for the first time in 1964. Presentation of SDS can vary most commonly presents with loose stools, failure to thrive and recurrent infections. SDS gene is located on chromosome 7q11. The SBDS gene is composed of 5 exons; it has a 1.6-kb transcript and encode a protein of 250 amino acids, which is a member of highly conserved protein family, Genetic analysis in Caucasian patients has revealed two common mutations associated with SDS, those resulting from gene conversion due to recombination between the SBDS and SBDSP genes [7]. Management of SDS is multidisciplinary involving paediatric gastroenterologist, haematologist, genetics, dietitian and speech language therapist. As our child presented with failure to thrive and loose stools early pick up and aggressive management help in growth and reduces the complications.

Bibliography

1. Harry Shwachmana., *et al.* "The syndrome of pancreatic insufficiency and bone marrow dysfunction". *The Journal of Paediatrics* 65 (1964): 645-663.
2. Mack DR., *et al.* "Schwachman syndrome: exocrine pancreatic dysfunction and variable phenotypic expression". *Gastroenterology* 111.6 (1996): 1593-1602.
3. Lesesve JF., *et al.* "Schwachman-Diamond syndrome with late-onset neutropenia and fatal acute myeloid leukaemia without maturation". *European Journal of Haematology* 71.5 (2003): 393-395.
4. Woods WG., *et al.* "The occurrence of leukemia in patients with the Schwachman syndrome". *Journal of Paediatrics* 99.3 (1981): 425-428.
5. Makitie O., *et al.* "Skeletal phenotype in patients with Shwachman-Diamond syndrome and mutations in SBDS". *Clinical Genetics* 65.2 (2004): 101-112.
6. Cipolli M., *et al.* "Schwachman's syndrome: pathomorphosis and long-term outcome". *Journal of Pediatric Gastroenterology and Nutrition* 29.3 (1999): 265-272.
7. Jeong Hee Lee., *et al.* "A Case of Schwachman-Diamond Syndrome Confirmed with Genetic Analysis in a Korean Child". *Journal of Korean Medicine* 23.1 (2008): 142-145.

Volume 7 Issue 8 August 2020

©All rights reserved by Ahmed Kadir and Israa Al-Agib.