

## Pseudomembranosa Colitis Pseudomembranous Colitis

Joshua Bayer of Carvalho<sup>1</sup>, Marcelo Fabricius Andreani<sup>2</sup> and Marlene Raimunda Andreola Perazzoli<sup>3\*</sup>

<sup>1</sup>General Surgeon, Salvatoriano Divino Salvador Hospital and Santa Maria Hospital, Videira, Brazil

<sup>2</sup>Endoscopist and General Surgeon, Salvatoriano Divino Salvador Hospital and Santa Maria Hospital, Videira, Brazil

<sup>3</sup>Specialist in Intensive Care, University of Vale do Rio dos Sinos in São Leopoldo/RS, Brazil

**\*Corresponding Author:** Marlene Raimunda Andreola Perazzoli, Specialist in Intensive Care, University of Vale do Rio dos Sinos in São Leopoldo/RS, Brazil.

**Received:** April 14, 2020; **Published:** July 30, 2020

### Abstract

Pseudomembranous colitis was initially described in 1893 by Finney, resulting in an infectious disease which arises in the daily antibiotic consume, leading basically to diarrhea symptoms, induced by *Clostridium difficile* toxin inflammatory reactions. This case report exhibits an 80<sup>th</sup>-year patient who, after being treated of an limb cellulitis, with pain, blush and heat, with ciprofloxacin 500 mg 12/12h, being curable. Thirty five days later, patient returns presenting abdominal pain and distention and volumes mucosal diarrhea. Submitted to a retossigmoidoscopy followed by a biopsy, diagnosing a diffuse pseudomembranous colitis, clinically treated, avoiding the surgical treatment.

**Keywords:** Colitis Pseudomembranous; Diarrhea; Colonoscopy

### Introduction

Pseudomembranous colitis (MPC) is a disease characterized by fever, abdominal pain and voluminous and persistent diarrhea, which usually arises as a result of previous antibiotherapy, with *Clostridium difficile* as its etiological agent [1,2]. What it looks like be related to the increasing use of antibiotics, and to the increase in the age range of hospitalized patients and longer hospitalizations [3,4]. MPC is characterized by the presence of important hyperemia and randomized yellow/esb plaques or pseudomembranes formed by an inflammatory exudate, consisting of fibrin, mucus, neutrophils and necrotic epithelial cells [4] in the colonic mucosa. In the state of active disease, the epithelium of the colon is the major target of *Clostridium difficile* toxins [5]. *C. difficile* infection begins with disturbance of the normal microflora of the colon [6-8]. Antibiotics act by destabilizing the normal microflora of the colon, allowing the establishment and proliferation of *C. difficile* of endogenous or exogenous origin and the pathogenesis of infection usually begins with the ingestion of the body usually in the form of resistant spores. The spores survive gastric acidity, germinate in the small intestine to the vegetative form and colonize the colon, where it produces in toxins that initiate a series of phenomena that culminate in the loss of barrier function of epithelial cells, the appearance of diarrhea and the formation of pseudomembranes [9,10].

### Case Report and Discussion

An 80-year-old woman, hospitalized with abdominal distension and pain, mucous diarrhea, developing septic condition, performed rectosigmoidoscopy, presenting numerous areas with plaques covered by purulent secretion, surrounded by important mucosal edema, with an endoscope aspect compatible with severe grade pseudomembranous colitis. Local biopsies were performed and sent for histopathology.

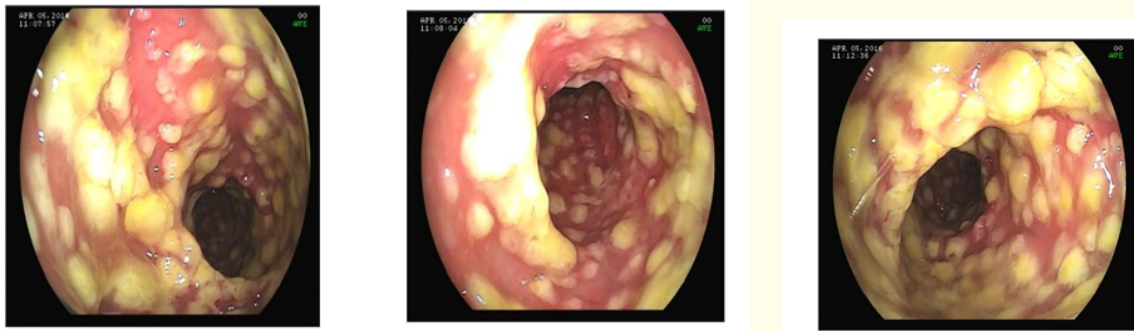

Figure 1: Challenge sigmoidoscopy - 05/04/2016.

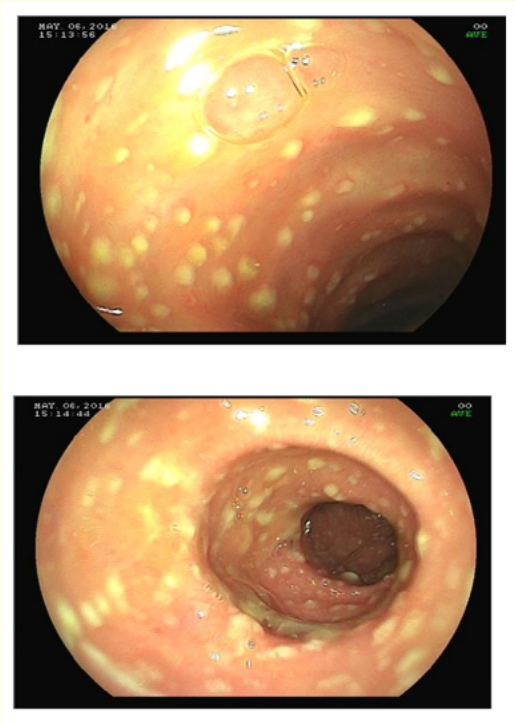
He started treatment with Metronidazole 400mg of 8/8 hours, associated with Vancomycin 500 mg of 6/6 hours, both orally, presenting favorable evolution both clinical and laboratory, between the first (Hbg: 10.6; Ht: 31.5; Leucocytes: 32,300; Bats: 18%) and the second day of hospitalization (Hbg: 10.7; Ht: 31.8; Leukocytes: 10000; Bats: 2%); as well as improvement in the inflammatory pattern of the sigmoid mucosa on rectosigmoidoscopy after seven days.

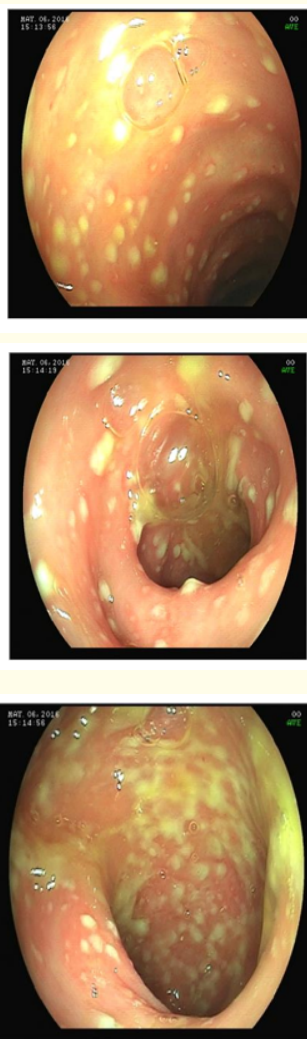

Figure 2: Challenges Scopiascopia - 13/04/2016.

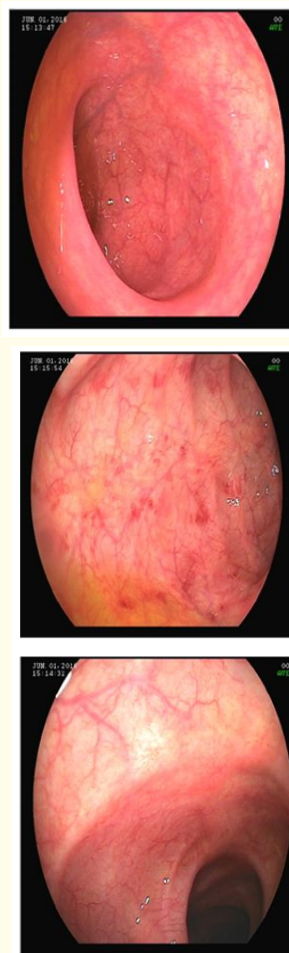
The descending colon is observed the presence of punctiform-purulent lesions, with the aspect of pseudomembranous colitis. There was a favorable evolution of the condition, and in the rectum it is almost observed that the total resolution of the findings endoscopies. Antibiotic therapy was discontinued for 14 days treatment. Histopathological examination concluded chronic ulcerated inflammation.

After thirty-five days, a patient was hospitalized again with the condition, diarrhea and abdominal pain, with the same laboratory alterations with septic aspect. In a new rectosigmoidoscopy, recurrence of the condition is observed.



**Figure 3:** Rectosigmoidoscopy - 06/05/2016, descending colon, sigmoid and rectum presenting numerous punctiform plaques covered by purulent secretion surrounded by mild edema of the endoscope-like mucosa with moderate pseudomembranous colitis.

In relation to the 4/5 examination, there was an improvement, but in relation to the 4/13 examination there was an unfavorable evolution. We chose to restart treatment with Metronidazole 400 mg for 8/8 hours for another 21 days and Vancomycin 500 mg for 6/6 hours for another 10 days, including orally, both suspended by the patient's favorable clinical evolution and laboratory test findings.



**Figure 4:** Rectosigmoidoscopy- 01/06/2016. Fifty-nine days after the first exam. Some superficial erosions of nonspecific aspect, without purulent and rectus secretion preserved with normal mucosa, without inflammatory signs are observed.

## **Conclusion**

Pseudomembranous colitis is a rare disease, but it can be prevented by avoiding the indiscriminate use of antibiotics. It should be investigated in any patient who has persistent and large diarrhea for 72 hours or more after hospitalization and/or who has received previous antibiotic therapy indefinitely. Rectosigmoidoscopy associated with biopsy establishes an important tool, allowing the correct diagnosis and management of the case, preventing more aggressive and invasive interventions.

## **Bibliography**

1. Archibald LK, et al. "Secular Trends in Hospital-Acquired *Clostridium difficile* Disease in the United States, 1987-2001". *Journal of Infectious Diseases* 189.9 (2004): 1585-1589.
2. Morris A, et al. "*Clostridium difficile* colitis: an increasingly aggressive iatrogenic disease". *Diseases of the Colon and Rectum* 44 (2001): A5-A26.
3. Freeman J, et al. "The changing epidemiology of *Clostridium difficile* infections". *Clinical Microbiology* 23.3 (2010): 529-549.
4. Sunenshine RH and McDonald LC. "*Clostridium difficile*- associated disease: new challenges from an established pathogen". *Cleveland Clinic Journal of Medicine* 73.2 (2006): 187-197.
5. Rocha M, et al. "*Clostridium difficile* as an inducing agent of inflammatory diarrhea". *Journal of the Brazilian Society of Tropical Medicine* 32.1 (1999): 47-52.
6. Silva C and Salvino C. "A torial clinical, epidemiological and labor aspects of *Clostridium difficile* infections". *RBAC* 35.2 (2003): 65-71.
7. Elliot B, et al. "*Clostridium difficile*-associated diarrhea". *Internal Medicine Journal* 37 (2007): 561-568.
8. Janoir C, et al. "Cwp84, a surface-associated protein of *Clostridium difficile*, is a cysteine protease with degrading activity an extracellular matrix proteins". *Journal of Bacteriology* 189.20 (2007): 7174-7180.
9. Wistrom J, et al. "Frequency of antibiotic-associated diarrhea in 2462 antibiotic treated hospitalized patients: a prospective study". *Journal of Antimicrobial Chemotherapy* 47.1 (2001): 43-50.
10. Poutanen SM and Simor AE. "*Clostridium difficile*- associated diarrhea in adults". *Canadian Medical Association Journal* 171.1 (2004): 51-58.

**Volume 7 Issue 8 August 2020**

**© All rights reserved by Marlene Raimunda Andreola Perazzoli, et al.**