

## Iatrogenic Anal Leukoplakia

**GK Bennani\*, I Benelbarhdadi, M Borahma, N Lagdali, K Berhili and FZ Ajana**

*Department of Diseases of the Digestive System, Medicine C, CHU IBN SINA-Souissi Med University V, Rabat, Morocco*

**\*Corresponding Author:** GK Bennani, Department of Diseases of the Digestive System, Medicine C, CHU IBN SINA- Souissi Med University V, Rabat, Morocco.

**Received:** March 16, 2020; **Published:** June 12, 2020

### Abstract

Haemorrhoidal disease is a common pathology around the world several therapeutic components are practiced like traditional treatment, we report the case of a patient who refused the instrumental treatment of her haemorrhoids and daily introduced a clove of garlic through the anus which caused her leukoplakia lesions deemed precancerous lesion.

**Keywords:** *Leukoplakia; Haemorrhoidal Disease; Garlic*

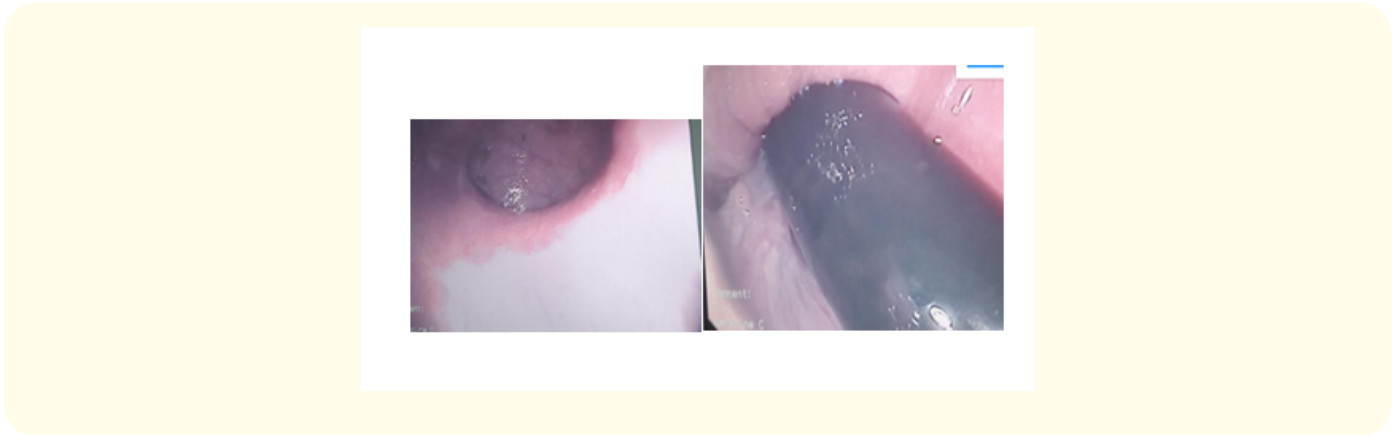
### Introduction

Hemorrhoids are vascular cushions with a thick submucosa involving the smooth muscle, connective tissues and blood vessels around the anus responsible for bleeding and protrusion of these cushions is responsible for pathologic hemorrhoids. The medicinal plants with anti-bleeding, venotonic, anti-inflammatory and antinociceptive activities may be useful for treatment of hemorrhoids but it also can be harmful to our health.

### Case Report

A 60-year-old woman was referred for continuous proctalgia and rectorrhagia associated with anemic syndrome. There was a medical history of arterial hypertension under amlodipine, no notion of anal sexual intercourse. At the rectoscopy, Haemorrhoidal disease stage II was objectified and at colonoscopy: colonic melanosis. Colon anatomopathology: non-specific chronic interstitial colitis with colonic melanosis lesions without histological signs of malignancy. The indication to the instrumental treatment was put, The patient is lost sight for 6 months during which she introduces daily in the anus a clove of garlic impregnated with olive oil or a ball of 7 mm of diameter of soap 5h to 6h per day. The patient always complains of rectorrhagia and proctalgia so she consults again; Rectoscopy: whitish smooth hemi-circumferential anal area suggestive of leukoplakia with persistent stage II internal hemorrhoids.

Anatomopathology: Anal mucosa lined on the surface by a hyperplastic squamous epithelium surmounted by an orthokeratotic corneal layer: leukoplakia Argon plasma electrocoagulation (APC) was performed on this lesion and the patient is connected to a specialized consultation for surveillance.



## Discussion

Haemorrhoidal disease is a common problem which is usually not managed properly with pharmacologic interventions and will eventually require surgery [1]. There are several plants in traditional Chinese medicine used for stopping bleeding from haemorrhoids and their efficacy has been supported by some clinical trials; but because their scientific names had not been determined in these papers and only it has been implied in their Chinese names; we could not consider them [2]. In our country the introduction of garlic inside the anus to heal haemorrhoids is a habit made by several people, this was the case of our patient but this habit did not treat haemorrhoids but on the contrary it caused a leukoplakia lesion in the anus. Leukoplakia can be classified as “precancerous lesions” when a number of them degenerate into cancer. It usually affects an elderly subject of both sexes. From a histological point of view, dysplasias of different stages associated with hyperkeratosis can be observed. Its frequency of malignant transformation remains rather low, between 4 to 6% [3].

This led us to forbid this habit to our patient and to install regular clinical and endoscopic surveillance.

## Conclusion

The treatment by medicinal plants for hemorrhoidal disease must be well codified in order to avoid an anarchic practice by the population including the use of garlic.

## Bibliography

1. Hep A., *et al.* “Treatment of hemorrhoids from the viewpoint of the gastroenterologist. Personal experience with the Ginkor Fort preparation”. *Vnitřní Lekarství* 46.5 (2000): 282-285.
2. Gan T., *et al.* “Traditional Chinese medicine herbs for stopping bleeding from haemorrhoids”. *Cochrane Database of Systematic Reviews* 10 (2010): CD006791.
3. Grajewski S and Groneberg D. “Leukoplakia and erythroplakia--two orale precursor lesions”. *Laryngorhinootologie* 88.10 (2009): 666-672.

**Volume 7 Issue 7 July 2020**

**©All rights reserved by GK Bennani., *et al.***