

Isolated Appendiceal Endometriosis, a Rare Cause of a Common Disease

Catarina Moura*, Maria Inês Leite and Armando Medeiros

General Surgery Department, Hospital do Divino Espírito Santo de Ponta Delgada, EPE, Ponta Delgada, Portugal

*Corresponding Author: Catarina Moura, General Surgery Department, Hospital do Divino Espírito Santo de Ponta Delgada, EPE, Ponta Delgada, Portugal.

Received: May 11, 2020; Published: May 29, 2020

Abstract

Endometriosis of the appendix is a rare condition that may have several manifestations, including acute appendicitis, accounting for only 3% of cases. Although rare, its preoperative diagnosis is difficult and should always be included in the differential diagnosis of acute abdomen, especially among women of childbearing age.

This article aims to carry out a literature review on endometriosis of the appendix as well as to present a clinical case.

Keywords: Appendix; Appendicitis; Endometriosis; Peritonitis; Acute Abdomen

Introduction

Acute appendicitis is one of the most frequent diagnoses for acute abdomen. From a pathophysiological perspective, it is due to the occlusion of the appendiceal lumen, usually by lymphoid tissue or fecalite; however, other less common causes may be responsible for this condition, namely endometriosis, with an incidence of 3% [1].

Endometriosis is defined as the presence of glands and endometrial stroma outside the uterine cavity. It is estimated to affect about 4 - 50% of women of childbearing age, being associated with pelvic pain and infertility in about 50% of these patients [2].

Concerning its pathophysiology, the cause is still unknown. Nonetheless, there are several proposed theories: implantation or retrograde menstruation theory, according to which endometrial cells flow back through the fallopian tubes; direct transplantation and dissemination theory, which explains extra-pelvic endometriosis; coelomic metaplasia theory, which is based on the fact that the peritoneal cavity contains progenitor cells capable of differentiating into endometrial cells; induction theory, wherein the shedding endometrium produces substances causing endometriosis; embryonic rest theory, wherein a specific stimulus induces a Mullerian origin cell nest to produce endometriosis; cellular immunity theory, which suggests that changes in humoral or cellular immunity promote the proliferation of ectopic endometrial cells [3].

Endometriosis is a benign condition that can be classified into 2 forms, internal and external, depending on whether or not it is confined to the uterine muscles, respectively [4]. It is usually found in female genital organs and pelvic peritoneum; however, it may also occur in the gastrointestinal tract, greater omentum, surgical scars, mesentery, and even in the kidney, lung, skin and nasal cavity [4,5]. The involvement of the gastrointestinal system occurs in about 3 - 37%, but appendiceal endometriosis accounts for only 3% of these cases, representing only 1% of all endometriosis cases [5].

Appendiceal endometriosis was first described in 1860 by Von-Rokitansky and since then several cases have been described; they can be classified as primary or secondary. It is primary when there is histopathological evidence of endometriosis at appendiceal level without extra-appendiceal involvement and secondary when combined with internal or external endometriosis [6,7].

Appendiceal endometriosis may occur not only as acute or chronic appendicitis, but also as recurrent pelvic pain, lower gastrointestinal bleeding, intestinal intussusception, perforation or it may be even asymptomatic [7].

In the case of acute appendicitis, inflammation of the appendix may be due to partial or complete occlusion by an endometrioma. Another proposed mechanism is that bleeding in the seromuscular layer may lead to edema, obstruction and inflammation [8].

Differential diagnosis comprises all differential diagnoses of appendicitis in general and the diagnostic study follows the same principles, although no test can give a definitive preoperative diagnosis of appendiceal endometriosis [3].

Occasionally, there may be a history of recurrent right lower quadrant pain or a previous diagnosis of endometriosis; however, this corresponds to only 41% of cases [4].

In the case of acute appendicitis, management involves appendectomy. The diagnosis may be suspected during laparotomy/laparoscopy through the visualization of intestinal implants, usually bluish-black, resulting from hemosiderin deposition, with varying degrees of pigmentation and circumscribed fibrosis. However, these implants may be very subtle or even nonpigmented lesions [7].

Anatomopathological examination is of paramount importance in the definitive diagnosis and consists of the identification of stroma and endometrial glandular tissue in the appendix, usually at muscular or seromuscular level in most cases, as the mucosa is usually unaffected. In about 50% of cases, it affects the body of the appendix and the tip in the remaining 50% [8,9].

The course of action after this finding depends on the patient's symptoms. Many women are asymptomatic and this diagnosis is a finding. If no other focus is found, it is not necessary to complement another type of therapy, which does not exclude follow-up after surgery and gynecological evaluation. However, symptomatic cases and with extra-appendiceal endometriosis require medication, namely with hormonal therapy [4].

Case Description

We present a 47-year-old female patient with history of chronic Gastritis, Depressive and Anxiety disorder, who was admitted to the emergency department due to abdominal pain with 4 days of evolution, initially diffuse, with later migration to the right iliac fossa. On admission, the patient was febrile, hemodynamically stable, with pain and tenderness on palpation of the right iliac fossa and signs of peritoneal irritation. Blood work showed high inflammatory parameters. An abdominal ultrasound was performed, showing free fluid in the peritoneal recesses, relatively heterogeneous, especially in the pelvic cavity.

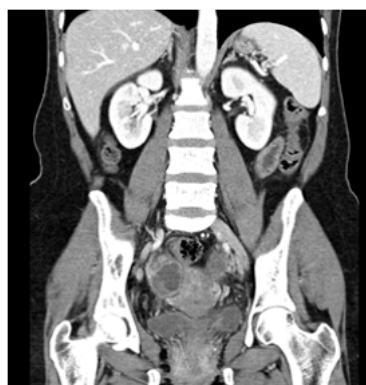

Figure 1: Abdominal CT scan - organized and heterogeneous peritoneal fluid in the pelvic cavity and a thickened appendix (14 mm) associated with fluid collection..

An abdominal pelvic CT-scan identified organized and heterogeneous peritoneal fluid in the pelvic cavity and a thickened appendix associated with fluid collection, which was compatible with complicated appendicitis.

The patient underwent exploratory laparoscopy, during which phlegmonous appendicitis and purulent peritonitis were found. Adhesive lysis, appendectomy, washing and drainage were subsequently performed. The postoperative period registered no interoccurrence, maintaining piperacillin-tazobactam antibiotic therapy, and patient was discharged clinically well on the 4th postoperative day. The anatomopathological examination of the specimen demonstrated multiple foci consisting of endometrial glands immersed in endometrial stroma in the appendix, compatible with endometriosis of the appendix.

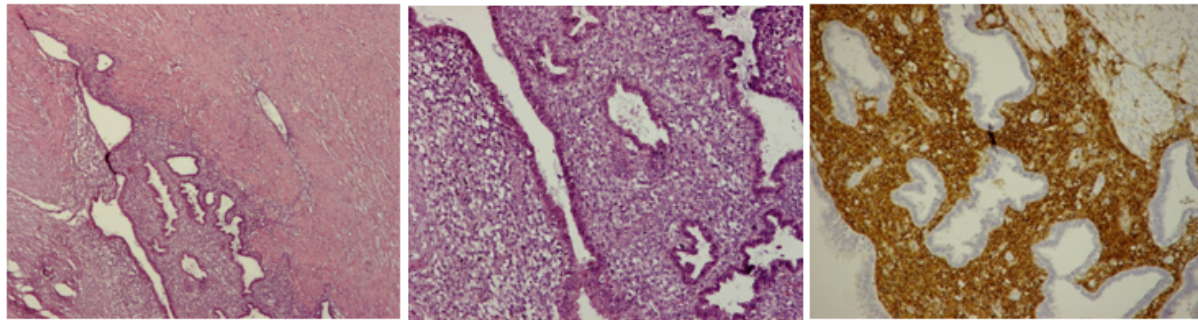


Figure 2: A irregular thick appendiceal muscular propria layer show a focus of endometrial glands embedded with stromal cells. In the right, CD10 immunoexpression in periglandular stromal cells.

Discussion

This is a case of isolated appendiceal endometriosis, a rare situation in the literature, whose clinical manifestation resulted in acute appendicitis. Previously, there has never been any symptom conducive to this diagnosis. As described by many authors, the preoperative diagnosis in such cases is very difficult. Even during surgery, there was no evidence that another diagnosis was to be considered, which was made after anatomopathological examination. In the postoperative reevaluation, the patient was clinically well without complaints, and therefore follow-up was maintained.

Conclusion

In sum, acute appendicitis is one of the most common causes of acute abdomen as appendectomy is one of the most frequent surgical interventions. However, in a small percentage of cases there are other causes for this condition, with appendiceal endometriosis accounting for only 3% of cases. Although rare, its preoperative diagnosis is difficult, but should be included in the differential diagnosis of acute abdomen, especially among women of childbearing age.

Conflict of Interest

None.

Bibliography

1. Akbulut S., *et al.* "Unusual histopathological findings in appendectomy specimens: a retrospective analysis and literature review". *World Journal of Gastroenterology* 17.15 (2011): 1961-1970.
2. Olive DL and Schwartz LB. "Endometriosis". *New England Journal of Medicine* 328 (1993): 1759-1769.
3. Yoon J., *et al.* "Endometriosis of the appendix". *Annals of Surgical Treatment and Research* 87.3 (2014): 144-147.
4. Douglas C and Rotimi O. "Extragenital endometriosis - a clinic-pathological review of a Glasgow hospital experience with case illustrations". *Journal of Obstetrics and Gynaecology* 24.7 (2004): 804-808.
5. Macafee CH and Gree HL. "Intestinal endometriosis. A report of 29 cases and a survey of the literature". *Journal of Obstetrics and Gynaecology of the British Empire* 67 (1960): 539-555.
6. Von Rokitsansky C. "Ueber Uterusdrusen_Neubildung in Uterus - und Ovarial-Sarcomen". *Ztschr kk Gesselsh Aerzte Wien* 16 (1860): 577.
7. Emre A., *et al.* "An unusual cause of acute appendicitis: Appendiceal endometriosis". *International Journal of Surgery Case Reports* 4.1 (2013): 54-57.
8. Uncu H and Taner D. "Appendiceal endometriosis: two case reports". *Archives of Gynecology and Obstetrics* 278.3 (2008): 273-275.
9. Laskou S., *et al.* "Acute appendicitis caused by endometriosis: a case report". *Medical Case Reports* 5.1 (2011): 144.

Volume 7 Issue 6 June 2020

©All rights reserved by Catarina Moura., *et al.*