

Massive Small Intestine Diverticular Disease

José Alberto Martínez Valdes^{1*}, Morelos Adolfo García Sánchez², Juan Manuel Tierrafría Valle¹, Alberto Uriel Garnica Rosales¹, Luis Andrés Sáenz Romero¹, Mireya de la Fuente González³, Alan Roberto Vázquez Rebollo¹, Ana Isabel Rodríguez Venegas¹, Daniel Ramírez León¹, Héctor Armando Miranda Blasnich¹, Roxana Islas Mendoza¹, Yabin Javier Soto García¹, Jorge Armando Gutiérrez Macías¹ and Christopher Jairo Rubio Alvarez¹

¹General Surgeon, Surgical Department at "Dr. Rubén Leñero" General Hospital Secretary of Health of Mexico City, National Autonomous University of Mexico, Mexico City, Mexico

²Colonic and Rectal Surgeon and General Surgeon, Surgical Department at "Dr. Gaudencio Gonzalez Garza" General Hospital Specialized Medical Unit, "La Raza", National Medical Center, Mexican Social Security Institute, National Autonomous University of Mexico, Mexico City, Mexico

³General Surgeon, Surgical Department at "Dr. Gaudencio Gonzalez Garza" General Hospital Specialized Medical Unit, "La Raza", National Medical Center, Mexican Social Security Institute, National Autonomous University of Mexico, Mexico City, Mexico

***Corresponding Author:** José Alberto Martínez Valdes, General Surgeon, Surgical Department at "Dr. Rubén Leñero" General Hospital Secretary of Health of Mexico City, National Autonomous University of Mexico, Mexico City, Mexico.

Received: May 03, 2020; **Published:** May 29, 2020

Abstract

Introduction: Small intestine diverticular disease is a rare pathology with an incidence of 0.2%; more frequent in patients ranging between 60 and 70 years of age. Caused by a protrusion of the mucosa and submucosa of the small intestine through its muscular layer. These types of diverticula are usually multiple, and they appear at the mesenteric border.

Purpose: Submission of a clinical case to the surgical community.

Results and Discussion: Small intestine diverticular disease is a rare pathology with an incidence of 0.2%; more frequent in patients ranging between 60 and 70 years of age. Caused by a protrusion of the mucosa and submucosa of the small intestine through its muscular layer. These types of diverticula are usually multiple, and they appear at the mesenteric border.

A probable cause for this pathology is the motor dysfunction of the smooth muscle or the myenteric plexus in the small intestine. In general, this pathology is usually asymptomatic, unless some sort of complication occurs.

A conservative treatment based on fasting and systemic antibiotics has been provided for those patients who are clinically and hemodynamically stable and have uncomplicated diverticular disease. However, the surgical treatment of small intestine diverticula has shown good results.

Conclusion: It is a clinical entity still truly unknown by the medical community and currently, there is no specific bibliographic support in the world's research literature; it is indeed extremely rare.

Its clinical features are unknown. There is no clear etiology, nor a standardized or established management. Its operative findings result mainly from imaging tests carried out with no suspected condition, or during the intraoperative period of unrelated surgical pathologies. Thus, the relevance of presenting this case and gain knowledge of its existence.

Keywords: Diverticular Disease; Diverticula; Diverticulitis; Jejunum; Ileum; Mucosa; Submucosa

Introduction

Small intestine diverticular disease is a rare pathology with an incidence of 0.2%; more frequent in patients ranging between 60 and 70 years of age. Caused by a protrusion of the mucosa and submucosa of the small intestine through its muscular layer. This is called a false diverticulum that makes a difference with the true diverticulum since they contain all the histological layers of the intestine.

Purpose of the Study

Submission of a clinical case to the surgical community.

Case Report

A 62-year-old female with a significant pathological personal history, two caesarean sections, uncontrolled diabetes mellitus and controlled hypertension, who checks in at the emergency room of the Dr. Rubén Leñero General Hospital of the Mexico City Ministry of Health, with intense colic-type abdominal pain that started 3 days before in the epigastrium and that irradiated in 24 hours and fixed in the right iliac fossa, concomitant with nausea, emesis, and hyporexia, unquantified fever, asthenia and adynamia. Physical examination revealed painful facies, abdomen with pain at McBurney, Lanz and Morris points. With overt rebound and peritoneal irritation presence. Laboratory tests show Leukocytosis of 16,000, Neutrophilia 80%, Hemoglobin 15 gr/dL, Platelets 349,000, Glucose 249 mg/dL; abdominal plain x-ray in standing position and lying down shows dilation of the intestinal loops, a fixed loop located in the right iliac fossa, multiple hydro-aerial levels, effacement of the right sacroiliac joint, which are indirect radiological signs of appendicular pathology, 14 points according to the Ripasa score, so emergency surgical management is decided, performing exploratory laparotomy finding abscessed acute appendicitis. Appendectomy is performed following the Pouchet procedure. As surgery continues, a massive diverticular disease of the entire small intestine is found by intraoperative finding, without any apparent complication, the entire extension of the disease is reviewed, ranging from a fixed loop or ligament of Treitz to the ileocecal valve, colon with no diverticulum in its entire length (Figure 1-3); wall closure is performed regularly and the procedure is completed. Subsequently, the patient is moved to the general surgery floor for postoperative management, where she progresses satisfactorily, passing gas, presenting bowel movements, tolerating oral route, therefore she was discharged and sent home in the following 48 hours. With subsequent control in the outpatient surgery.

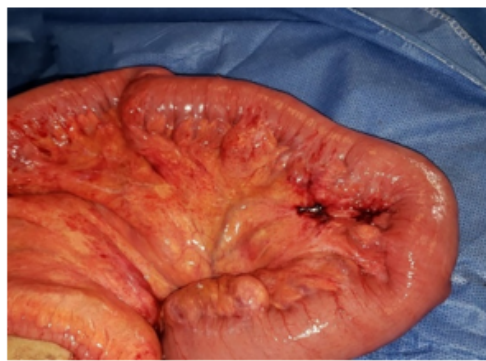


Figure 1

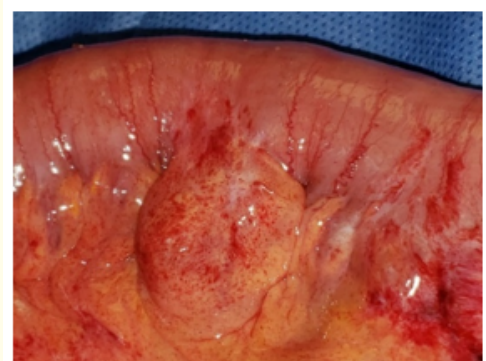

Figure 2

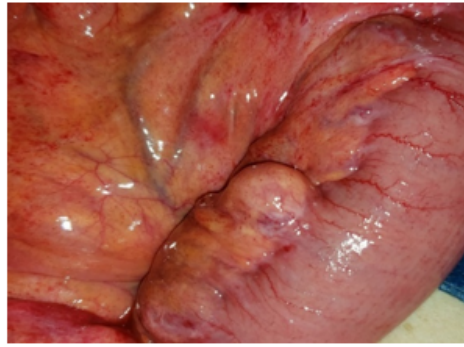

Figure 3

Discussion

In 1932 Andreas Christ reported a rare and unusual disease, namely jejunal diverticulosis [1]. In 1983, Krishnamurthy defined a small bowel diverticulum as a heterogeneous disorder caused by various smooth muscle or myenteric plexus disorders [2].

The origin of the acquired diverticulum of the small intestine has not yet been conclusively clarified [3]. The probable cause of this pathology is motor dysfunction of the smooth muscle or myenteric plexus in the small intestine, which leads to small intestine motor dysfunction with consequential bacterial overgrowth.

Small intestine diverticular disease is a rare pathology with an incidence of 0.2%; more frequent in patients ranging between 60 and 70 years of age. Which is caused by a protrusion of the mucosa and submucosa of the small intestine through its muscular layer. These types of diverticula are usually multiple, and they appear at the mesenteric border; however, complication rate is low. Most cases are discovered incidentally during radiological investigations [4].

In general, this pathology is usually asymptomatic, unless it occurs as some type of complication such as diverticulitis, diverticular bleeding secondary to intestinal perforation or occlusion; however, these complications can be mistaken for pathologies such as acute appendicitis, acute cholecystitis, or even colonic diverticulitis.

Among the most frequent complications of this pathology is acute diverticulitis; its typical presentation involves the jejunum and is often not severe. Followed by diverticular bleeding, which is the second most common complication [5]. Intestinal occlusion occurs in 2 to 5% of jejunoileal diverticulosis cases, being the most frequent complication of jejunal diverticula which require surgical management.

Among the diagnostic methods, we find various imaging studies, of which the Abdominal Computed Tomography (CT scan) is the preferred test to determine the site and number of diverticula located in the small intestine.

Abdominal ultrasound is typically hampered by intestinal gas along with the intraperitoneal inflammatory process. Therefore, it is not a useful tool to diagnose jejunal diverticula.

Abdominal Computed Tomography is currently considered the gold standard for the diagnosis of jejunal diverticula, as well as for their complications. During the CT scan, jejunal diverticula may appear as a focal and asymmetric thickening of the intestinal wall or an

abscess adjacent to a jejunal loop with edema of peridiverticular fat. In addition, the “arrowhead-shaped contrast collection” sign, which is a nonspecific sign of jejunal diverticula, can be identified. Pneumoperitoneum is usually a radiological sign of perforation. However, patients with jejunal diverticulosis can develop chronic pneumoperitoneum without peritonitis or previous surgery. Two pathophysiological mechanisms are suggested: micro perforation of the diverticulum and passing air through the semipermeable membrane of the thin wall of the diverticulum [11].

Magnetic resonance enterography is increasingly being used to assess small intestine diverticular disease; however, its use is limited due to the lack of resources within governmental health institutions [7].

Perforation of small bowel diverticula can be fatal due to delayed diagnosis [6].

Currently, those patients who are clinically and hemodynamically stable and have uncomplicated diverticular disease have conservative treatment based on fasting and systemic antibiotics. However, there are authors who consider performing intestinal resection of the affected area in order to prevent recurrence and complications [8].

Surgery is mandatory when complications such as bleeding or diverticular perforation occur. The immediate anastomosis should be performed whenever the general conditions of the patient allow it. Otherwise, jejunostomy is the preferred management for high-risk patients [8].

In case of massive or extensive jejunal diverticulosis, the intestinal resection should be limited to the intestinal loop where the perforated diverticulum is located in order to avoid short bowel syndrome [9]. Asymptomatic diverticula resulting from an imaging finding during the intraoperative period do not require surgical management. However, in order to avoid complications, intestinal resection is mandatory in cases where diverticula are large with dilated intestinal loops.

In general, surgical treatment of small bowel diverticula has good results. With a mortality rate of 0 to 5%; however, in cases of perforation, mortality can increase up to 40% [10-14].

Conclusion

This clinical entity is still truly unknown by the medical community and currently, there is no specific bibliographic support in the world's research literature; it is indeed extremely rare. Its clinical features are nonspecific, its diagnostic suspicion is practically nonexistent.

There is no clear etiology, nor a standardized or established management. Its finding in the surgical procedure confirmed its existence. Hence the importance of presenting this case.

Bibliography

1. Christ A. “Multiple Diverticula of the Jejunum”. *Langenbeck's Archives of Surgery* 236 (1932): 560-570.
2. Silvia Navarro Moya and José Miguel Ramírez Valverde. “Divertículos en yeyuno”. *Revista Clínica de la Escuela de Medicina UCR - HSJD* 6.2 (2016).
3. Peters R., *et al.* “Perforated jejunal diverticulitis as a rare cause of acute abdomen”. *European Radiology* 9 (1999): 1426-1428.
4. Ceuppens A-S., *et al.* “Jejuno-ileal diverticulosis: a review of literature”. *Acta Gastro-Enterologica Belgica* 81.4 (2018): 517-519.

5. Lebert P, *et al.* "Acquired diverticular disease of the jejunum and ileum: imaging features and pitfalls". *Abdominal Radiology* 44.8 (2019):1734-1743.
6. Kassir R, *et al.* "Jejuno-ileal diverticulitis: Etiopathogenicity, diagnosis and management". *International Journal of Surgery Case Reports* 10 (2015): 151-153.
7. Bahar Mansoori, *et al.* "Magnetic resonance enterography/enteroclysis in acquired small bowel diverticulitis and small bowel diverticulosis". *European Radiology* 26.9 (2016): 2881-2891.
8. Kassahun WT, *et al.* "Complicated small bowel diverticulosis: a case report and review of the literature". *World Journal of Gastroenterology* 13.15 (2007): 2240-2242.
9. Harbi H, *et al.* "Jejunal diverticulitis. Review and treatment algorithm". *La Presse Médicale* 46.12 (2017): 1139-1143.
10. Kassir R, *et al.* "Jejuno-ileal diverticulitis: etiopathogenicity, diagnosis and management". *International Journal of Surgery Case Reports* 10 (2015): 151-153.
11. Kwak JY, *et al.* "Uncomplicated jejunal diverticulosis with pneumoperitoneum". *Annals of Surgical Treatment and Research* 90.6 (2016): 346-349.
12. Yilmaz E, *et al.* "Assessment of Duodenal Diverticula: Computed Tomography Findings". *Current Medical Imaging Reviews* 15.10 (2019): 948-955.
13. Chiu TC, *et al.* "Right-Sided Colonic Diverticulitis: Clinical Features, Sonographic Appearances, and Management". *Journal of Medical Ultrasound* 25.1 (2017): 33-39.
14. Ivatury RR. "Meckel's diverticulum and the eponymous legend". *Journal of Trauma and Acute Care Surgery* 87.2 (2019): 451-455.

Volume 7 Issue 6 June 2020

©All rights reserved by José Alberto Martínez Valdes., *et al.*