

A Case Report of Ectopic Pancreas in The Jejunum as a Rare Position of Heterotopic Pancreas in Children

Reema Al Ebrahim^{1*}, Eman Shhada^{1*}, Yahia Al Yaski², Hamid Alkhaled² and Lina Khouri¹

¹*Department of Gastroenterology, Children's Damascus University Hospital, Syria*

²*Department of Surgery, Children's Damascus University Hospital, Syria*

***Corresponding Author:** Reema Al Ebrahim and Eman Shhada, Department of Gastroenterology, Children's Damascus University Hospital and Department of Surgery, Children's Damascus University Hospital, Syria.

Received: January 28, 2020; **Published:** March 30, 2020

Abstract

Heterotopic Pancreas is a rare congenital malformation which pancreatic tissue was located anywhere along gastrointestinal tract (GI tract). The most location is in the upper GI tract. We report a case of 3-year old male, who admitted to evaluation acute abdominal pain 12 days ago, after that he developed bilious vomiting, hence the patient underwent emergency operative and a mass in the wall of jejunum was resected. After operative the histological examination of resected mass was established the diagnosis of heterotopic pancreas, and the patient was followed up without of any complication.

Keywords: *Heterotopic Pancreas; Abdominal Pain; Sub-Mucosa; Jejunum*

Introduction

Heterotopic pancreas is a rare congenital malformation, defined as pancreatic tissue that localizes at abnormal site along gastrointestinal tract [1]. The etiology of HP is unknown, and it's described the first time in 1727 [2,3]. The incidence of this lesion occurs between 0.5 - 13.7% on autopsy studies [4] and it can be found along gastrointestinal tract, however most cases are reported in the upper GI tract, including stomach, duodenum and jejunum [5-7], however the incidence of ectopic pancreas in the jejunum is (15.9%) [9,12] and the main located in sub mucosa and muscular layer (in 23% of cases) [2].

HP is usually asymptomatic, but it may present clinically as bleeding, obstruction and malignant transformation [10,11], also the severity of symptom depends on lesion size and site [1]. The most common presentation is abdominal pain. The diagnosis of HP was established by histological examination after surgical excision.

Case Presentation and Discussion

A 3-year old boy with no significant medical history, normal growth and development was admitted to our department with colic abdominal pain, diarrhea and vomiting 12 days ago. Within the last 2 days prior to admission to our hospital, the patient had two episodes of bilious vomiting and dark black tarry feces. On examination, the patient was stable, feeling pain and pale. His temperature was 37, heart rate was 120 beats/min, and the blood pressure was 98/65.

The abdomen was tender with sign of peritoneal irritation. Digital rectal examination revealed no markable sign.

The laboratory tests showed elevated white blood cells (WBC = 20000, N = 76%), Hemoglobin was 11g/dl, elevated CRP (CRP: 27, normal up to 5) Other blood tests including ESR,GPT, Wright, Widal, Amylase and Lipase were normal. Occult Blood in stool was Positive. Urinalysis was normal. The radiographic investigation showed: Abdominal X Ray was unremarkable and showed abnormal gases distribution in the abdomen (Figure 1). Abdominal ultrasonography and Contrast-enhanced computed tomography of the abdomen were performed, the imaging findings included thickening of the involved bowel wall and surrounding inflammation, inflammatory nodes and suspected ileoileal intussusception was found in the right lower abdomen with a diameter of 2.5 cm.

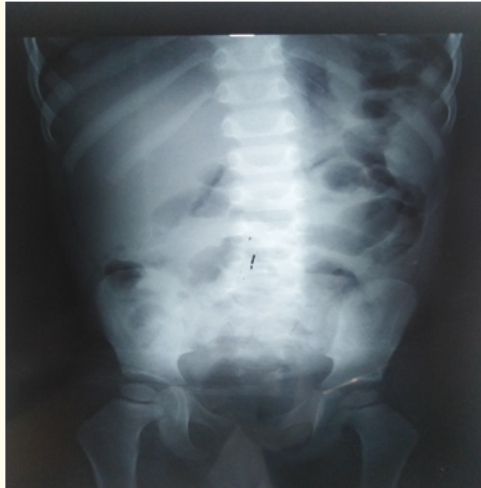

Figure 1: Abdominal X Ray show abnormal gas distribution and intestinal dilation.

The patient underwent to exploratory laparotomy. laparotomy revealed a yellowish mass measuring 1.5 cm located at the antimesenteric wall of the jejunum, about 15 cm from the ligament of treitz (Figure 2). The mass was resected, eventually an end-to-end anastomosis was performed. Postoperative course was uneventful; histopathologic examination of the resected specimen revealed ectopic pancreatic tissue consisting of acini, islet cells, and pancreatic ducts located in the sub-mucosal layer and extend to the muscular layer with obvious border (Figure 3).

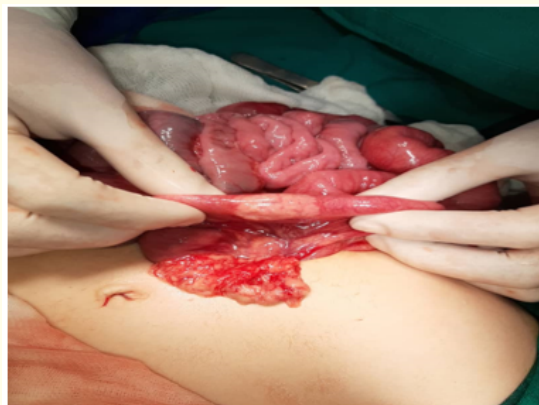

Figure 2: Photograph of the yellowish mass measuring 1.5 cm located at the antimesenteric wall of the jejunum.

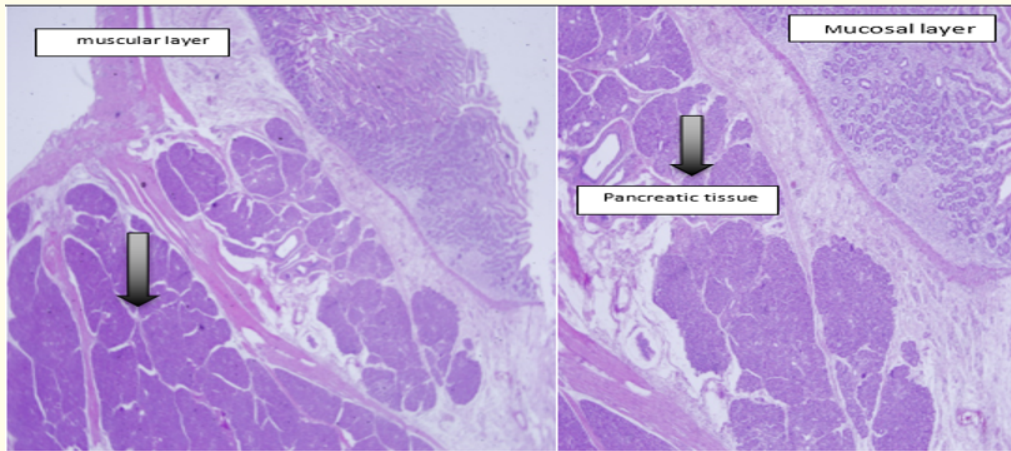


Figure 3

There was no evidence of malignant change in the ectopic pancreatic tissue. The pathologic diagnosis was Ectopic Pancreas. The patient was discharged from the hospital in good state. By follow-up of the patient for 4 mo postoperatively showed no evidence of any complication or relapse.

Discussion

HP is a rare congenital malformation (the incidence of HP between 0.5 and 13.7% of the whole cases) [1,4]. The first reported was in 1727 [2,3].

HP may be found anywhere along the gastrointestinal tract, and the most cases showed that stomach is the most common site (25 - 47%), however in our case, ectopic pancreas was found in jejunum (15 - 35% of cases in the medical literature) [1,2,8,9] and the ectopic pancreas was located sub-mucosa and extended to muscular layer as same as most studies (23% of cases) [2]. HP is typically asymptomatic but it may be present clinically when it's complicated, so it may present as bleeding, intussusception, obstruction and malignant transformation, our patient is admitted with obstructive manifestation as a result of intussusception. Intussusception owing to heterotopic pancreas as a lead point is very unusual in children; roughly 20 reports were published until 2011 [7]. Because of nonspecific manifestation, the confirmed diagnosis is established postoperatively, so our patient underwent to exploratory laparotomy and the resected mass is sent to histological examination which confirmed diagnosis. According to medical literature the severity of symptoms depends on the size of lesion, hence our patients mass was larger than 1,5 cm, so it's associated with evident symptoms.

Conclusion

Heterotopic pancreas is a rare congenital anomaly, and it's difficult to distinguish it clinically, and present when it's complicated, so HP should be consider as a differential diagnosis when one of its complications present.

Bibliography

1. Barbosa JJ., et al. "Pancreatic heterotopia review of the literature and report of 41 authenticated surgical cases, of which 25 were clinically significant". *Surgery, Gynecology and Obstetrics* 82 (1946): 527-542.
2. Ginsburg M., et al. "Ectopic pancreas presenting with pancreatitis and a mesenteric mass". *Journal of Pediatric Surgery* 48.1 (2013): e29-e32.

3. Kung JW, *et al.* "Heterotopic pancreas: typical and atypical imaging findings". *Clinical Radiology* 65.5 (2010): 403-407.
4. Wei R, *et al.* "Upper gastrointestinal tract heterotopic pancreas: findings from CT and endoscopic imaging with histopathologic correlation". *Clinical Imaging* 35.5 (2011): 353-359.
5. Sandrasegaran K, *et al.* "Heterotopic pancreas: presentation as jejunal tumor". *American Journal of Roentgenology* 187.6 (2006): W607-W609.
6. Borghei P, *et al.* "Anomalies, anatomic variants, and sources of diagnostic pitfalls in pancreatic imaging". *Radiology* 266.1 (2013): 28-36.
7. Ulrych J, *et al.* "Premalignant and malignant lesions of the heterotopic pancreas in the esophagus: a case report and review of the literature". *Journal of Gastrointestinal and Liver Diseases* 24.2 (2015): 235-239.
8. Trifan A, *et al.* "Gastric heterotopic pancreas: an unusual case and review of the literature". *Journal of Gastrointestinal and Liver Diseases* 21.2 (2012): 209-212.
9. Kilman WJ and Berk RN. "The spectrum of radiographic features of aberrant pancreatic rests involving the stomach". *Radiology* 123.2 (1977): 291-296.
10. Mack T, *et al.* "Multimodality imaging evaluation of an uncommon entity: esophageal heterotopic pancreas". *Case Reports in Radiology* (2014): 614347.
11. Shanbhogue AK, *et al.* "A clinical and radiologic review of uncommon types and causes of pancreatitis". *RadioGraphics* 29.4 (2009): 1003-1026.
12. Lee NK, *et al.* "Hypervascular subepithelial gastrointestinal masses: CT-pathologic correlation". *RadioGraphics* 30.7 (2010): 1915-1934.

Volume 7 Issue 4 April 2020

©All rights reserved by Reema Al Ebrahim, Eman Shhada and Hamid Alkhaled., *et al.*