

Eosinophilic Gastroenteritis

Mohamed Zakaria*

Specialist Gastroenterologist at Medeor 24x7, Dubai, UAE

***Corresponding Author:** Mohamed Zakaria, Specialist Gastroenterologist at Medeor 24x7, Dubai, UAE.

Received: June 26, 2019; **Published:** September 06, 2019

Abstract

Introduction: Eosinophilic gastroenteritis (EGE) is an uncommon inflammatory gastrointestinal disease affecting both children and adults. This condition is characterized by eosinophilic infiltration of the GI tract, with about 20 or more eosinophils per high-power field and its presented by abdominal pain, nausea, vomiting, diarrhea, and weight loss and in most of the cases there is no identified cause of the high eosinophilia.

Case Presentation: Female patient, about 61 yrs. old, complaining of recurrent epigastric pain, acidity with heart burn for the past 4 months and associated recently with nausea and vomiting, the symptoms were intermittent with mild to moderate degree of severity, her bowels were regular, she was given PPIs (mainly esomeprazole and dexlansoprazole) on different occasions without any improvement, an upper endoscopy was advised which showed small flat elevated antral polyps around 1 x 1.5 mm each with the duodenum showing short villi, and the oesophagus showed only mild sliding hiatus hernia with no signs of reflux, biopsies were taken from the stomach and duodenum, histopathology results showed eosinophilic gastritis with moderate glandular hypertrophy, intestinal metaplasia and hyperplastic polyps. Advice was given to avoid main 6 food elements (milk products, eggs, wheat, soy, peanuts and fish). Patient symptoms declined dramatically after 2 weeks and her follow up clinic visits showed no any specific complaints nor symptoms.

Discussion: Eosinophilic gastroenteritis is an uncommon inflammatory gastrointestinal disease affecting both children and adults. This condition is characterized by eosinophilic infiltration of the GI tract, with about 20 or more eosinophils per high-power field, it's presented by abdominal pain, nausea, vomiting, diarrhea, and weight loss with no identified cause of eosinophilia.

Conclusion: Persistent upper GI symptoms not responding to PPI requires upper endoscopy to exclude other histologically found diseases as eosinophilic gastroenteritis which requires only avoidance of some food elements.

Keywords: *Eosinophilic Gastroenteritis (EGE); GI Tract*

Introduction

Eosinophilic gastroenteritis (EGE) is an uncommon inflammatory gastrointestinal disease affecting both children and adults. This condition is characterized by eosinophilic infiltration of the GI tract, with about 20 or more eosinophils per high-power field and its presented by abdominal pain, nausea, vomiting, diarrhea, and weight loss and in most of the cases there is no identified cause of the high eosinophilia.

Case Report

Female patient, widow, has 2 offsprings, about 61 yrs. old, her height was 153.5 cm, her weight 68 kg, her BMI 29 kg/m², and she was vitally stable, she was complaining of recurrent epigastric pain, acidity with heart burn for the past 4 months and associated recently with nausea and vomiting, the symptoms were intermittent with mild to moderate degree of severity but starting to affect her regular daily activity recently, her bowels were regular, her past history is positive for type 2 diabetes mellitus which was controlled on low dose of metformin and her family history is irrelevant, she was seen by many centers before and was advised and given PPIs (mainly esomeprazole and dexlansoprazole) on different occasions without any improvement, some courses were given for a period of 2 - 4 weeks, on examination generally no pallor, no jaundice with no lower limb edema and no lymph node enlargement, her abdomen showed mild and periumbilical tenderness, other systems (heart, chest and neurological) were unremarkable, investigations were done in my facility (chemistry panel was normal and abdominal USG also was normal), an upper endoscopy was advised which was done under light to moderate sedation which showed small flat elevated antral polyps around 1 x 1.5 mm each with the duodenum showing short villi, and the oesophagus showed only mild sliding hiatus hernia with no signs of reflux, biopsies were taken from the stomach and duodenum, and the provisional gross diagnosis was gastroduodenitis pending histopathology results which showed eosinophilic gastritis with moderate glandular hypertrophy, intestinal metaplasia and hyperplastic polyps. Advice was given to avoid main 6 food elements (milk products, eggs, wheat, soy, peanuts and fish). Patient symptoms declined dramatically after 2 weeks and her follow up clinic visits showed no any specific complaints nor symptoms with increase in mood changes and daily activity.

Discussion and Conclusion

Eosinophilic gastroenteritis (EGE) is an uncommon inflammatory gastrointestinal (GI) disease affecting both children and adults. This condition is characterized by the following:

- Eosinophilic infiltration of the GI tract, with about 20 or more eosinophils per high-power field (HPF).
- Its presented by abdominal pain, nausea, vomiting, diarrhea, and weight loss.
- No identified cause of eosinophilia.

Laboratory studies

General workup includes a complete blood cell (CBC) count and differential. Peripheral blood eosinophilia is found in 20 - 80% of cases. Mean corpuscular volume measurements may reveal iron-deficiency anemia, and serum albumin levels may be low, especially in patients with mucosal layer involvement [1-11].

Procedures

Endoscopy and biopsy

Note the following:

- If eosinophilic gastroenteritis is suspected, you have to take at least 6 biopsy samples from the gastric antrum and duodenum [12,13].
- Grossly there is prominent mucosal folds, hyperemia, ulceration, or nodularity can be seen.

Histologic findings

Histopathology usually there is increased numbers of eosinophils (often > 50 eos per high-power field) in the lamina propria with Large numbers of eosinophils present in the muscularis and serosal layers. The localized eosinophilic infiltrates may cause crypt hyperplasia, epithelial cell necrosis, and villous atrophy [14].

Medical care

Diet

Elimination of six foods, which is milk, soy, wheat, egg, peanuts/tree nuts, and fish/shellfish are helpful.

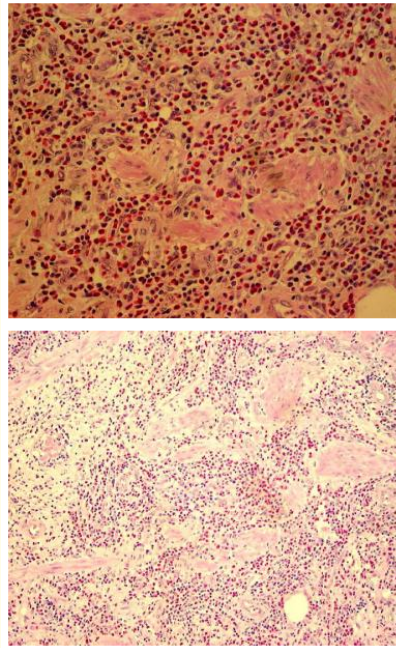


Figure 1

The absolute eosinophil count can be checked 4-6 weeks after implementation of empiric dietary treatment. A reduction of 50% in the peripheral eosinophil count can be considered a response to treatment.

Medication Summary

Oral glucocorticosteroids with anti-inflammatory properties are the primary therapy, especially for patients with obstructive symptoms and eosinophilic ascites. Most patients with eosinophilic gastroenteritis respond dramatically to oral glucocorticosteroids within 2 months. Successful treatment with other anti-inflammatory medications, such as leukotriene modifiers (e.g. montelukast), macrolides, and mast cell stabilizers (e.g. cromolyn), has been reported.

Bibliography

1. Uppal V, *et al.* "Eosinophilic gastroenteritis and colitis: a comprehensive review". *Clinical Reviews in Allergy and Immunology* 50.2 (2016): 175-188.
2. Mehta P and Furuta GT. "Eosinophils in gastrointestinal disorders: eosinophilic gastrointestinal diseases, celiac disease, inflammatory bowel diseases, and parasitic infections". *Immunology and Allergy Clinics of North America* 35.3 (2015): 413-437.
3. Ito J, *et al.* "Racial differences in eosinophilic gastrointestinal disorders among Caucasian and Asian". *Allergology International* 64.3 (2015): 253-259.
4. Kim NI, *et al.* "Clinical features of eosinophilic gastroenteritis [in Korean]". *Korean Journal of Gastroenterology* 44.4 (2004): 217-223.
5. Chen MJ, *et al.* "Eosinophilic gastroenteritis: clinical experience with 15 patients". *World Journal of Gastroenterology* 9.12 (2003): 2813-2816.

6. Savino A., *et al.* "Role of ultrasonography in the diagnosis and follow-up of pediatric eosinophilic gastroenteritis: a case report and review of the literature". *Ultraschall in der Medizin* 32.2 (2011): E57-E62.
7. Liacouras CA., *et al.* "Eosinophilic esophagitis: updated consensus recommendations for children and adults". *Journal of Allergy and Clinical Immunology* 128.1 (2011): 3-20.e6.
8. Sharaf RN., *et al.* "Endoscopic mucosal tissue sampling". *Gastrointestinal Endoscopy* 78.2 (2013): 216-224.
9. Kim YJ., *et al.* "Rebound eosinophilia after treatment of hypereosinophilic syndrome and eosinophilic gastroenteritis with monoclonal anti-IL-5 antibody SCH55700". *Journal of Allergy and Clinical Immunology* 114.6 (2004): 1449-1455.
10. Foroughi S., *et al.* "Anti-IgE treatment of eosinophil-associated gastrointestinal disorders". *Journal of Allergy and Clinical Immunology* 120.3 (2007): 594-601.
11. Phaw NA and Tsai HH. "Eosinophilic gastroenteritis: a challenge to diagnose and treat". *BMJ Case Reports* (2016).
12. Lucendo AJ., *et al.* "Efficacy of dietary treatment for inducing disease remission in eosinophilic gastroenteritis". *Journal of Pediatric Gastroenterology and Nutrition* 61.1 (2015): 56-64.
13. Prussin C. "Eosinophilic gastroenteritis and related eosinophilic disorders". *Gastroenterology Clinics of North America* 43.2 (2014): 317-327.
14. Gupta N., *et al.* "The management of eosinophilic gastroenteritis". *Scandinavian Journal of Gastroenterology* 50.11 (2015): 1309-1314.

Volume 6 Issue 10 October 2019

©All rights reserved by Mohamed Zakaria.