

Rare Cause of the Small Bowel Volvulus in a 29-Year-Old Woman

Archili Miminoshvili*

Medical center "Verum", Ukraine

***Corresponding Author:** Archili Miminoshvili, Medical center "Verum", Ukraine.

Received: July 03, 2019; **Published:** July 23, 2019

Small bowel volvulus is a pathological twisting of a small intestine loop around the axis of its own mesentery. In severe cases, it causes small bowel obstruction or necrosis of the bowel loop.

A 29-year-old woman came to the emergency department because of acute abdominal pain during the last 7 hours. Other symptoms included vomiting and abdominal tenderness.

Her history is unremarkable for previous surgery or diseases, except chronic constipation during the last 10 years. Also, she admitted periodically mucous vaginal discharge without any additional symptoms, like dysuria or frequent urination. She never was pregnant and finished her oral contraceptive pills intake 2 years ago. She denies any medical therapy, except daily laxatives.

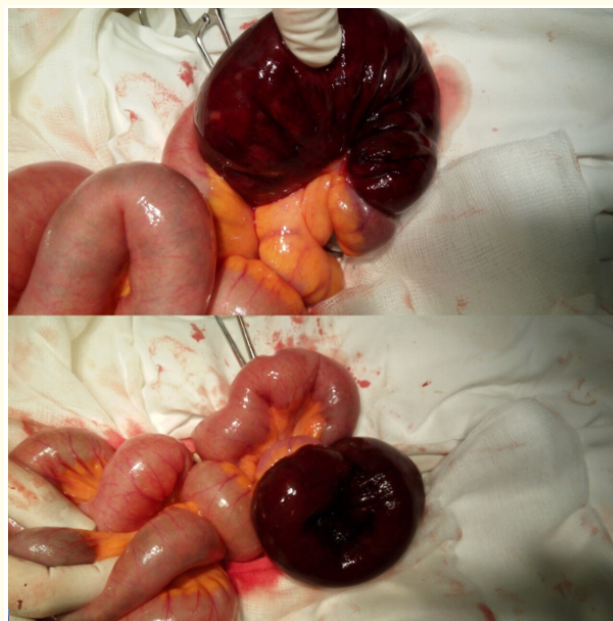
During an examination, her vital signs were stable, except moderate tachycardia. Mild distention and abdominal tenderness were revealed, peritoneal signs were negative.

All hematological investigations were within normal limits.

Ultrasound was not informative, no evidence of a pelvic mass or abscess, only a mild amount of free fluid in the pelvis.

An abdominal X-ray demonstrated some air-fluid levels - features of intestinal obstruction.

After worsening of abdominal pain laparotomy was performed. During surgical intervention, the small bowel volvulus was revealed (Figure 1) and necrosis of twisted loop was confirmed. The 20 cm segment of the ileum was resected with primary anastomosis. Discharge from the hospital on the fourth day.



Laboratory exam in postoperative period confirmed the presence of Chlamydia trachomatis and antibiotics were prescribed.

Overall, this case report demonstrates that the small bowel volvulus in a young woman may occur due to a combination of non-surgical pathologies, like chronic constipation and pelvic inflammatory disease.

Volume 6 Issue 8 August 2019

©All rights reserved by Archili Miminoshvili.