

## Late Rehabilitation of Mid Esophagus Caustic Stricture in a Six Years Old Girl

Diameter of 1 - 2 Milimeters (mm) by 4 Centimeters (cm) Length

Elizondo-Vázquez Jorge Bernardo<sup>1\*</sup>, Pérez-González Federico<sup>2</sup>, Martínez-Estrada Tomás Francisco<sup>3</sup>, Noriega-Aldana Juan Manuel<sup>3</sup> and Ibarra-Aldaco Robero<sup>3</sup>

<sup>1</sup>*Pediatric Gastroenterologist and Endoscopist, CIMA Hospital, Hermosillo and Pediatric Gastroenterologist, Internal Medicine Department, Sonora State Children's Hospital, Sonora, México*

<sup>2</sup>*Endoscopist and General Surgeon, CIMA Hospital, Hermosillo, Sonora, México*

<sup>3</sup>*Pediatric Surgeon, CIMA Hospital, Hermosillo, Sonora, México*

**\*Corresponding Author:** Elizondo-Vázquez Jorge Bernardo, Pediatric Gastroenterologist and Endoscopist, CIMA Hospital, Hermosillo, Sonora, México.

**Received:** July 12, 2018; **Published:** July 15, 2019

### Abstract

Describe late beginning (51 days after caustic ingestion) mid esophagus complicated stricture (1-2 mm diameter by 4 cm length) rehabilitation, in a six years old girl with a prolonged esophageal stricture dilation with Savary-Guilliard dilators, esophageal metallic, self-expandable, thoroughly covered, with resection of a fibrous ring with primary esophagoplasty and, again, esophageal stricture dilations after primary esophagoplasty.

**Keywords:** *Caustic Ingestion; Caustic Burns; Esophageal Stenosis; Esophageal Caustic Stenosis; Esophageal Stricture; Esophageal Caustic Stricture; Esophagus Rehabilitation; Esophageal Stricture Dilation; Savary-Guilliard Dilators; Esophagoplasty*

### Abbreviations

ASD: Autism Spectrum Disorder; SI: Superior Incisors; S-Gd: Savary-Guilliard Dilators

### Introduction

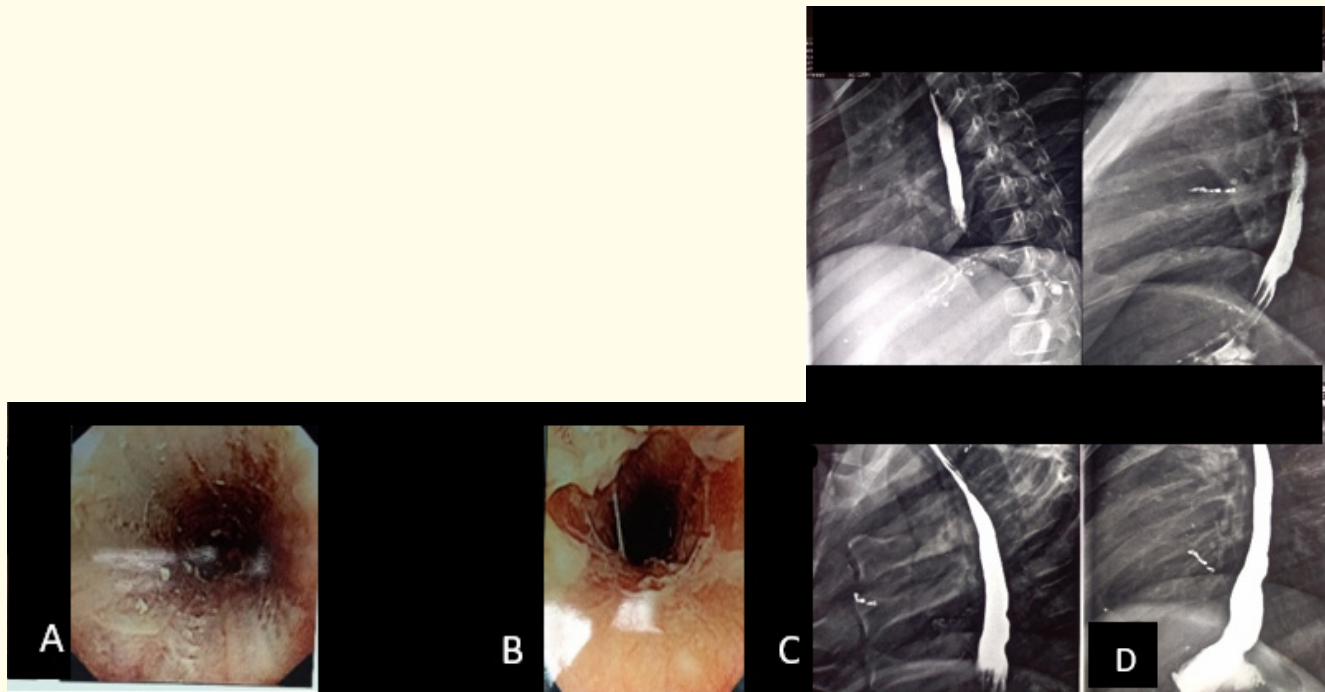
Esophageal caustic ingestion can produce severe esophageal burns and local and systemic complications; the purpose is to describe short and long term complications after liquid caustic ingestion; the significance is that, the esophageal dilation program, should not be limited by a short course of esophageal stricture dilation to consider it refractory to this treatment; it should consider parent's opinion, in this case, they refuse, for a long time, to do another treatment besides esophageal dilations. Resistance to esophageal dilations is less after esophagoplasty; esophageal lumen, after resection of a fibrous ring and primary esophagoplasty, is less than previous esophageal surgery, nevertheless, she eats more and faster and do not develop dysphagia as compare as larger lumen diameter before the surgery; so, the size of fibrous tissue (fibrous ring, previous to the surgery, is larger, as compare to scar formation after esophagoplasty), this issue influences dysphagia appearance and larger resistance to esophageal dilations previous to the surgery as compare after it, nevertheless, esophageal diameter is lower after surgery).

### Materials and Methods

This is a case report, the material that was used are Olympus endoscope of 9.8 mm, with a biopsy channel of 2.8 mm, biopsy forceps for esophageal mucosa, esophageal metallic and expandable, thoroughly covered, with anti-reflux mechanism stent, with a diameter of 20 mm, and 20 cm long, and surgical equipment for thoracotomy and primary esophagoplasty.

**Case Report**

A six-year-old girl with autism spectrum disorder (ASD), accidentally ingests liquid caustic, it was on a soda recipient, she took the recipient and drink on June-26-2017, immediately she begins with drooling and severe mouth pain. Endoscopy, in the following hours, revealed white fibrinous plates, erythema, and hemorrhage in all esophagus mucosa (Figure 1). Esophagoscopy, in the first hours, and esophagogram, 11 days after caustic ingestion.

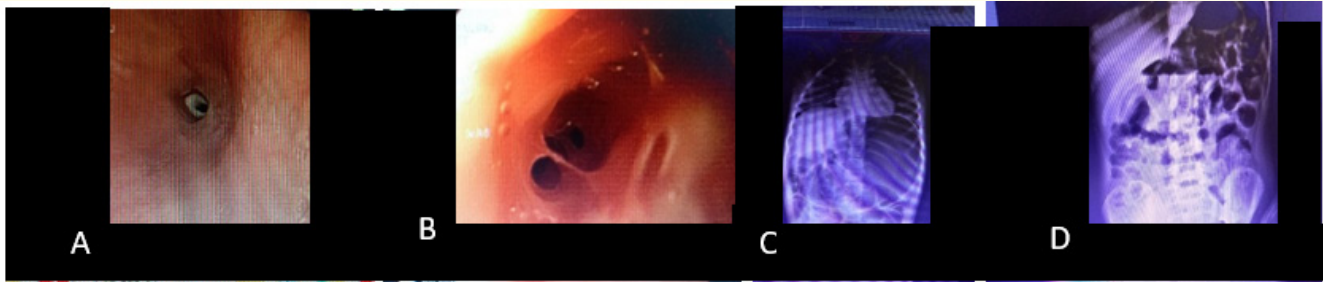


**Figure 1:** First endoscopy on June-26-17. Fibrinous plates along two thirds of the esophagus, a and b. Esophagogram on July 7-17. No evidence of esophageal stricture 11 days after liquid caustic ingestion c, d, e and f.

She was put on fast for about one week, a surgical gastrostomy was done, it was closed two weeks later. She was fed by mouth, dysphagia developed progressively, from solids to liquids, three days prior she arrived to our hospital, on August 16-2017, 51 days after liquid caustic ingestion, she had aphagia, it manifested by choking, drooling, peripheral cyanosis and weight loss.

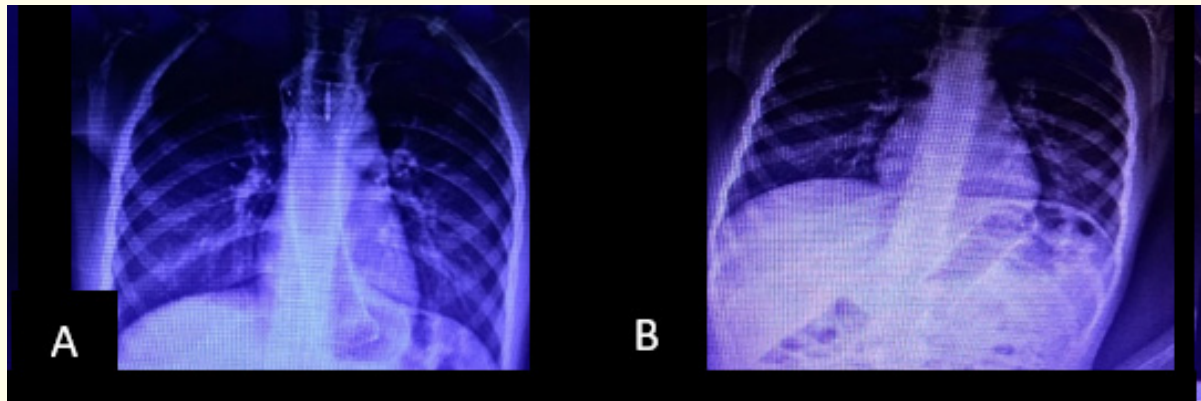
The first three esophageal stricture dilations were done in the hospital. The first endoscopy revealed, at 19 cm from superior incisors (SI), a tiny central stricture, covered by white fibrinous plates, it has a diameter of 1 - 2 mm, it can only pass the guidewire, and 5 and 7 mm Savary-Guiliard dilators (S-Gd) (Figure 2), after the first stricture dilation, she begins to eat liquids; after second and third ones, the lumen diameter arrived at 9 mm, she begins to eat solids, and was discharged from hospital.

In the first endoscopy, when only a guidewire could be passed, she developed gastric dilation, as air passed through the esophageal stenosis, but could not get out through the tiny stricture; the abdominal circumference severely increased; an abdominal X-ray revealed gastric dilation by gas, next day, gas distribution is normal (Figure 2). In the following dilations, she did not have any acute complication. In the second one, the stricture was from 19 to 23 cm from SI. The esophageal proximal and distal thirds are normal, the stricture is on the middle third.



**Figure 2:** First endoscopy in our hospital: August-16-2017. A. At 19 cm from SI is found a tiny lumen stricture of 1-2 mm diameter. B. After first dilation with Savary-Guiliard dilators (S-Gd) of five- and seven-mm. C. Dilated stomach after passage of guide wire and first esophageal dilation. D. Normal gas distribution in stomach and small bowel after 24 hours.

She is maintained, as an outpatient, on a stricture esophageal dilations program, we tried to space the esophageal dilations, since three, to two, to one per week, to every two to three weeks; but she developed dysphagia after one week. The esophageal diameter reached 18 mm, in one week, it diminished to 12 - 13 mm and, at two weeks, it diminished to 8 - 9 mm. They were maintained because the parents did not accept esophageal stenting. On March-24-2018, seven months and eight days after the first one, and after 60 dilations, the parents accepted, it was placed a metallic esophageal expandable stent, completely covered, 10 cm length and a diameter of 20 mm, with an anti-reflux mechanism. The esophageal stent is on the two distal thirds and proximal stomach (Figure 3).



**Figure 3:** A. March-24-18. Metallic expandable, thoroughly covered, esophagus stent in its correct place on esophagus. B. June-8-2018 (75 days later), esophageal stent on stomach.

She does not need another esophageal dilation while stent was located on esophagus; it remained there just a little bit more than two months. After one and a half month, she begins with dysphagia to solids which, in three weeks, progress to dysphagia to liquids, until she could not pass anything by mouth, the day before she was carried to our hospital, on June-8-2018.

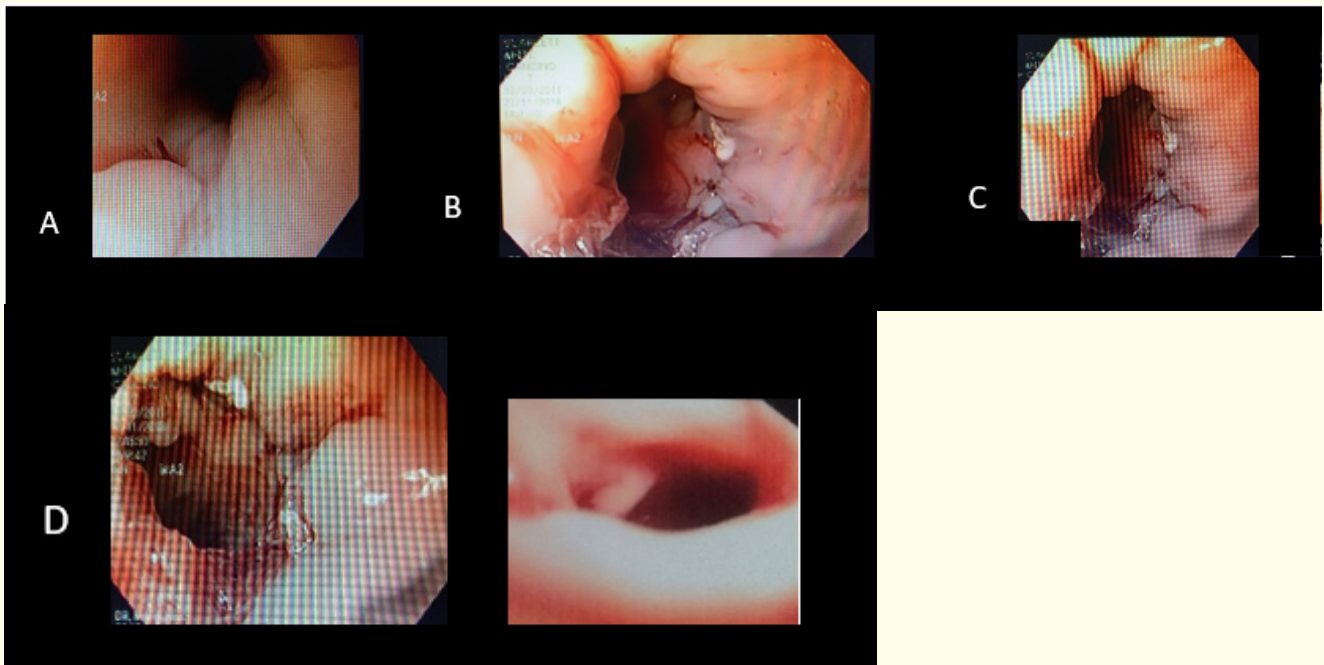
Thoracic and abdominal X-rays demonstrated stent migration to stomach (Figure 3). Endoscopy revealed stricture of 8 - 9 mm, with an irregular surface, which bleeds as the endoscope, of 9.8 mm, passed through it.

The stent's body obstructed the gastro-esophageal union, the proximal part is in the antrum and, the distal part, is on the upper part of the stomach, its body, convexly curved to the front view of the endoscope. In retroflexion, the proximal part of the stent, let easily see the thread located inside of the stent, it was grasped by foreign body forceps and pulled the esophageal stent, which migrated to stomach, was extracted without any complication.

Once the esophageal stent was removed, the stricture dilation program was reinitiated, because the parents did not accept to put another esophageal stent, they said that her daughter, while she has the stent, did not sleep well, she was very bothered and she also had gastroesophageal reflux.

Esophageal dilations were three per week for two weeks, with this frequency, the patients did not have dysphagia, and the injuries caused to the mucosa by dilations, did not reach the muscular layer she did not bleed, and the esophageal lumen is maintained on 14 to 18 mm; the dilatation program was reduced to two per week, she begins with dysphagia, the lumen diminished to 8 - 9 mm.

After 15 dilations, the parents accepted an esophagoplasty, it was done on November 20-2018. During surgery, the pediatric surgeons found adhesions in the mid part of the esophagus, which extended through mediastinum, they could not find where is the stricture, so, an upper endoscopy was made, by transillumination, at the level of the stenotic segment, the pediatric surgeons easily identified it in the outer part of the esophagus. They resected a fibrous ring of 1.5 cm length, and made a primary anastomosis; esophagoscopy identified the esophagoplasty sutures in the esophageal lumen, it was passed air at the time that, pediatric surgeons, put water on the mediastinum, no air bubbles were formed, the hermeticity of the esophagoplasty was confirmed (Figure 4). Trans-surgery esophagoscopies, and the following 7, 11 an 18<sup>th</sup> days post-surgery.



**Figure 4:** A. Stitch at fibrous stenotic ring, located by transillumination during a trans-surgical endoscopy. B. Esophagoplasty stitches, they were inflated as water is introduce in mediastinum, no air bubbles were seen. C. At seven days post-esophagoplasty, no dilation was made, D. At 11<sup>th</sup> day, it was dilated since 7 to 9 and 11 mm; D. At 18<sup>th</sup> day, it was dilated since 7, 9, 11, 12.8, 14 to 15 mm with less resistance and no hemorrhage. F. 35<sup>th</sup> day, no stitches are seen, after dilation since 7 to 15 mm, no bleed is seen.

She was on total parental nutrition for one week when she is on fast, the first seven post-surgery days. At day six, esophagogram revealed a mid-esophagus stricture, that lets the barium swallowed easily pass to the stomach.

Esophagoscopy, at days 7 and 11 showed an esophagoplasty with a lumen diameter of 7 - 8 mm, she was dilated to 7, 11 and 12.8 mm in last one.

The father said that her daughter, after the esophagoplasty, begins to eat better, faster and more food.

The management of this patient includes Savary-Guilliard dilations, esophageal stenting, esophagoplasty and once again, esophageal stricture dilations post-esophagoplasty.

Dilations are programmed once per week. We hope they can be done every two, three weeks and so forth.

The first dilation after esophagoplasty was done at day 11, she has been eating well, faster and more although she has only 7 - 8 lumen mm, the surface on stenotic esophagus was softer than previous to the esophagoplasty, it was dilatated to 9, 11 and 12.8 mm on December 1-2018, this history has not ended yet.

### Discussion

Caustic ingestion in childhood can produce since mild to severe oropharyngeal, esophageal and gastric signs and symptoms: drooling, vomiting, odynophagia, dysphagia, dyspnea, stridor and hematemesis [1-4], or severe complications as esophageal perforation, mediastinitis and death [5].

Strictures occur after the 3<sup>rd</sup> week, and barium swallow should be performed by the end of the 1<sup>st</sup> month [6]. Rehabilitation of esophageal caustic ingestion should be initiated as soon as esophageal stenosis is beginning, it could start in three to four weeks after caustic ingestion.

In this patient, mid esophagus stenosis rehabilitation begins at day 51 after caustic ingestion. We describe the long and complicated road she has to pass in her rehabilitation, it includes about 60 esophageal dilations with general anesthesia and endoscopy every one week, to two or three esophageal dilations per week, after that an esophageal metallic expandable covered stent with anti-reflux mechanism was put, it lasted a little bit more than two months, when it migrated to stomach, it was retired, after retirement, esophageal dilations were reinitiated.

The ingestion of corrosive agents produces oropharyngeal and gastro-esophageal lesions, ranging from minor injuries to severe necrosis, depends on the agent that is ingested, its concentration and time of exposure. Of 473 patients, endoscopy found 379 with burn in esophagus (80%) and 81 in stomach (17%) [7].

This case corresponds to a late beginning of esophageal stricture stenosis rehabilitation; as Gun mentioned, a group of esophageal strictures, which begin their rehabilitation six to 12 weeks after caustic ingestion, after one year of the accidentally ingested corrosive, remains on esophageal dilation program, and no one in the group of patients who begins their rehabilitation in the first weeks after caustic ingestion [8].

Self-expandable metallic thoroughly covered stent, with anti-reflux mechanism lasted in esophagus during six weeks, after that, it begins its slow stomach migration, in this patient, it takes about three weeks to migrate to stomach, she begins with dysphagia to solids but, the mother, expected until her daughter could not even pass her own saliva before the arrival to the hospital.

Esophageal dilations, after stent extraction, were performed more easily as compared to esophageal dilations before its esophageal placement, the passage of Savary-Guilliard dilators, 15 and 18 mm, are passed easily, with less resistance and less bleeding.

The stricture, in mid esophagus, in the first endoscopy, has one to two mm in diameter by 4 cm length. It needs three dilations per week; if there are two, the diameter diminishes from 18 to 13 - 14 mm and, if there is one per week, the diameter diminishes from 18 to 8 - 9 mm.

Mid esophagus stricture maintains 13 - 14 mm diameter with two esophageal dilations per week.

The placement of expandable prostheses, for one to four weeks, are useful in benign esophageal stenoses in children and, as Kramer described, stenting offers tremendous potential advantage over more traditional pneumatic or bougie dilation in its ability to provide continuous, radially oriented dilation pressure sustained over a period of time [9].

An indication for stent placement is benign dysphagia as a consequence of refractory benign esophageal stricture (RBES). Benign esophageal strictures (BES) can be caused by caustic ingestion. RBES are defined as an anatomic restriction because of a cicatricial luminal compromise or fibrosis resulting in clinical symptoms of dysphagia in the absence of endoscopic evidence of inflammation [10]; this may occur as the result of the inability to successfully remediate the esophageal narrowing to a diameter of, at least, 14 mm over five sessions at 2-week intervals [11]; mid esophagus stricture lumen is maintained on 13 - 14 mm with twice dilations, in her esophageal dilation program, the maximum reached diameter is 18 mm; the recurrence of the BES in this patients drive her to a prolonged esophageal dilation program until, the parents, accepted the placement of an esophageal expandable metallic stent.

Caustic BES is associated with a high risk of becoming refractory to treatment with repeated esophageal bougie or balloon dilation (EBD) [10,11]. The more time dilation program begin after caustic ingestion, more time needs esophageal dilation program as happened with this girl.

Stenting and use of mitomycin C (0.4 mg/mL) are technics used in caustic burns [8-18]. Endoscopically placed stents is a useful alternative for the management of caustic esophageal strictures [19].

Other method that can be used is cutting the fibrous ring formed after scaring after caustic burns [20]. In this patient, this method, after the prolonged esophageal program, before an esophageal expandable stent was placed, and after its retrieval because its stomach migration, was contemplated as a method that could help her in her dilation rehabilitation esophagus program, to separate the dilation since every two weeks to several months; we have a consensus talk, and after viewing pros and cons.

### **Pros: Endoscopic technique:**

1. Less invasive than a surgery.
2. Less expensive.
3. This method looks for resolve esophageal stricture.

### **Cons:**

1. We do not know how she is going to form scar, in fibrous ring in the esophagus, after it is cutted.
2. With this technique, the esophagus could be perforated and did not guaranteed good results.

### **Pros: Surgery.**

1. Could resolve esophageal stricture.

### **Cons:**

1. More expensive.
2. Higher risk because prolonged anesthesia and only left bronchi is intubated, to let pediatric surgeons, deflate right lung, and can work on mediastinum and esophageal wall.

The medical and surgical team decided to do an esophagoplasty, with resection of fibrous ring. It was resected a complete fibrous esophageal ring of 1.5 cm length, and primary esophageal anastomosis was made.

Esophageal dilations were made on days 11th and 18th, stricture lumen diminished to 7 - 8 mm, and could only be dilated to 11 and 15 mm respectively.

In the first one, they were passed three (7, 9 and 11 mm), in the second one, they were passed 7, 9, 11, 12.8, 14 and 15. Its an empiric rule not passed more than three dilations per session; however, each endoscopist "feels" resistance to the passage of esophageal dilator; in this patient, although, the stricture diameter is seven mm, there were no resistance to 7 and 9 mm dilators; low resistance with 11 and 12.8, more with 15, and 18 mm could not be passed.

Despite stricture diameter diminished to 7 mm after esophagoplasty, posterior esophageal stricture dilations were with less resistance and less hemorrhage than previous esophagoplasty; one issue that should be noted is that, her father, told her daughter could eat more quantity and faster after esophagoplasty. Another issue is low dilation resistance and less bleed.

At this moment, esophageal dilations are one per week. We have to follow up her for a long time. This history has not ended yet.

The best measure to prevent esophageal stenosis is prevention; but patients who arrived in the first four weeks after caustic ingestion, esophageal dilation program has to be initiated, because there are more possibilities that esophageal rehabilitation last less time than when arrived after 4 weeks, as in this girl who arrived after 7 weeks.

### Conclusion

#### What is known

1. Prevention is the best measure to avoid esophagus and stomach caustic burns.
2. The first step to try to avoid refractory esophageal strictures, is to begin as soon as possible esophageal dilation program, best before four weeks.
3. A late beginning of an esophagus dilation program in an esophageal established stricture, produces a refractory esophagus stricture.

#### What is new

1. Esophageal dilatations have less resistance and less hemorrhage after esophagoplasty than previous ones; nevertheless, stenosis lumen, after esophagoplasty, is smaller, the patient, eats more and faster as compare as to a larger esophageal lumen after dilations before the esophagoplasty.
2. The number of esophageal dilations is dictated by clinical symptoms as dysphagia, and not by the number of dilations the physician would like to do, if they cannot be separated, because the patient has dysphagia, the should be done as frequent as needed when it appears.
3. It is known, by gastroenterologists and surgeons, that in one session, the number of dilators should not be more than three dilators per session; however, because this has been established only by experience, our experience is that the number of dilations per session should be determined by perceived "resistance" to dilators when they passed the stricture.

#### What should be known by clinicians

1. An endoscopy evaluation has to be done in the first hours after caustic ingestion, after hemodynamic stabilization if it exists, the exception is when esophageal perforation is diagnosed previously by Thoracic X Ray.
2. If there is no burn, no treatment is needed.
3. If there is a caustic burn in esophagus and/or stomach, treatment must begin immediately: Airway permeability, vascular access, intravenous analgesic, steroids and antibiotics.

4. Although some authors leave their patients one week on fast and with nasogastric tube when they have caustic esophageal burns, in our institution, we give them food if they can swallow; esophageal stricture rehabilitation with dilations begins when is detected, three to four weeks after caustic ingestion.

### Conflict of Interest

I declare, I do not have any conflict of interest.

### Bibliography

1. Gaudreault P, *et al.* "Predictability of Esophageal Injury from Signs and Symptoms: A Study of Caustic Ingestion in 378 Children". *Pediatrics* 71.5 (1983): 767-770.
2. Betalli IP, *et al.* "Caustic ingestion in children: is endoscopy always indicated? The results of an Italian multicenter observational study". *Gastrointestinal Endoscopy* 68.3 (2008): 434-439.
3. Crain EF, *et al.* "Caustic ingestion symptoms as predictors of esophageal injury". *American Journal of Diseases of Children* 138.9 (1984): 863-865.
4. Lamireau T, *et al.* "Accidental Caustic Ingestion in Children: Is Endoscopy Always Mandatory?" *Journal of Pediatric Gastroenterology and Nutrition* 33.1 (2001): 81-84.
5. Riffat F and Cheng A. "Pediatric caustic ingestion: 50 consecutive cases and a review of the literature". *Diseases of the Esophagus* 22.1 (2009): 89-94.
6. Mas E., *et al.* "Management of caustic esophagitis in children". *Archives de Pédiatrie* 19.12 (2012): 1362-1368.
7. Dogan Y, *et al.* "Caustic gastroesophageal lesions in childhood: an analysis of 473 cases". *Clinical Pediatrics* 45.5 (2006): 435-438.
8. Gün F, *et al.* "Early and late term management in caustic ingestion in children: a 16-year experience". *Acta Chirurgica Belgica* 107.1 (2007): 49-52.
9. Kramer RE and Quiros JA. "Esophageal stents for severe strictures in young children: experience, benefits, and risk". *Current Gastroenterology Reports* 12.3 (2010): 203-210.
10. Zhang C., *et al.* "The use of retrievable self-expanding stent in treating childhood benign esophageal strictures". *Journal of Pediatric Surgery* 40.3 (2005): 501-504.
11. Vermeulen BD and Siersema PD. "Esophageal stenting in clinical practice: An overview". *Current Treatment Options in Gastroenterology* 16.2 (2018): 260-273.
12. Kochman MI., *et al.* "The refractory and the recurrent esophageal stricture: a definition". *Gastrointestinal Endoscopy* 62.3 (2005): 474-475.
13. Repici A., *et al.* "Natural history and management of refractory benign esophageal strictures". *Gastrointestinal Endoscopy* 84.2 (2016): 222-228.
14. Rodrigues-Pinto F, *et al.* "Risk factors associated with refractoriness to esophageal dilatation for benign dysphagia". *European Journal of Gastroenterology and Hepatology* 28.6 (2016): 684-688.
15. Luigi Dall'Oglio., *et al.* "Endoscopic management of esophageal stenosis in children: New and traditional treatments". *World Journal of Gastrointestinal Endoscopy* 8.4 (2016): 212-219.



16. Sweed AS., *et al.* "A prospective controlled study to assess the use of mitomycin C in improving the results of esophageal dilatation in post corrosive esophageal stricture in children". *International Journal of Pediatric Otorhinolaryngology* 79.1 (2015): 23-25.
17. El-Asmar KM., *et al.* "Topical mitomycin C application is effective in management of localized caustic esophageal stricture: a double-blinded, randomized, placebo-controlled trial". *Journal of Pediatric Surgery* 48.7 (2013): 1621-1627.
18. El-Asmar KM., *et al.* "Topical mitomycin C can effectively alleviate dysphagia in children with long-segment caustic esophageal strictures". *Diseases of the Esophagus* 28.5 (2015): 422-427.
19. Nogales O., *et al.* "Endoscopically placed stents: a useful alternative for the management of refractory benign cervical esophageal stenosis". *Revista Española de Enfermedades Digestivas* 109.7 (2017): 510-515.
20. Manfredi MA., *et al.* "Endoscopic electrocautery incisional therapy as a treatment for refractory benign pediatric esophageal strictures". *Journal of Pediatric Gastroenterology and Nutrition* 67.4 (2018): 464-468.

**Volume 6 Issue 8 August 2019**

©All rights reserved by Elizondo-Vázquez Jorge Bernardo., *et al.*