

Isolated Splenic Diffuse Cystic Lymphangiomas in an Adult: A Case Report with Literature Review

Hailu Wondimu Gebresellassie*

Assistant Professor of Surgery and GI Surgeon, Addis Ababa University, College of Health Sciences, School of Medicine, Ethiopia

***Corresponding Author:** Hailu Wondimu Gebresellassie, Assistant Professor of Surgery and GI Surgeon, Addis Ababa University, College of Health Sciences, School of Medicine, Ethiopia.

Received: February 15, 2019; **Published:** August 27, 2019

Abstract

Background: Lymphangiomas are uncommon congenital malformations of the lymphatic system that classically involve the skin or subcutaneous tissues and generally seen in infants and very young children. Isolated splenic lymphangiomas are extremely rare.

Case Presentation: A 23 year old male patient presented with a left sided abdominal swelling and dull dragging pain of 4 years. The pertinent finding on examination is a non-tender huge splenic mass. Imaging studies showed a mass occupying most of the abdomen arising from spleen.

Conclusion: Though rare splenic lymphangiomas should be considered in the differential of huge splenomegaly and splenectomy improves greatly the patient's condition.

Keywords: Spleen; Isolated; Lymphangiomas; Splenomegaly; Cystic

Background

Lymphangiomas are a rare anomalous developmental disorder occurring in infants and young children. The skin and subcutaneous tissues of the neck, axilla or groin are the usual sites involved. Intra-abdominal in general and isolated splenic involvement is very rare that there are only few case reports in the literature [1].

Here I report on a 23 year old man with isolated diffuse cystic lymphangiomas of spleen who underwent splenectomy. The patient recovered well and reported that his symptoms disappeared.

Case Presentation

A 23 year old Ethiopian man from a non-malarial area presented with a progressively increasing abdominal swelling and a dull dragging pain of 4 years duration. Physical examination showed a huge non-tender left sided abdominal mass that crosses the midline measuring 32 CMS from left coastal margin along the mid-clavicular line. Investigation showed a normal blood count and bleeding profile. Imaging studies showed highly enlarged spleen with multiple low attenuation foci. A diagnosis of huge symptomatic (pain) splenomegaly made and splenectomy done to avoid possible future rupture. Splenectomy were done through a bilateral sub coastal incision to get a better access. The surgery and post-operative course was uneventful. Histopathology report showed 32 x 27 x 22 cm encapsulated grey brown multi-nodular specimen which on cross section had dark brown soft multi-cystic material filled with yellowish to greenish material. Microscopy revealed showed diffuse ectatic lymphatic spaces lined by endothelial cells filled with lymph adjacent normal looking spleen parenchyma consistent with splenic diffuse cystic lymphangiomas.

Citation: Hailu Wondimu Gebresellassie. "Isolated Splenic Diffuse Cystic Lymphangiomas in an Adult: A Case Report with Literature Review". *EC Gastroenterology and Digestive System* 6.9 (2019): 608-611.

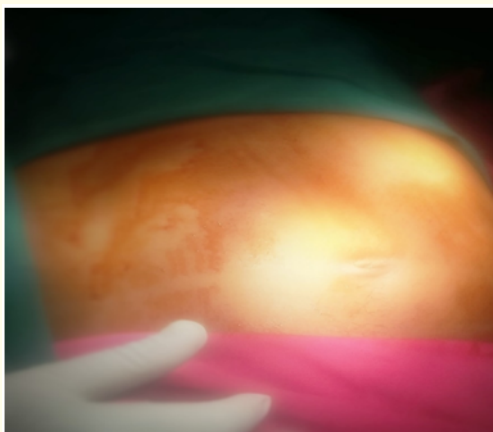


Figure 1: Distended abdomen as a result of huge splenomegaly.

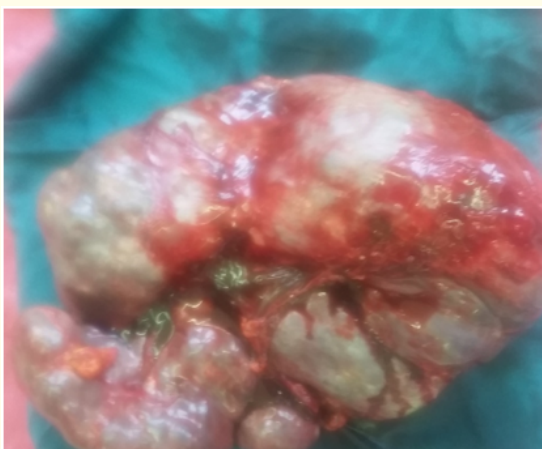

Figure 2: Spleen of diffuse cystic lymphangiomas specimen after splenectomy.

Discussion

Lymphangiomas are a rare disorder often involving multiple organs. It is characterized by cystic lymphangiomas which are diffuse proliferation of inter-connecting lymphatic channels [1]. The common sites involved are neck, axilla, groin and the face. Involvement of the intra-abdominal viscera is extremely rare and when involved multiple organs are affected. In one series by Goh over a period of 15 years, 14 intra-abdominal lymphangiomas were reported but only one was splenic. In another series by Allen, *et al.* none were splenic among six cases over a period of 18 years [2,3].

Lymphangiomas in general are commoner in children than adults but there were case reports of isolated splenic involvement even in an old age [4]. There is a report of a rapidly growing splenic lymphangiomas in a lactating mother by Rosalina Patti, Emilio Iannitto and Gaetano Di Vita in 2010 [5].

In many cases isolated lymphangiomas of spleen are small in size, asymptomatic and detected accidentally. Abdominal pain, swelling or fullness, early satiety are the manifestations of large lesions as in our patient [6]. Laboratory studies including complete blood count, bleeding profile are normal in most of the cases reported but there were also a report of an adult patient with isolated splenic lymphangioma presenting as a huge mass causing anemia and abdominal distension by Boubacar E., *et al* [7].

Typical ultrasound and Doppler examination findings consist of hypo-echoic cysts of various size with septation and vasculature within the mass [8].

The differential diagnosis of splenic cystic lymphangiomas include among others true splenic cysts, mesothelial cysts, cystic hamartomas, and parasitic (echinococcal) cysts [3].

Although there is limited experience with this condition, splenectomy seems the best treatment for such a large spleen as it relieves the symptoms, improves the anemia and thrombocytopenia that may be seen with such a huge spleen (but were not observed in our patient) and prevents the risk of a splenic rupture. Splenectomy relieved all the presenting complaints of our patient i.e. abdominal swelling and pain. Splenectomy for such large lesions is often done via large laparotomy incisions although there were a report of a successful laparoscopic splenectomy by Crema, *et al* [9].

Conclusion

Splenic cystic lymphangiomas though rare should be considered in the differential diagnosis of huge splenomegaly. Splenectomy when the spleen is huge as in this patient seems the best treatment.

Acknowledgements

I would like to thank the staff in the surgical ward and operating theater of department of surgery of Tikur Anbessa tertiary teaching hospital, Addis Ababa, Ethiopia.

Funding

No funding was used in the writing of the manuscript.

Availability of Data and Materials

There are no additional data and materials beyond those mentioned in the reference and within the manuscript.

Authors' Contributions

Hailu Wondimu Gebresellassie operated upon the patient and followed him in the post-operative period.

Competing Interests

The author declares that he has no competing interests.

Consent for Publication

Written informed consent was obtained from the patient for publication of this case report and accompanying images. A copy of the written consent is available for review by the Editor-in-Chief of this journal.

Bibliography

1. Ioannidis I and Kahn AG. "Splenic Lymphangioma". *Archives of Pathology and Laboratory Medicine* 139.2 (2015): 278-282.
2. H PKSKN. "Isolated cystic lymphangiomas of spleen in an adult : a diagnostic conundrum". *BMJ Case Reports* (2018).
3. Verghese BG., *et al.* "Lymphangioma of the Spleen - A Rare Tumor Rarely seen in an Adult : A Case Report and a Comprehensive Literature Review". *Euroasian Journal of Hepato-Gastroenterology* 3.1 (2013): 64-69.
4. Manoharan G V., *et al.* "Cystic lymphangioma of spleen: an abdominal flabbergast". *International Journal of Advances in Medicine* 2.1 (2015): 64-66.
5. Patti R., *et al.* "Splenic lymphangiomas showing rapid growth during lactation: A case report". *World Journal of Gastroenterology* 16.9 (2010): 1155-1157.
6. Rodríguez-montes JA., *et al.* "Splenic lymphangioma. A rare tumour. Presentation of 3 cases and a literature review". *Cirugía Y Cirujanos* 84.2 (2016): 154-159.
7. Efares B., *et al.* "Isolated splenic lymphangioma presenting as a huge mass causing anemia and abdominal distension in an adult patient: a case report". *Journal of Medical Case Reports* 12 (2018): 97.
8. Pistoia F and Markowitz SK. "Splenic lymphangiomas: CT diagnosis". *American Journal of Roentgenology* 150.1 (1988): 121-122.
9. Crema E., *et al.* "Letter to the Editor Splenic lymphangioma: a rare benign tumor of the spleen treated by laparoscopic surgery". *Arquivos Brasileiros de Cirurgia Digestiva* 25.3 (2012): 178-179.

Volume 6 Issue 9 September 2019

©All rights reserved by Hailu Wondimu Gebresellassie.