

Persistent Diffuse Lower Gastrointestinal Bleeding: Treatment in Extremis with FloSeal®

Francisco Javier Pérez Lara^{1*}, A Ferrer Berges², JM Hernández González¹, S Gómez González¹, C Tellez Iñiguez¹ and H Oliva Muñoz³

¹*Service of Surgery, Antequera Hospital, Málaga, Spain*

²*Service of Surgery, Malaga, Spain*

³*Chief of Surgery Service, Surgery Service, Antequera Hospital, Málaga, Spain*

***Corresponding Author:** Francisco Javier Pérez Lara, Digestive Surgeon, Antequera Hospital, Málaga, Spain.

Received: November 01, 2018; **Published:** December 21, 2018

Abstract

We describe a case presenting lower gastrointestinal bleeding that was finally resolved by tamponade with FloSeal® haemostatic matrix after all other available treatment possibilities had been exhausted.

Fundamentally, the treatment consists of inserting the tube containing the Sengstaken-Blakemore probe impregnated with FloSeal into the rectum-sigma.

With this treatment the patient's bleeding stopped, stools were normal and the usual haemoglobin levels re-established

The FloSeal® haemostatic matrix tamponade is a simple procedure that is easy to reproduce and can be very useful in cases of LGB of the last 20 cm of the digestive tract.

Keywords: *FloSeal; Lower Gastrointestinal Bleeding; Treatment*

Introduction

Lower gastrointestinal bleeding (LGB) accounts for 20 - 40% of acute gastrointestinal haemorrhage and its incidence is increasing [1]. It usually leads to hospital admission, and requires invasive diagnostic evaluation and the application of significant medical resources [2]. Although in the majority of patients with this condition, the bleeding is self-limiting and resolves favourably, outcomes, morbidity and mortality are greater in elderly patients and in patients with comorbid medical conditions [3].

In some cases, diagnostic and therapeutic tests may fail to locate and/or manage the haemorrhage, and the patient's situation can then become critical, with bleeding remaining uncontrolled despite multiple transfusions and with all normal options exhausted. The case presented below is one such, which was finally resolved by using a device consisting of a Sengstaken-Blakemore (SSB) probe impregnated with FloSeal® haemostatic matrix (FHM) (tamponade + haemostasis).

Clinical Case

We describe a case presenting LGB that was finally resolved by tamponade with FHM after all other available treatment possibilities had been exhausted.

This patient - male, aged 70 years with a history of hypertension, pulmonary emphysema, ischaemic heart disease and peripheral vascular disease - underwent a scheduled cholecystectomy for cholelithiasis.

In the postoperative period, the patient experienced LGB. After two colonoscopies (which failed to reveal the origin of the bleeding) and the transfusion of 14 units of RBC concentrates, two units of platelets and one unit of plasma, the bleeding remained uncontrolled for 12 days, during which the patient underwent three episodes of hypovolaemic shock. CT angiography (Figure 1) showed the source of bleeding to be in the last 20 cm of the large intestine, but with no clearly defined bleeding point (diffuse bleeding), meaning that embolisation could not be performed. Surgical intervention (low anterior resection) was considered, but finally rejected, in view of the patient's poor condition and medical history.

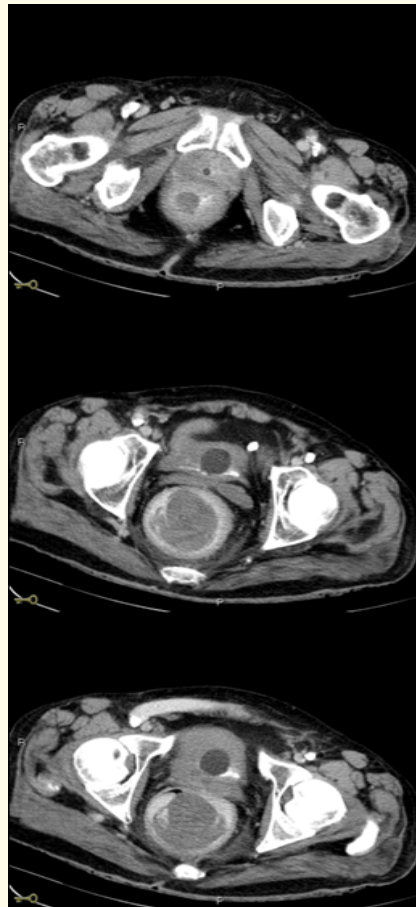


Figure 1: CT angiography, showing diffuse contrast extravasation in the last 20 cm of the digestive tract.

At this point, having exhausted all other diagnostic-therapeutic possibilities, we decided as a last resort to attempt treatment with the haemostatic device presented below.

The procedure consists of introducing a SSB, with the oesophageal balloon impregnated with FHM, into the rectum, by means of an introducer tube (Figure 2). Once it is inserted (Figure 3), the balloon is inflated, in order to bring the FHM into contact with the intestinal mucosa, under pressure from the balloon (Figure 4).

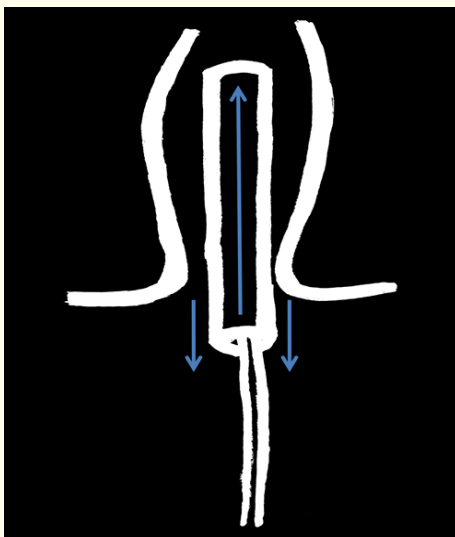


Figure 2: Inserting the introducer tube, containing the Sengstaken-Blakemore probe, into the rectum lumen.

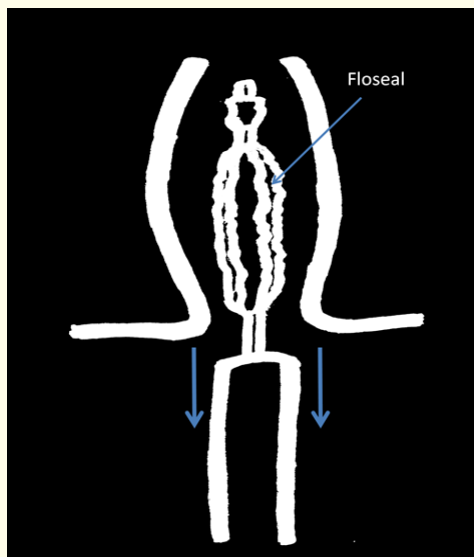


Figure 3: Removal of the introducer tube, leaving the Sengstaken-Blakemore probe within the rectosigmoid lumen.

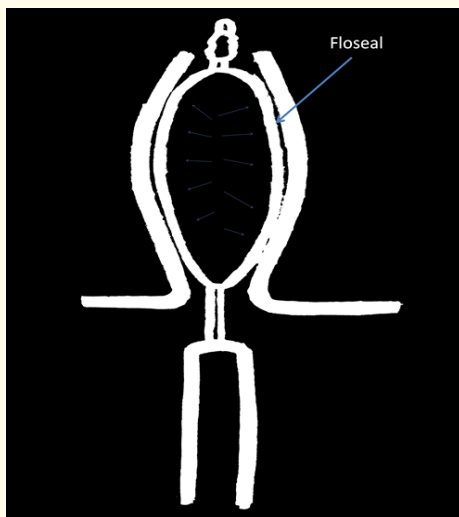


Figure 4: Inflation of the oesophageal balloon of the Sengstaken-Blakemore probe, bringing the FloSeal into contact with the rectal mucosa.

The elements needed - the SSB, the introducer tube, a 50 ml syringe and two FHM kits - were set out on a table (Figure 5a). In the first step of the procedure, the SSB balloon was inserted into the introducer tube (Figure 5b and 5c). Then, the entire surface of the oesophageal balloon within the probe was covered with FHM, using the cannula supplied (Figure 5d and 5e).

Once this device was prepared, it was lubricated with Vaseline and inserted into the rectum until resistance was noted (Figure 5f and 5g). The probe was then pushed inward through the introducer tube while the latter was removed (Figure 5h). As a result of this manoeuvre, the oesophageal balloon of the SSB, coated with the FHM, was firmly established within the rectosigmoid lumen.

Finally, the oesophageal balloon was inflated (Figure 5i) until resistance was noted, thus bringing the FHM into contact with all of the rectosigmoid mucosa (where the CT angiography had previously identified the area of bleeding) and exerting continuous pressure on this area.

The balloon was left in this position, at low pressure (to avoid provoking ischaemia in the area), for 24 hours, after which it was removed (Figure 5j).

With the introduction of the tamponade with FHM, the patient's bleeding stopped, stools were normal and the usual haemoglobin levels re-established (Figure 6). With the consequent clinical recovery, the patient was discharged from hospital without sequelae.

Discussion

The annual incidence of LGB is 0.03%, but it increases 200 times between the ages of 20 and 80 years [4]. The most common age at which LGB occurs is between 63 and 77 years [5]. LGB has been defined as that which occurs distal to the ligament of Treitz [6]. With the advent of deep enteroscopy, bleeding from the small bowel was classified as mid-gastrointestinal bleeding, and a new definition of LGB was proposed as bleeding distal to the ileocaecal valve [7]. Acute LGB is defined as a recent haemorrhage (within the last three days) that can cause haemodynamic instability, anaemia and/or the need for blood transfusion [8].

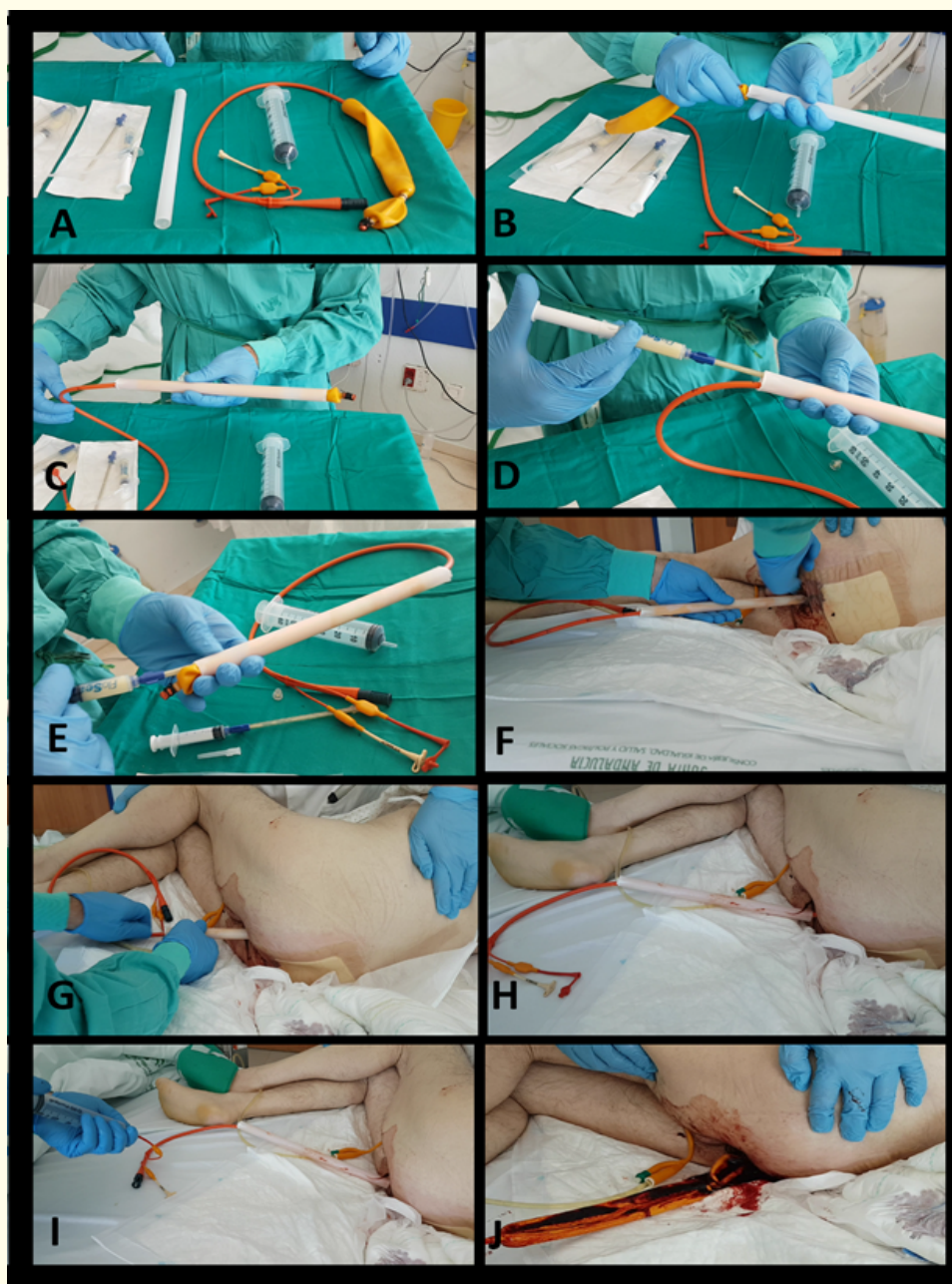


Figure 5a: Necessary elements to perform the tamponade with FloSeal.

Figures 5b and 5c: Inserting the oesophageal balloon of the Sengstaken-Blakemore probe into the introducer tube.

Figures 5d and 5e: Filling the introducer tube with FloSeal,

Figures 5f and 5g: Inserting the tube into the rectum lumen.

Figure 5h: Removing the tube while pushing the probe into the rectum.

Figure 5i: Inflating the oesophageal balloon.

Figure 5j: Removing the probe after 24 hours.

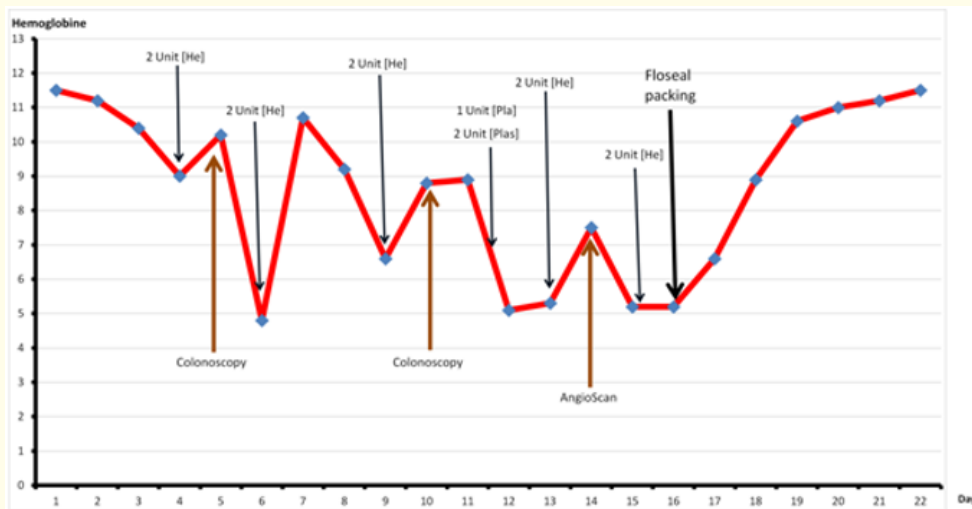


Figure 6: Haemoglobin levels.

The SSB probe is commonly used to control bleeding from oesophageal varices. This instrument consists of a probe with three channels; one is for gastric lavage and the other two are connected to a gastric balloon and to an oesophageal balloon. To our knowledge, the SSB probe has not previously been used in the treatment of LGB.

FHM is a combination of two independent haemostasis-promoting agents, consisting of patented gelatin granules, with a bovine-derived gelatin matrix component and a human-derived thrombin component [9], which swell to form a stable tampon at the site of the haemorrhage. The FloSeal granules expand by approximately 20% in ten minutes, allowing predictable control [9]. We have no previous record of its use in LGB.

Although blood loss from LGB can vary from mild to massive and life-threatening, in most patients it is self-limiting and hospitalisation is uncomplicated.

In comparison with upper gastrointestinal bleeding (UGB), patients with LGB tend to have higher levels of haemoglobin and are less likely to develop hypotensive shock or require blood transfusions [8]. Their mortality rate is 2 - 4% [5,9,10]. However, the case we present behaved more like one of UGB, as the patient underwent haemodynamic shock on three occasions, with a haemoglobin level below 6 g/dL.

In such cases of acute or massive LGB associated with haemodynamic instability, prompt, reliable and lasting haemostasis is required. Common forms of treatment include haemoclips, oversized over-the scope clips and thermal coagulation, or embolisation of the vessel from which bleeding is taking place, if it is identified by CT angiography.

However, none of these options is appropriate for lesions with diffuse bleeding. Added difficulties arise when massive bleeding obscures the focus of bleeding or when bleeding sites are tangentially located.

Argon plasma coagulation can resolve this problem. This approach has the important advantage over endoscopic techniques that it enables diffuse bleeding to be controlled over a large area, for which haemoclip placement is not feasible. However, this treatment requires a delicate technical balance between achieving lasting haemostasis and the risk of perforation. Therefore, the proposed tamponade with FHM may be the most appropriate for cases of diffuse LGB of the final section of the large intestine.

Conclusion

In conclusion, the FHM tamponade is a simple procedure that is easy to reproduce and can be very useful in cases of LGB of the last 20 cm of the digestive tract, both as an alternative to current forms of treatment and also as a rescue therapy when injection, clips and/or embolisation fail to achieve haemostasis at the bleeding point, or to deal with large diffuse haemorrhages when otherwise only thermal treatment or surgery would be possible, both of which produce significant risks.

Bibliography

1. Lanas A., *et al.* "Time trends and impact of upper and lower gastrointestinal bleeding and perforation in clinical practice". *American College of Gastroenterology* 104.7 (2009): 1633-1641.
2. Chait MM. "Lower gastrointestinal bleeding in the elderly". *World Journal of Gastrointestinal Endoscopy* 2.5 (2010): 147-154.
3. Strate LL., *et al.* "Risk factors for mortality in lower intestinal bleeding". *Clinical Gastroenterology and Hepatology* 6.9 (2008): 1004-1010.
4. Bounds BC and Kelsey PB. "Lower gastrointestinal bleeding". *Gastrointestinal Endoscopy Clinics of North America* 17.2 (2007): 273-288.
5. Farrell JJ and Friedman LS. "Gastrointestinal bleeding in the elderly". *Gastrointestinal Endoscopy Clinics of North America* 30.2 (2001): 377-407.
6. Eisen GM., *et al.* "An annotated algorithmic approach to acute lower gastrointestinal bleeding". *Gastrointestinal Endoscopy* 53.7 (2001): 859-863.
7. Raju GS., *et al.* "American Gastroenterological Association (AGA) Institute technical review on obscure gastrointestinal bleeding". *Gastroenterology* 133.5 (2007): 1697-717.
8. Zuckerman GR and Prakash C. "Acute lower intestinal bleeding: part I: clinical presentation and diagnosis". *Gastrointestinal Endoscopy* 48.6 (1998): 606-617.
9. Floseal Hemostatic Matrix Instructions For Use. CA: Baxter Healthcare Corporation. Fremont 934057.
10. Richter JM., *et al.* "Effectiveness of current technology in the diagnosis and management of lower gastrointestinal hemorrhage". *Gastrointestinal Endoscopy* 41.2 (1995): 93-98.

Volume 6 Issue 1 January 2019

© All rights reserved by Francisco Javier Pérez Lara., *et al.*