

Mucinous Adenocarcinoma as Malignant Degeneration of a Retrorectal Cyst. An Unexpected Outcome

Roldán Villavicencio Javier Ismael*, Larrea Oleaga Jasone, Marquina Tobalina Teresa, Servide Staffolani Maria José and Prieto Calvo Mikel

Department of General and Digestive Surgery, Cruces University Hospital, Basque Country, Spain

***Corresponding Author:** Roldán Villavicencio Javier Ismael, Department of General and Digestive Surgery, Cruces University Hospital, Basque Country, Spain.

Received: September 18, 2018; **Published:** October 29, 2018

Abstract

Frequently asymptomatic, these rare and congenital lesions are usually unrecognized and misdiagnosed. Benign behaviour is typical and surgery is the definitive treatment. Malignant degeneration is extremely rare and it's often delayed in diagnosis. We report a young woman who has been diagnosed of urinary tract infection, and during her complementary study, we found a presacral mass and suspicious of anal duplication (physical examination). Once the study was completed and diagnosis made (Retrorectal Cyst), the treatment of choice is complete surgical remove to prevent recurrences. Degeneration to mucinous adenocarcinoma was demonstrated in the pathological anatomy. Surgical removal is still the gold standard and the best way for a complete histopathological examination.

Keywords: *Mucinous Adenocarcinoma; Malignant Degeneration; Retrorectal Cyst*

Introduction

Generally asymptomatic, retrorectal tumors are heterogeneous and nonspecific, for that reasons the diagnosis is usually delayed. A variety of classification systems are known and divide these lesions into congenital, neurogenic, inflammatory, leiomyoma, developmental cyst, fibroma, chordoma, etc. Malignancy is uncommon and is more frequent in pediatric population than in adults. Delay of diagnosis can lead to disorganized growth of the retrorectal tumor; infiltration of adjacent structures and malignant degeneration.

Case Presentation

A 42 year-old woman was admitted from emergency for acute pyelonephritis. Retrorectal tumor was incidentally diagnosed by CT scan (Figure 1). Patient was asymptomatic and the physical exam showed an anal duplication (Figure 2) and a palpable rectal mass in proctological examination. Under suspicion of retrorectal cyst we request a pelvic MRI (magnetic resonance imaging) in order to delimit the tumor o presacral lesion and start planning surgery. MRI showed a well delimited, left, pararectal, complex and unilobed cyst (Figure 3). The patient scheduled for elective surgery for resection. During surgery a 10 x 6 cm retro-rectal cyst was evidenced. These tumor was fixed and adhered to sacrococcygeal bone. Complete resection of the tumor was performed with partial sacrectomy (Figure 4). No other adjacent pelvic structure was compromised and the anatomophological study was Hamartoma Cyst (Tail Gut) with malignant degeneration to mucinous adenocarcinoma with severe dysplasia, Limits of the cyst were respected. The patient was discharged without complications. One year follow up shows no radiological lesion or recurrence and the patient still asymptomatic.

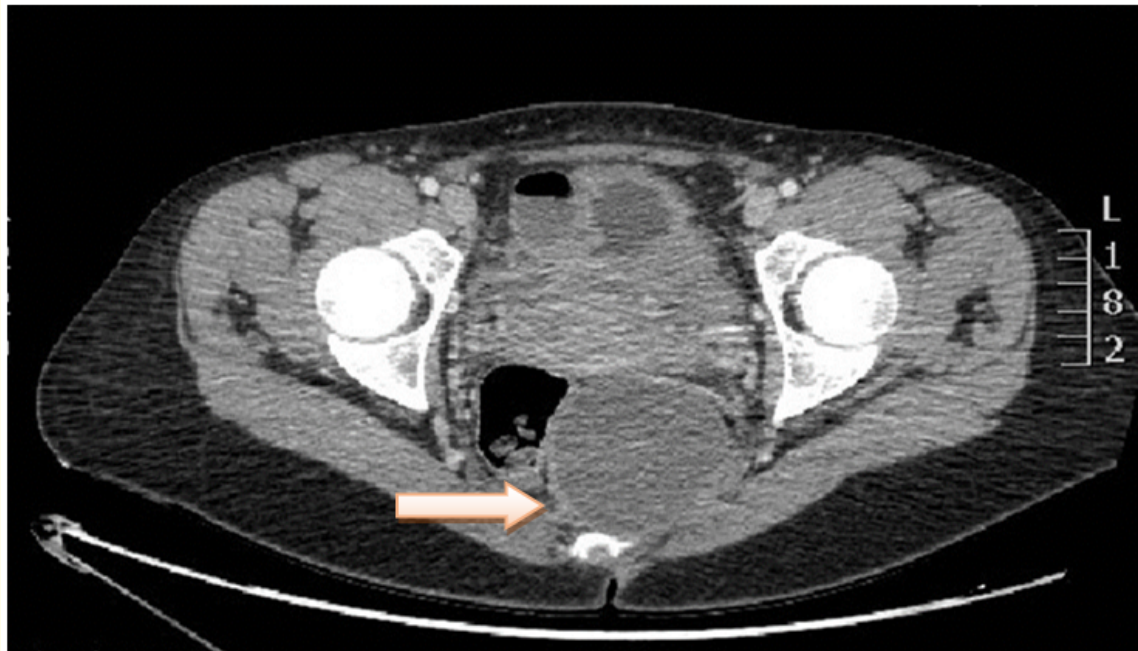


Figure 1: CT Scan showing retrorectal cyst.

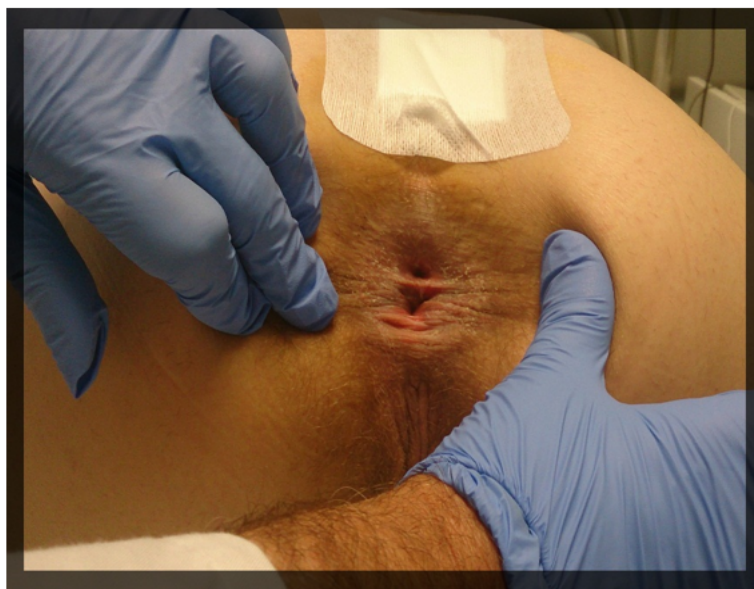

Figure 2: Physical examination reveals anal duplication.

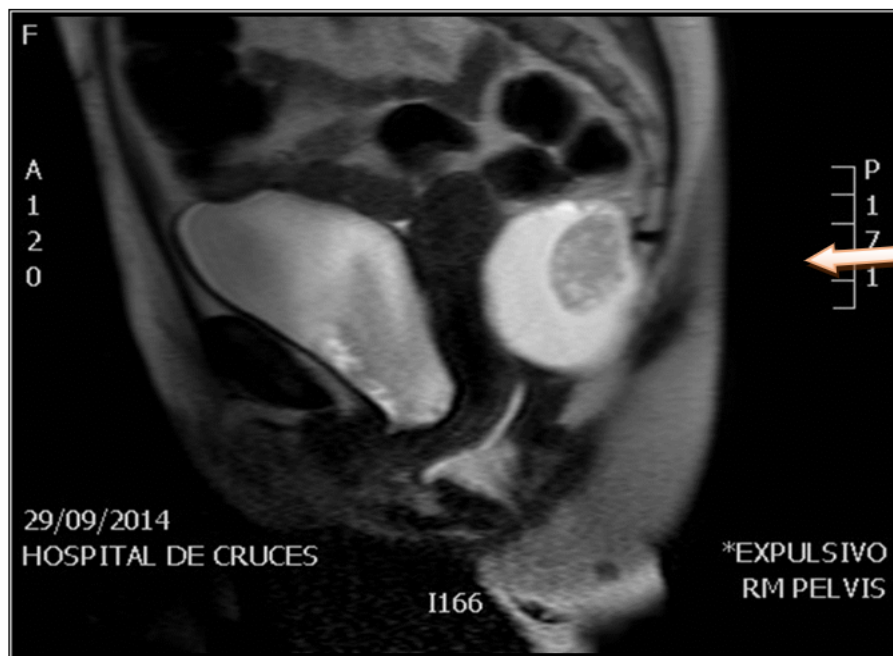


Figure 3: MRI Pelvic sagittal view, showed well delimited, retrorectal and multi-partitioned complex cyst.

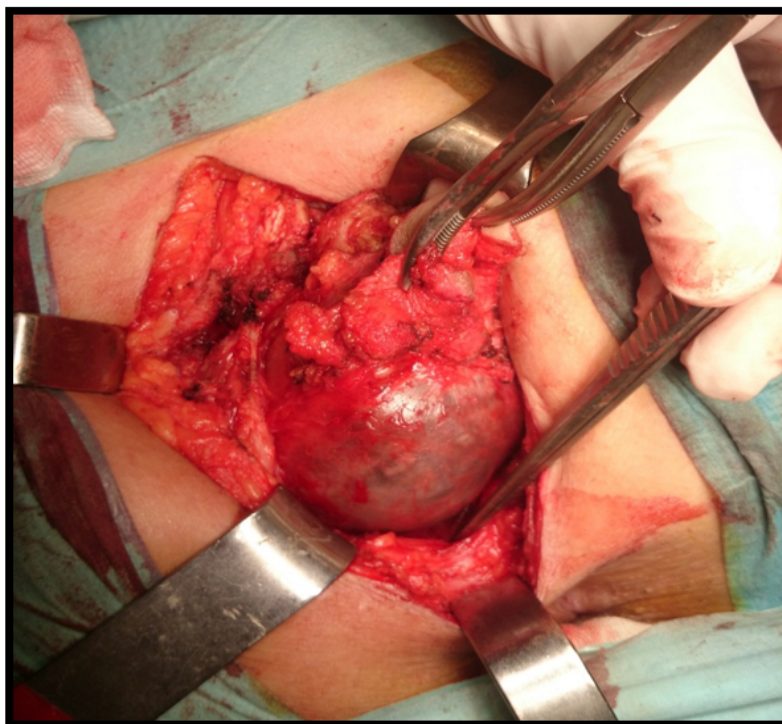


Figure 4: During surgery, complete resection of the tumor was performed.

Discussion and Conclusion

This unusual clinical entity and rare congenital tumor of development arise from post-natal primitive gut, usually with benign behaviour and often found incidentally [1,2]. If symptomatic, most clinical signs and symptoms result of compression or invasion of surrounding pelvic viscera or nerves. These retrorectal tumor or lesions that degenerate and arise from cystic lesions developing from remnants of the embryological post-anal gut containing mucous-secreting epithelium, known as Tail-gut cysts [2-4]. The potential for infection, perianal fistulas and most importantly, after surgery. Malignant degeneration of the epithelium component has been recognized in some rare reported occasions and its malignancies include adenocarcinoma, carcinoid adenosquamous carcinoma, squamous cell carcinoma, squamous cell carcinoma and sarcoma. There are many studies that present some types of malignancies and an extensive search shows 17 case reports of primary adenocarcinoma in the anatomopathological examination [2,3,5-10]; but there is no such report of a Mucinous adenocarcinoma degeneration as our clinical case. Early complete surgical resection represent the treatment of choice. Retrorectal space represents a potentially risk of damage during surgery, because it limits with vascular and nervous structures like ureters, the iliac vessels, and the sacral nerve roots. In order to organize the surgical treatment, pelvic -MRI is often used in diagnosing and managing the patients with presacral tumors, as it can provide excellent anatomic detail and soft-tissue contrast [2,10]. Complete surgical excision and preservation of the genito-urinary and fecal function are the mainstay in the management of these tumors.

Bibliography

1. Prasad AR, *et al.* "Retrorectal cyst hamartoma: report of 5 cases with malignancy arising". *Archives of Pathology and Laboratory Medicine* 124.5 (2000): 725-729.
2. Singer MA, *et al.* "Retrorectal Cyst Hamartoma : a rare tumor frequently misdiagnosed". *Journal of the American College of Surgeons* 196.6 (2003): 880-886.
3. Lokesh B, *et al.* "Retrorectal Cyst Hamartoma: Report of a case and Review of Literature (Tail Cyst)". *Indian Journal of Surgery* 75.1 (2013): s204-s207.
4. Mousakis O, *et al.* "Adenocarcinoma arising in a rectal duplication Cyst with distant metastasis A case report and review of the recent literature". *Annali Italiani di Chirurgia* (2018).
5. Chhabra S, *et al.* "Adenocarcinoma associated with tail gut cyst". *Journal of Gastrointestinal Oncology* 4.1 (2013): 97-100.
6. Gonul II, *et al.* "Tail gut Cyst: diagnostic challenge for both pathological and clinicians". *International Journal of Colorectal Disease* 22.10 (2007): 1283-1285.
7. Krivokapic Z, *et al.* "Adenosquamous carcinoma arising within a retrorectal tailgut cyst: report of a case". *World Journal of Gastroenterology* 11.39 (2005): 6225-6227.
8. Tampi C, *et al.* "Retrorectal cyst hamartoma (tailgut cyst) with malignant transformation". *Gynecologic Oncology* 105.1 (2007): 266-268.
9. Puccio F, *et al.* "Primary retrorectal adenocarcinoma: report of a case". *Techniques in Coloproctology* 7.1 (2003): 55-57.
10. Bo-Lin Yang, *et al.* "Retrorectal tumors in adults: Magnetic resonance imaging findings". *World Journal of Gastroenterology* 16.46 (2010): 5822-5829.

Volume 5 Issue 11 November 2018

©All rights reserved by Roldán Villavicencio Javier Ismael, *et al.*