

Staged Management of Meckel's Diverticulitis

Zi Qin Ng*, Sharin Pradhan and Palan Thirunavukkarasu

Department of General Surgery, St John of God Midland Public and Private Hospital, Midland, WA, Australia

***Corresponding Author:** Zi Qin Ng, Department of General Surgery, St John of God Midland Public and Private Hospital, Midland, WA, Australia.

Received: August 09, 2018; **Published:** October 01, 2018

Abstract

Meckel's diverticulum occurs in about 2% of the general population. It can be asymptomatic or presents in a wide range of clinical presentations such as bleeding, inflammation, perforation or obstruction. Majority of cases when discovered incidentally during intraoperative setting are dealt with surgical intervention. Herein, we present a case of Meckel's diverticulitis diagnosed by CT imaging and was managed initially with intravenous antibiotics. Interestingly, when patient returned for a surgical resection of the Meckel's diverticulum, the findings during laparoscopic did not concur with CT appearance.

Keywords: Meckel's; Diverticulitis; Antibiotics; Laparoscopy; Conservative

Abbreviations

PR: Per Rectal; CT: Computed Tomography; IV: Intravenous; MD: Meckel's Diverticulum

Introduction

A 68-year-old man presented with two-day history of right periumbilical abdominal pain. He described the pain as sharp, gradual onset and progressively worsened with no radiation. There was associated nausea but no vomiting. He had a few episodes of diarrhoea but no PR bleeding. He has never experienced this pain prior. He denied any fevers. His past medical history included type 2 diabetes mellitus. He has not had any recent colonoscopy in the last 5 years.

On examination, he was mildly tachycardic with heart rate of 100bpm. Other observations were within normal limits and he was afebrile. Abdomen was soft with tenderness around the right periumbilical region and right iliac fossa. There was no guarding or peritonism. Initial biochemistry examination revealed a normal white cell count and c-reactive protein of 100 mg/L.

The clinical differential diagnoses at this stage were acute appendicitis or right sided colitis. A computed tomography (CT) abdomen and pelvis was organised and depicted an inflamed blind ending diverticulum 30cm from the ileocaecal valve, representing Meckel's diverticulitis. There was also significant small bowel thickening proximal and distal to the Meckel's diverticulum (Figures 1 and 2).

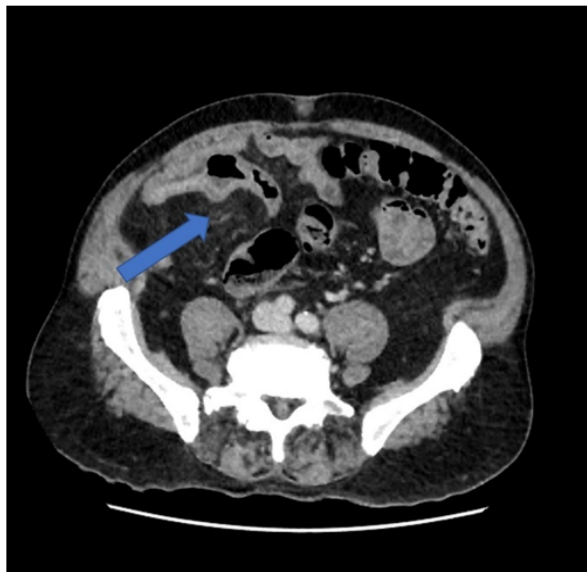


Figure 1: Axial film of the CT scan showing the blind ending diverticulum extending from the distal aspect of the ileum (arrow).

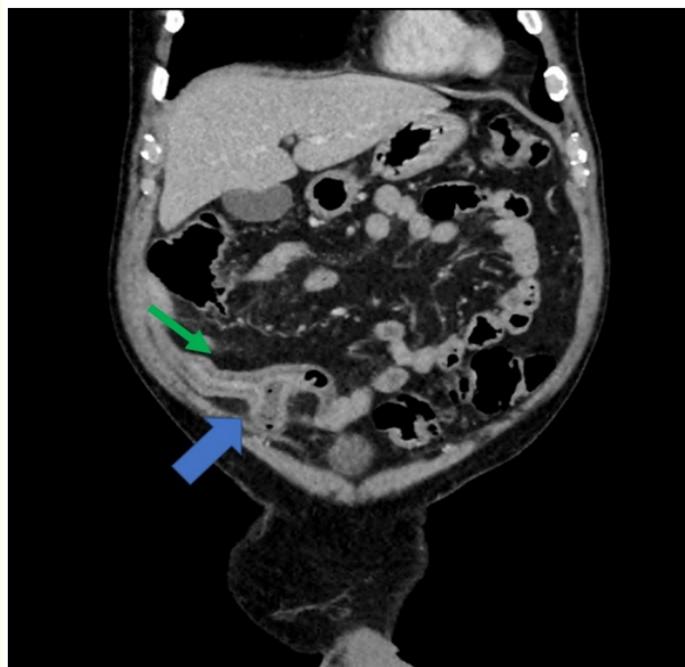


Figure 2: Coronal film of the CT scan demonstrating the diverticulum originating within 30 cm of the ileocaecal junction (thick arrow), representing most likely a Meckel's diverticulum. It is fluid-filled with a moderately thickened wall and there is surrounding inflammatory stranding in the adjacent fat (thin arrow).

Fluid resuscitation was initiated and broad-spectrum intravenous (IV) antibiotics (Piperacillin/Tazobactam) was administered. He was reassessed the following morning for consideration of surgery. However, he reported a significant improvement in pain and inflammatory markers improved. After a thorough discussion with him, it was decided that he would undergo an elective resection. He was continued on IV antibiotics for 48 hours and discharged home with oral antibiotics. A laparoscopic-assisted small bowel resection was planned 8 weeks later. Interestingly, during the laparoscopy, there was no convincing Meckel's diverticulum identified after running the entire small bowel on the antimesenteric border. There was a suspicious area but the findings did not concur with the CT appearance. Hence, it was decided not to proceed with the resection.

Discussion

Meckel's diverticulum (MD) is notably known for its "rule of twos". It is rare where it occurs in 2% of the population secondary to failure to regress of the vitelline duct; it has a ratio of 2:1 in male to female; it is approximately 2 inches in length and 2 feet proximal to the ileocaecal valve; it contains 2 common types of ectopic tissues (gastric and pancreatic most commonly) [1,2]. Majority of MD is asymptomatic and discovered incidentally [1,2]. A small group of MD can lead to bleeding, inflammation, perforation and obstruction [1].

Meckel's diverticulitis is a rare entity to be identified as most cases are diagnosed intraoperatively especially when the case is suspected to be appendicitis [3]. Majority of case reports or small case series have recommended surgical management in the form of small bowel resection or wedge resection when encountered with Meckel's diverticulitis [1,3]. In our case, as there was significant small bowel thickening proximal and distally and he responded swiftly to IV antibiotics, we decided to proceed with elective resection. Nevertheless, MD was not convincingly found intraoperatively. Given the risk of complication was 4% in the literature and it decreases with age [2], we decided against the small bowel resection.

Conclusion

Meckel's diverticulitis is a rare entity to be diagnosed pre-operatively as its symptoms and presentation often mirror those of appendicitis. In our case, we have demonstrated that conservative management during the initial presentation is an alternative option in the uncomplicated cases. Following resolution of the acute phase, an elective resection can be planned. The risk of complications arising from a Meckel's diverticulum reduces with age.

Acknowledgements

Nil.

Conflict of interest

The authors declare no conflict of interest.

Bibliography

1. Sharma RK and Jain VK. "Emergency surgery for Meckel's diverticulum". *World Journal of Emergency Surgery* 3 (2008): 27.
2. Bennett GL., et al. "CT of Meckel's diverticulitis in 11 patients". *American Journal of Roentgenology* 182.3 (2004): 625-629.
3. Wong CS., et al. "Meckel's diverticulitis: a rare entity of Meckel's diverticulum". *Journal of Surgical Case Reports* (2017): rjw225.

Volume 5 Issue 10 October 2018

©All rights reserved by Zi Qin Ng, et al.