

Recurrence of Volvulus of Sigmoid Colon after Sigmoid Colon Partial Resection: A Systematic Review and Case Report

Malene Enevoldsen and Alaa El-Hussuna*

Department of Surgery, Aalborg University Hospital, Aalborg, Denmark

***Corresponding Author:** Alaa El-Hussuna, Department of Surgery, Aalborg University Hospital, Aalborg, Denmark.

Received: August 13, 2018; **Published:** September 18, 2018

Abstract

Background: Volvulus of the sigmoid or pelvic colon, is the torsion of a colon segment over its mesenteric axis, resulting in partial or total occlusion. Recurrent sigmoid colon volvulus is an entity, which has been regarded as very rare. No systematic review has been performed to assess the extent, causes and possible solutions for this disease entity.

The aim of this review is to investigate the extent of recurrent sigmoid colon volvulus after partial surgical resection of sigmoid colon.

Method: A systematic search of PubMed and Embase databases were used to identify cases of recurrent sigmoid colon volvulus. The search was conducted according to PRISMA guidelines.

Inclusion criteria are studies reporting recurrent sigmoid volvulus after partial sigmoid resection, regardless of the resections' indications. The search was done by first author (ME) and repeated by research librarian. We present also a case of an 89-year-old male admitted with the rare case of recurrent sigmoid volvulus after partial colon sigmoid resection.

Results: Twelve studies were included, with a total of 61 patients with recurrent sigmoid volvulus after partial sigmoid resection. Indications for surgery included sigmoid volvulus and colon cancer. The time from surgery until (re)occurrence of sigmoid volvulus varied from months to 24 years. Follow up time varied from 8 to 30 years.

Conclusion: This systematic review suggest that recurrent sigmoid volvulus might not be as rare an event as it is believed to be, and shows that this area of surgery need further research.

Keywords: *Volvulus; Sigmoid Colon*

What's new in this article?

This is a case report and a systematic review of recurrent sigmoid colon volvulus. Recurrent sigmoid colon volvulus is an entity, which has been regarded as very rare, but this systematic review shows that it is not as rare as it is believed to be. The results of this systematic review may trigger researches to change the surgical technique to reduce the recurrence rate.

Introduction

Volvulus of the sigmoid or pelvic colon, is the torsion of a colon segment over its mesenteric axis, resulting in partial or total occlusion [1].

Sigmoid volvulus is common in adult older men and is commonly associated with recurrent episodes, comorbidity and shock [2]. It generally presents as a large-bowel obstruction and is often suspected and diagnosed by CT-scan and confirmed by endoscopy. The most

common symptoms are abdominal pain, distention and obstipation (the classic sigmoid volvulus triad). In addition, the main clinical findings in clinical examination are abdominal tenderness and asymmetrical abdominal distention. Other symptoms such as anorexia, vomiting, empty rectal vault, diminished or increased bowel sounds, visible peristalsis, dehydration, fever, and muscular defence are also relatively frequent [2].

In 2016 the American Society of Colon and Rectal Surgeons published a number of guidelines regarding treatment of colon volvulus [3]. It states that the first line treatment for colonic volvulus in absence of perforation or ischemia should be endoscopy, as the purpose is both diagnostic and in some cases therapeutic through decompression, de-torsion and insertion of a rectal tube [3]. This is to be done with or without colonic lavage. Surgery has earlier been secondary in cases where colonoscopy is insufficient, and primary in cases of dominating peritoneal irritation and signs of mucosa necrosis. However recent studies suggest [4-6] that because of a high risk of recurrent volvulus, which increases with every episode, surgical intervention such as sigmoid colectomy should be considered after endoscopy once the patient is stable, still within the initial admission, or soon afterwards to prevent reoccurrence [3]. This leads to the endoscopy converting an acute situation into an elective state, so that all preparations can be made prior to the surgery. Urgent surgery is indicated when endoscopic de-torsion of the sigmoid is not possible or in case of peritonitis, necrosis or perforation [7].

We present a case report of recurrent sigmoid volvulus after a Hartmann surgery performed due to earlier incidents of sigmoid volvulus with no correlation to megacolon, an event which to our knowledge has been sparsely reported in literature [8-12].

Recurrent sigmoid colon volvulus is a condition, which has been regarded as very rare. It has not been investigated in a systematic review before to assess the extent, causes and possible solutions for this disease entity.

Aim of the Study

The aim of this review is to investigate the extent of recurrent sigmoid colon volvulus after partial surgical resection of sigmoid colon.

Method

Predefined study protocol was used (unpublished) according to PRISMA guidelines. The aim of the study was to identify studies reporting recurrence of sigmoid colon volvulus after sigmoid colon resection. To investigate the extent of this clinical entity and attempt to identify risk factors leading to recurrence.

Eligibility criteria

Inclusion criteria

Case control studies, case reports, cohort studies and reviews about recurrent volvulus of sigmoid colon were included.

These studies assessed patients who had a recurrent episode of volvulus and were sigmoid resected following the first incident, or due to cancer. To ensure a broad search, the terms 'left hemicolectomy', 'hartmann's procedure' and 'sigmoidectomy' were used synonymously. The intervention group therefore included patients who had the surgical procedure done, between the first and the latest volvulus episode, regardless of the intention.

Exclusion criteria

Studies reporting of volvulus at other colon sites or recurrent sigmoid volvulus after non-surgical interventions, were excluded along with studies concerning non-adults. Studies in languages other than English, French, Danish, Swedish or Norwegian were excluded due to limited resources to translate from other languages.

Outcome measure

The primary outcome measure was to identify similar cases in the literature, to explore the extent of this clinical entity and to understand possible causes of the recurrent sigmoid volvulus after partial sigmoid resection.

Search strategy

The search was done by first author (ME) and repeated by research librarian from Randers hospital to ensure that all relevant studies are included. PRISMA guidelines were followed and reported. The search was done in two databases, PubMed and Embase. Last search date was the 18th of June 2018. Search terms were “intestinal volvulus” [MeSH] OR “volvulus” AND “recurrence” [MeSH] OR “colectomy/adverse effects” [MeSH] OR “postoperative Complications” [MeSH] OR “recurren*” OR “postoperative” OR “after surger*” AND “colectomy” [MeSH] OR “intestine, large/surgery” [MeSH] OR “sigmoid diseases/surgery” [MeSH] OR “anastomosis, surgical” [Mesh] OR “colectom*” OR “sigmoid surger*” OR “sigmoidectomy”. Excluded by search were papers on non-adults, papers before January 2010 and papers not in English, French, Danish, Norwegian or Swedish. Furthermore, the search included text words only with no filters, through the terms ‘hemicolectomy recurrent volvulus’, ‘left hemicolectomy recurrent volvulus’, ‘volvulus of sigmoid colon after hartmann’, ‘volvulus after sigmoid colon resection’, ‘volvulus after hartmann surgery’, ‘volvulus of the pelvic colon after colon resection’, ‘Recurrence of sigmoid volvulus after surgical intervention’, ‘recurrence of volvulus after sigmoidectomy’, ‘recurrent volvulus in the descending colon after surgery’, ‘recurrent volvulus after colectomy’, ‘recurrent volvulus after surgical treatment’, ‘recurrent volvulus after surgical intervention’, ‘return of volvulus after surgical treatment’, ‘resection of sigmoid colon recurrent volvulus’, ‘recurrent volvulus after resection of sigmoid colon’, ‘sigmoid resection recurrent volvulus’ and ‘sigmoid Diseases/surgery [MeSH Terms] volvulus recurrent’. Few articles were identified through reference lists. This search showed 284 results, of which 12 were included in the review.

Data extraction

First author (ME) extracted data. In case of doubt the second author read and extracted data from the included studies.

Statistical analyses and bias control

Due to the heterogeneity of the included studies, no statistical analyses or bias control analyses were conducted.

Results

A total of 12 studies were included (See PRISMA chart in figure 1). The included studies were 3 case reports, 8 retrospective studies and 1 systematic review, resulting in a total of 61 patients with recurrent volvulus after partial sigmoid resection. The included studies and patients’ characteristics are shown in table 1.

The studies were very heterogenous in method and outcome reporting. Therefore, it was not possible to extract all types of data from all the studies.

The period from surgery until (re)occurrence of sigmoid volvulus for the case reports were a mean of 8,2 years (2, 24, 4, 9 and 2 respectively) [11,13,14], which differs a little with what was observed in this case report, where our patient presented with recurrent volvulus 15 years after partial sigmoid resection. In the retrospective studies, the time until recurrence was not reported in three studies, and the mean period in the additional studies were 7,1 years (10,8, 2,25, 7,3, 3,16 and 12 respectively) [4,8,15-17]. For the included review [18] the time until recurrence was between 27 and 76 months.

The primary indication for sigmoid resection was volvulus, however one case report stated that the sigmoid resection was due to cancer [14].

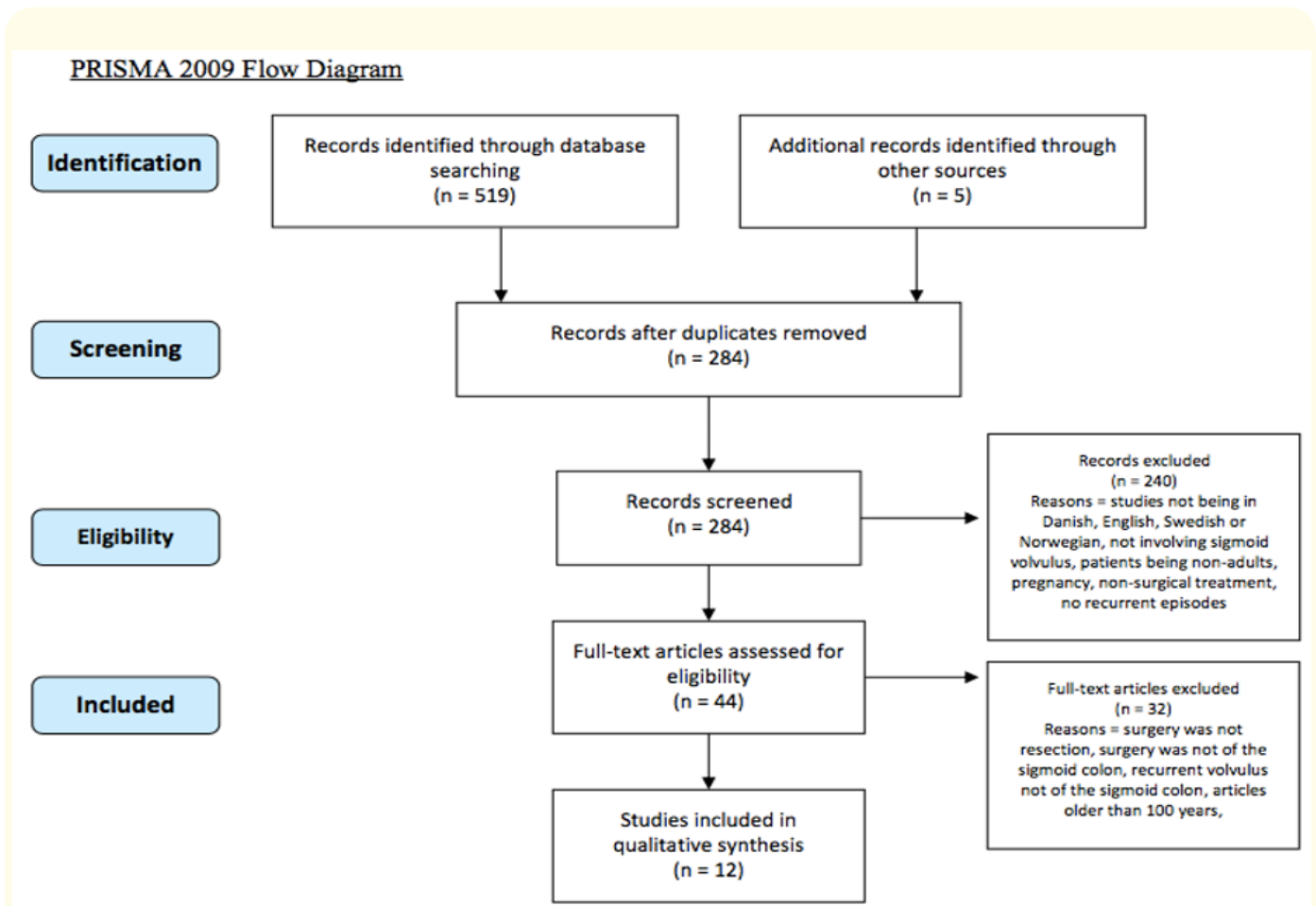


Figure 1: PRISMA flowchart of literature search. The search resulted in a total of 12 included and 272 excluded studies.

In total, the studies included 61 patients with recurrent sigmoid volvulus, of these 1 [4] patient presented after emergency surgery, while this was either elective surgery or not reported, for the remaining patients.

Little information about the patient demographics were possible to extract from the included studies, where only four papers [11,13-15] mentioned the age of the patients presenting with recurrent sigmoid volvulus and none of the studies included the status of the American society of anesthesiologists' classification system (ASA). The mean age among the recurrent patients were 56,8 years (75, 49, 47, 52 and 61 respectively), which is younger than the mean age during first admission with sigmoid volvulus, that in the most recent study was found to be 75 years [10]. The unifying aspect of all the included papers is, that the characteristics of the patients admitted with sigmoid volvulus after partial sigmoid resection are very sparsely reported. The reason for this might be, that the papers address different aspects of sigmoid volvulus and that the recurrent episodes are merely sub-findings.

| Paper | Study design | No. Of patients (sigmoid volvulus / total number) | Type of surgical intervention (n) of the patients presenting with recurrent sigmoid volvulus (recurrent episodes/ (n)) | Finding of megacolon | Period from surgery until (re)/ occurrence of sigmoid volvulus | Period of time (mean) | Additional notes |
|--|---------------|---|--|--|--|-----------------------|--|
| Johansson N, A. Rosemar and E Angenete, Recurrence Risk of Sigmoid Volvulus - a Single Center Cohort Study, 2017 | Retrospective | 168 | Elective surgery (61), Emergency surgery (46), 5 patients had at least one recurrence during the study period after surgery - 4 after sigmoid resection with primary anastomosis and 1 after ileorectal anastomosis. | - | - | 8,3 years | - |
| Bruzzi M, <i>et al.</i> Management of acute sigmoid volvulus: short- and long-term results, 2015 | Retrospective | 65 | Emergency surgery (1/6), sigmoid resection and primary anastomosis (1/33), surgical sigmoidpexy (1/3), colostomy without sigmoid resection (1) | 46% had megacolon | Up to 130 months (=10,8 years) | 8 years | - |
| Sadatomo A, <i>et al.</i> Sigmoid volvulus after laparoscopic surgery for sigmoid colon cancer, 2013 | Case report | 1 | Sigmoid resection of 15 cm due to cancer | No | 2 years | - | - |
| Suleyman O, <i>et al.</i> Sigmoid volvulus: Long-term clinical outcome and review of the literature, 2012 | Review | 6120 | Sigmoid resection (27/857) | 21 out of 27 had megacolon or megarectum | Between 27 and 76 months | 12 years | Recurrence was seen in 27 out of 857 sigmoid resected patients - these numbers are also reported in studies that are included in this table. |
| Scheffer RC, RJ Wiezer and R Timmer, Recurrent left-sided colon volvulus leading to mediastinal shift, 2007 | Case report | 1 | Sigmoid resection | - | 24 years | - | - |

| | | | | | | | |
|---|---------------|-------|--|--|---|----------|--|
| Chung YF, <i>et al.</i> Minimizing recurrence after sigmoid volvulus, 1999 | Retrospective | 35 | Elective surgery (23), Emergency surgery (6): Sigmoid colectomy (25), subtotal colectomy with ileorectal anastomosis (2), Hartmann procedure (2) | 10 patients had mega bowel, 4/6 recurrent volvulus episodes after a Hartmann procedure or sigmoid colectomy had megacolon | 27 months (= 2,25 years) | 8 years | - |
| Morrissey TB and EA Deitch, Recurrence of sigmoid volvulus after surgical intervention, 1994 | Retrospective | 29 | primary sigmoid colectomy and anastomosis (7/19), sigmoid resection and end colostomy (1/5), surgery without colon resection (2/4) | 11 had an associated megacolon, and 9 recurrences was in this group. | The mean interval until recurrence was 76 ± 17 months (= 7,3 years) | 12 years | 1 recurrence in 17 patients had disease limited only to the sigmoid colon |
| Hiltunen KM, H Syrja and M Matikainen, Colonic volvulus. Diagnosis and results of treatment in 82 patients. Eur J Surg, 1992. | Retrospective | 58/82 | Sigmoid resection (1/19), detorsion with or without sigmoidpexy (5/21), | - | - | 17 years | - |
| Friedman JD, MD Odland and MP Burbick, Experience with colonic volvulus, 1989 | Retrospective | 30/58 | Sigmoidectomy with anastomosis (1/12), emergency surgery with detorsion with or without fixation (1/2) | - | 37,9 months (= 3,16 years) | 15 years | - |
| Ryan P, MS, FRCS, FRACS. Sigmoid Volvulus with and Without Megacolon, 1982 | Retrospective | 66 | Elective surgeries: laparotomy and detorsion (1), laparotomy and colopexy (3), resection without anastomosis (4), resection with anastomosis (20), closure of colostomy (15). Emergency surgeries: laparotomy and detorsion (9), detorsion and colostomy (2), detorsion and colopexy (1), resection without anastomosis (14), resection with anastomosis (6). | Of patients with simple volvulus without relation to mega bowel, 13 had recurrence of symptoms (the nature of these not further elaborated - and therefore not included), in comparison 1/6 of the mega bowel related patients had recurrent sigmoid volvulus requiring further sigmoid colectomy. | 12 years | 20 years | Recurrence of symptoms includes but is not limited to subsequent volvulus of "new" sigmoid requiring further sigmoid colectomy |

| | | | | | | | |
|--|---------------|-----|--|-----------|------------------------------|----------|--|
| Harbrecht PJ and DE Frey, Recurrence of volvulus after sigmoidectomy, 1979 | Case report | 3 | Sigmoid colectomy (1), 60 cm sigmoid resection (1), sigmoidectomy (1) | Yes all 3 | 4 years, 9 years and 2 years | - | Volvulus of respectively the sigmoid, the splenic flexure, and sigmoid |
| Sharpton Cheek RC, Volvulus of the Sigmoid colon, 1976 | Retrospective | 114 | Elective surgery: acute operative/non-operative decompression followed by elective sigmoid resection (5/50). Emergency surgery: resection and colostomy (10). | - | - | 30 years | - |

Table 1: Showing the details of studies included in this systematic review. These studies were cases reports/case series, retrospective studies and review. There is a heterogeneity in method and outcome reporting.

Case report

An 89-year-old Caucasian male known with severe Alzheimer’s disease was admitted in 2017 to the emergency department from his nursing home, due to stomach ache and lack of bowel movements throughout 3 days.

The patient had a history of two earlier episodes of volvulus, which was treated with a colonoscopy, and desufflation, and in 2002 the patient underwent a partial colon sigmoid resection (Hartmann procedure) with formation of an ostomy, which later was reversed in 2003. The patient was diagnosed with Alzheimer dementia since 2012.

At time of presentation, the patient was conscious, afebrile and without pain, however because of the patient’s Alzheimer’s disease, he was unable to remember his own data and account for his meals. The nursing home staff had tried treating his lack of bowel movements with laxantia, without any effect.

At physical examination, the abdomen was found distended and soft with normal bowel sounds. There were no signs of peritonitis.

CT-scan of the abdomen showed a dilated left colon with a transition zone leading to suspicion of colon volvulus. Colonoscopy, with desufflation and insertion of a 30 French soft rectal tube was done with some response. At 25 cm height, a relatively stenosis was found, however it was easy passable with the scope, and there were no suspects of malignancy. He was afterwards discharged on the mend.

One month later, the patient was admitted to the emergency department with a fever, continuous lack of bowel movements throughout 6 days, and an increasingly distended abdomen with pain in the right side of the loin and anorexia. His blood pressure was 132/75, he had a pulse rate of 75, and blood analyses showed a C-reactive protein (CRP) of 14 mg/L and white blood cell count of $8,8 \times 10^9$ per litre. During the physical examination, the patient had a distended abdomen with soreness in the lower abdomen and sparse high-pitched bowel sounds. He underwent yet a colonoscopy, de-sufflation and insertion of a rectal tube. It was afterwards decided to offer him surgery as the patient was in great pain. Explorative laparotomy with a partial colon resection and left sided ostomy was performed. The patient was discharged on the 6th day postoperatively after uneventful postoperative course. Figure 2 shows the timeline of events.

Timeline

2002: Hartmann operation with ostomy after two episodes of volvulus

2003: reversion of ostomy

2008: the patient was admitted with constipation

2012: the patient was terminated from the dementia Clinique

2016: the patient was admitted with constipation and had a CT-scan done which showed colon ileus. Afterwards he had a colonoscopy with desufflation.

2017: the patient had in February a CT-scan with pseudo obstruction and colonoscopy with desufflation, and in November CT-verified colon volvulus along with desufflation.

December:

Day 1 (20/12):

- The patient was admitted with lack of bowel movements for 7 days and a severe distended abdomen.
- Suspicion of sigmoid volvulus after acute CT-scan
- Admitted for acute endoscopy, desufflation and with rectal drain

Day 2 (21/12):

- The patient had continuously distended abdomen, however no sign of peritonitis
- The patient was recommended for elective surgery in concert with his relatives

Day 3 (22/12):

- The patient underwent an explorative laparoscopic colon resection and ostomy formation, due to volvulus

Day 4 (23/12):

- First day postoperatively - the ostomy produced flawlessly, but had a hint of darkness on the serosa side above fascia level.

Day 5 (24/12):

- Second day postoperatively - Continuously progress and no remarks.

Day 6 (25/12):

- Third day postoperatively - the patient was discharged with decreasing infectious parameters and an ostomy with response.

Figure 2: Shows the timeline of events.

Discussion

The systematic review of the literature is summarized in table 1, where 12 studies in all reported 61 episodes of recurrent sigmoid volvulus after surgical treatment. The studies extend in the years from 1976 to 2017, and cover a range of procedures, which were relevant at the present time, but all have in common being surgical. Furthermore, it is noted whether the patients were found to have megacolon as this is a well-known predisposing factor for sigmoid volvulus, and this association differ from the patient in our case report. The figure also illustrates that most of the patients present with recurrent volvulus less than 10 years after primary surgery, which yet emphasize that our presented case is quite rare, as we present a case report of sigmoid volvulus 15 years after a Hartmann's procedure.

The review including a recent Swedish study [10], where 103 patients had surgery, either elective or emergency. Five patients experienced at least one volvulus recurrence, out of whom four had had a resection with a primary anastomosis and one had had a colectomy with ileorectal anastomosis. Four of them underwent a second surgery and did not again present with volvulus during the inclusion period.

A study from 1999 [15] also reports recurrence of sigmoid volvulus after total or partly sigmoid resection. The interesting pattern in this study however, is the significant association between megabowel at the initial surgery and the recurrence of sigmoid volvulus. This connection is not singular, and the coherence between e.g. megacolon and recurrent volvulus has been reported earlier [1,13], so has the occurrence of sigmoid volvulus after Hartmann procedure due to cancer [14]. Our patient differs, as he showed no signs of either conditions. In addition, we report a rare case of recurrent volvulus more than 15 years after the initial volvulus preventive surgery.

So even though surgical intervention was performed to prevent further events of sigmoid volvulus, the patient was yet admitted with incidents of volvulus of the sigmoid years after, and went through a second surgery, which is presumed relatively uncommon.

The mechanisms of volvulus of the sigmoid colon, are yet not fully understood, but might be related to a long sigmoid colon, age, a prolonged mesentery, scarring of the sigmoid mesentery [19], narrow mesenteric fastenings and no repair of the mesentery after surgery [1,20]. It has furthermore been suggested that nursing home residents and patients with psychological or neurological diseases more often have tendencies to develop sigmoid volvulus [21], as in described in this case report. It might be because the institutionalized elderly patients often are chronically constipated due to medications [1], delaying or ignoring call for bowel movements, parasympathetic hypofunction and inactivity. The fecal overload makes the colon distended and elongated, which eventually makes the colon rotate around its mesenteric axis [1]. The elongation is greater at the anti-mesenteric border, as the mesentery and vessels fastens its border, and as the distention intensifies, the sigmoid rotate to balance out the size difference [1]. The distension further increases with the proximal peristaltic movements, along with bacterial fermentation, resulting in an impaired blood supply. The rotation might eventually reach 360 degrees, and become unable to untwist back to its habitual anatomy [1].

Similar hypotheses exist regarding the higher rate among patients with neuropsychiatric diseases, as many of these patients also are institutionalized [19].

The cause of recurrence of sigmoid colon volvulus is not well known, however concomitant mega bowel at the time of the resection seems to be associated with recurrent sigmoid volvulus [12-18].

Furthermore, the studies hypothesize that a long remnant sigmoid colon because of inadequate resection [9], insufficient repair of the sigmoid mesentery or lack of re-peritonealization, adhesions due to previous abdominal surgery, missing postoperative adhesions and chronic constipation or motility disorders could contribute to development of recurrent sigmoid volvulus [14-16,18]. In addition, it has been proposed that the length of the remnant sigmoid might be longer after laparoscopic surgery compared to open surgery as it can be difficult to estimate the tension at the anastomotic site [14].

A study from 2015 [22] found a decrease in the extent of the enteric plexus and ganglion cells, along with fewer myenteric and submucosal ganglion cells, in patients undergoing sigmoid resection due to sigmoid volvulus. However, whether this correlation is causing sigmoid volvulus, or caused by it, is still unclear [23]. Patient demographic according to the most recent included study states that the majority of admitted sigmoid volvulus patients are men, and that the median age at the time of first admission was 75 years [10].

In this case, the patient's earlier Hartmann procedure and following adhesions might have contributed to the torsion of the sigmoid resulting in volvulus. The CT scan suspected a rather mobile transverse colon, which along with the remnant sigmoid colon that might still be long enough to entail sigmoid torsion, could promote the formation. In addition, the patient had a pronounced tendency to develop constipation, and a relatively stenosis at 25 cm height. This could possibly have contributed to increased elasticity of the colon and thereby the mobility. Information about the nature of the mesentery and whether this was elongated or if it was sutured after the Hartmann procedure was unavailable.

This opens for discussion of the surgical intervention, to further optimize the treatment, perhaps by reviewing the recurrence rate in relation to specific surgical procedures.

The study has many limitations. It analyzed mixed data from case reports/case series, retrospective studies and a review. The included studies were very heterogeneous in methodology and outcome reporting which did not allow statistical analyses. Including studies in five languages only is another limitation of this systematic review.

Conclusion

Sigmoid volvulus is a rather rare event, and even though the understanding of it has developed through time, the underlying reason for its formation, remains unclear. In addition to this, the development of recurrent sigmoid volvulus after (inadequate) surgical resection, is considered an even bigger enigma. This review showed that it might be more frequent than commonly considered.

A history of surgical intervention for volvulus including (sigmoid) colectomy should not exclude the possibility of recurrent volvulus in cases where patients are admitted with relevant symptoms such as abdominal pain, distention and obstipation, and diagnostic imaging and endoscopy should always be considered.

Funding

None.

Conflict of Interests

None.

Bibliography

1. Osiro SB, et al. "The twisted colon: a review of sigmoid volvulus". *American Surgeon* 78.3 (2012): 271-279.
2. Atamanalp SS. "Sigmoid volvulus: diagnosis in 938 patients over 45.5 years". *Techniques in Coloproctology* 17.4 (2013): 419-424.
3. Vogel JD, et al. "Clinical Practice Guidelines for Colon Volvulus and Acute Colonic Pseudo-Obstruction". *Diseases of the Colon and Rectum* 59.7 (2016): 589-600.
4. Bruzzi M, et al. "Management of acute sigmoid volvulus: short- and long-term results". *Colorectal Disease* 17.10 (2015): 922-928.
5. JO Larkin T, et al. "Recurrent Sigmoid Volvulus – Early Resection may Obviate Later Emergency Surgery and Reduce Morbidity and Mortality". *The Annals of The Royal College of Surgeons of England* 91.3 (2009): 205-209.
6. Tan KK, et al. "Management of acute sigmoid volvulus: an institution's experience over 9 years". *World Journal of Surgery* 34.8 (2010): 1943-1948.
7. Oren D, et al. "An algorithm for the management of sigmoid colon volvulus and the safety of primary resection: experience with 827 cases". *Diseases of the Colon and Rectum* 50.4 (2007): 489-497.
8. Friedman JD, et al. "Experience with colonic volvulus". *Diseases of the Colon and Rectum* 32.5 (1989): 409-416.
9. Hiltunen KM, et al. "Colonic volvulus. Diagnosis and results of treatment in 82 patients". *European Journal of Surgery* 158.11-12 (1992): 607-611.
10. Johansson N, et al. "Recurrence Risk of Sigmoid Volvulus - a Single Center Cohort Study". *Colorectal Disease* 20.6 (2018): 529-535.
11. Scheffer RC, et al. "Recurrent left-sided colon volvulus leading to mediastinal shift". *Clinical Gastroenterology and Hepatology* 5.7 (2007): A34.
12. Sharpton B and Cheek RC. "Volvulus of the sigmoid colon". *American Surgeon* 42.6 (1976): 436-440.
13. Harbrecht PJ and Fry DE. "Recurrence of volvulus after sigmoidectomy". *Diseases of the Colon and Rectum* 22.6 (1979): 420-424.
14. Sadatomo A, et al. "Sigmoid volvulus after laparoscopic surgery for sigmoid colon cancer". *Asian Journal of Endoscopic Surgery* 6.3 (2013): 217-219.
15. Chung YF, et al. "Minimizing recurrence after sigmoid volvulus". *British Journal of Surgery* 86.2 (1999): 231-233.
16. Morrissey TB and Deitch EA. "Recurrence of sigmoid volvulus after surgical intervention". *American Surgeon* 60.5 (1994): 329-331.
17. Ryan P. "Sigmoid Volvulus with and Without Megacolon". *Diseases of the Colon and Rectum* 25.7 (1982): 673-679.
18. Suleyman O Mdaak, et al. "Sigmoid volvulus: Long-term clinical outcome and review of the literature". *South African Journal of Surgery* 50.1 (2012): 9-14.

19. DA Margolin WC. "The Pathogenesis and Etiology of Colonic Volvulus". *Seminars in Colon and Rectal Surgery* 10 (1999): 129-138.
20. Alatise OI., et al. "The role of the anatomy of the sigmoid colon in developing sigmoid volvulus: a cross-sectional study". *Surgical and Radiologic Anatomy* 35.3 (2013): 249-257.
21. Swenson BR., et al. "Colonic volvulus: presentation and management in metropolitan Minnesota, United States". *Diseases of the Colon and Rectum* 55.4 (2012): 444-449.
22. Fujiya K., et al. "Sigmoid volvulus is associated with a decrease in enteric plexuses and ganglion cells: a case-control study". *International Journal of Colorectal Disease* 30.5 (2015): 673-678.
23. Safioleas M., et al. "Clinical considerations and therapeutic strategy for sigmoid volvulus in the elderly: a study of 33 cases". *World Journal of Gastroenterology* 13.6 (2007): 921-924.

Volume 5 Issue 10 October 2018

© All rights reserved by Malene Enevoldsen and Alaa El-Hussuna.