

Endoscopic Treatment of Complications of Broken Liver Hydatid Cysts in Bile Ducts

Berraida Rida*, Seddik Hassan, Y Touibi and A Benkirane

Service of Gastro-Gastroenterology II of the Hospital Military Mohammed V of Rabat, Morocco

***Corresponding Author:** Berraida Rida, Service of Gastro-Gastroenterology II of the Hospital Military Mohammed V of Rabat, Morocco.

Received: July 04, 2018; **Published:** July 17, 2018

Keywords: *Endoscopic Treatment; Biliary Complication; Hydatid Cyst of the Liver*

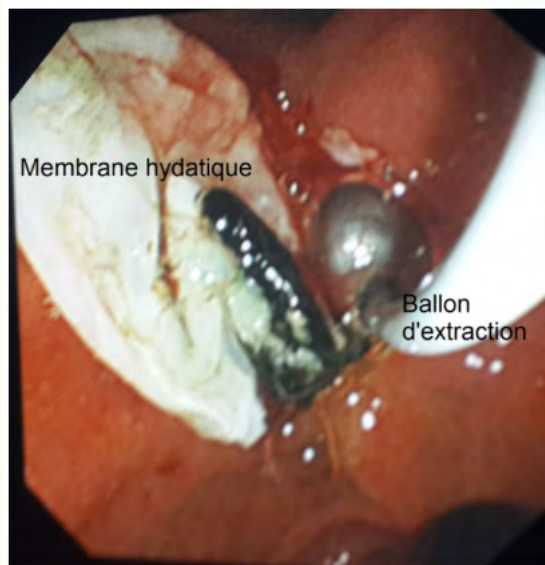


Figure 1: Endoscopic view after biliary sphincterotomy endoscopic showing the extraction of a hydatid membrane by extraction balloon (Photo from the gastro-gastroenterology II service of the HMIMV).

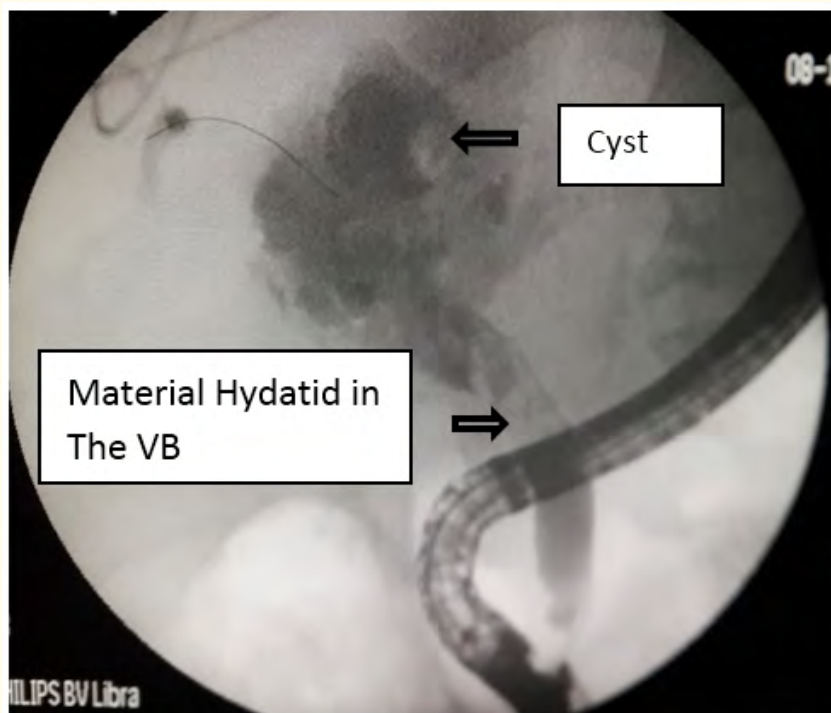


Figure 2: Endoscopic retrograde cholangiography showing broad communication between the cystic cavity and bile ducts containing hydatid material (Photo from the gastro-gastroenterology II service of the HMIMV).

Objective

The objective was to assess and analyze the effectiveness from ERCP in the diagnosis and treatment of hydatid cysts of Broken liver in biliary pathways.

Patients and Methods

This is a retrospective study and Descriptive of 15 years, ranging from January 2002 to March 2017, Having Patients with a fistulize KHF in the bile ducts. The ERCP and the Sphincterotomy Biliary Endoscopic have been carried out in all patients, 18 times in Operative and 21 times in post-op.

Results

39 patients with a broken KHF in the biliary tract, or 2.4% of the indications of ERCP. In our series have been included. The average age of patients were of 47 years, with male predominance in 65% of cases. Broken KHF in the bile ducts were Complications of a persistent external biliary fistula. In Post-operative in 34% of cases. The sphincterotomy a been carried out in all patients allowing the extraction of de Hydatid material by extraction balloon or by Basket Slept. The evolution was marked by the disappearance de Jaundice after 5 to 12 days on average after the Endoscopic gesture and the drying of the fistula Biliary After 10 to 12 days.

Discussion

The Hydatid cyst of the liver is a parasitic disease due to the Development of the larval form of the dog's Taenia Echinococcus Granulosus. This pathology remains frequent and it is a public health problem in countries of high endemicity. The Mediterranean countries and more particularly those of the Maghreb are Considered to be hydatid endemic countries [1].

Intra-bile rupture is the most serious and most severe complication frequent Hydatid disease of the liver. His diagnosis and especially his taken in charge remains difficult. His clinical presentation can go from forms Asymptomatic To severe acute cholangitis [2].

ERCP and endoscopic sphincterotomy are therapeutic advances in Bile complications of hepatic echinococcosis.

It is an innovative treatment that has already shown its effectiveness and Safety In pre and post-op. It allows to shorten the stay Post-operative and avoid reintervention, often difficult and haemorrhagic.

Conclusion

The results of this study confirm the efficacy and safety of ERCP and endoscopic sphincterotomy in bile complications of hepatic echinococcosis. It shortens the post-operative stay and avoids reintervention, often difficult and haemorrhagic.

Bibliography

1. Faraj P., *et al.* "Hydatid cyst of the liver". EMC (Elsevier Masson SAS, Paris), Hepatology 7-023-A-10 (2008).
2. Committee Interdepartmental to combat hydatidosis/echinococcosis. Fight against Hydatidosis/Echinococcosis. Guide to wrestling activities. Kingdom of Morocco (2007).

Volume 5 Issue 8 August 2018

©All rights reserved by Berraida Rida., *et al.*