

Transanal Resection of a Neuroendocrine Rectal tumor. An Alternative and Safe Technique

Alexander Forero-Torres*, Manuel Losada Ruiz, Beatriz Dieguez and Alfredo Alonso Poza

Department of General and Digestive Surgery. Division of Coloproctology, Hospital Universitario del Sureste, Spain

***Corresponding Author:** Alexander Forero-Torres, Department of General and Digestive Surgery. Division of Coloproctology, Hospital Universitario del Sureste, Spain.

Received: May 25, 2018; **Published:** November 26, 2018

Abstract

Introduction: Neuroendocrine tumors (NETs) are a heterogeneous group of tumors, rectal NETs are the most common; The treatment of rectal NET is determined by the size of the primary lesion, the transanal microsurgery (TAMIS) may be considered for the resection.

Case Presentation: A 38 year old woman of Asian background presented with one year of proctalgia and mild rectal bleeding without response at medical treatment; a colonoscopy was performed revealing a 4 - 5 mm whitish nodule, histopathology showed features compatible with a neuroendocrine carcinoid tumor. An endoscopic mucosal resection and polypectomy was performed but histopathology report confirmed the presence of a neuroendocrine tumor involving the deep resection margin. We perform a resection with TAMIS approach using a single anal port with three 5 mm trocars. The histology report showed no evidence of residual malignancy; the patient was discharged after 48 hours.

Discussion: The treatment of rectal NET is determined by the size. Small lesions (< 1 cm) can be controlled with endoscopic mucosal resection. Bigger lesions may require a lower anterior resection or an abdominal-perineal resection. Transanal microsurgery may be considered to avoid major surgeries in selected lesions.

Conclusion: Transanal microsurgery (TAMIS) allows the removal of the entire local thickness of lesions up to 15 cm from the anal margin. It is a safe and reproducible technique.

Keywords: *Case Report; Neuroendocrine Tumors (NETs); Transanal Microsurgery (TAMIS)*

Introduction

Neuroendocrine tumors (NETs) are a heterogeneous group of tumors that arise in various anatomical sites. From the entire gastrointestinal tract, rectal NETs are the most common, comprising 17 - 27% [1,2]. The majority of this tumors are asymptomatic, the symptoms include rectal bleeding, anal pain, constipation and tenesmus. These lesions are usually incidentally found during colonoscopy. They have an overall 5-year survival rate of 88.3%, with 90.8% for localized disease, 48.9% for regional disease and 32.2% for metastatic disease [1,3,4].

Case Report

A 38 year old woman of Asian background, without any previous medical history presented with one year of proctalgia and mild rectal bleeding. In view of poor response to an initial management for grade II hemorrhoids and anal fissure, a colonoscopy was performed revealing a 4 - 5 mm whitish nodule, located at 7 - 8 cm from the anal margin (Figure 1). Histopathology from a biopsy showed Fragments of mucosa of the large intestine infiltrated fundamentally in the submucosa, by a cellular epithelial proliferation, which forms organoid structures, constituted by cells with little atypia, positive by immunohistochemical for chromogranin (>25%) and synaptophysin, being negative for CK7 and CK2. The Urinary elimination of 5-hydroxyindoleacetic acid in 24 hrs was 1,7 mg/24 hrs (2-9 mg/24 hrs). CT-scan showed no abnormalities, a pelvic MRI showed alterations of the mucosal intensity and discrete thickening at 5 cm of the anal margin with no evidence of mucosal or perirectal lesions or abnormal lymphadenopathies (Figure 2). Upper and Low GI endoscopy rule out adjacent lesions or co-existing NET tumors. A low EU showed a discreet rise of the rectal mucosa with point fibrin suggestive of a lesion located at 7 cm of the anal margin (Figure 3). An endoscopic mucosal resection and polypectomy was performed (Figure 4 and 5). Histopathology report confirmed the presence of a neuroendocrine tumor involving the deep resection margin. We decided to perform excision by transanal approach. Flexible colonoscopy was performed identifying and marking the biopsy scar with 2 clips (Figure 6); a single anal port

with three 5 mm trocars was introduced (Figure 7), the clips marking the lesion were identified and circumferential marking 1 cm from the clips was performed with electrocoagulation (Figure 8 and 9); the tumor was dissected and removed, with subsequent closing of the mucosa using continua reabsorbible stich V-Loc. A hemorrhoidectomy was also performed at the same time. The histology report showed reparative change associated with black pigment deposition with no evidence of residual malignancy; the patient was discharged after 48 hours. We perform an annual upper and low endoscopy and the patient remains asymptomatic.

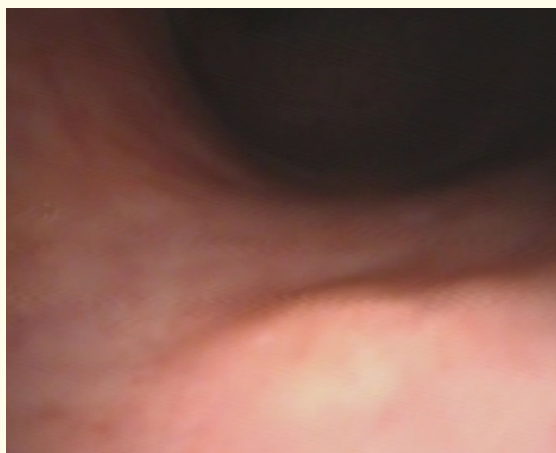


Figure 1: Whitish nodule, located at 7 - 8 cm from the anal margin, prior to endoscopic resection.

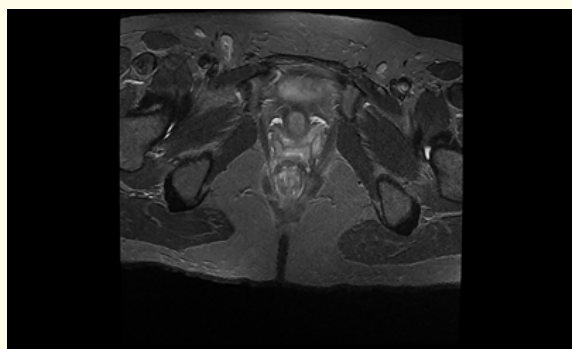


Figure 2: Whitish nodule, located at 7-8cm from the anal margin, prior to endoscopic resection.

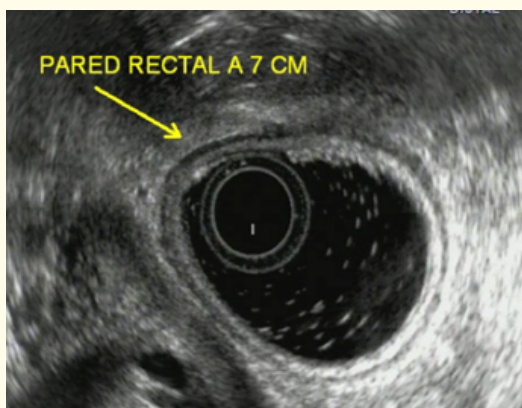


Figure 3: Lesion located at 7 cm of the anal margin.

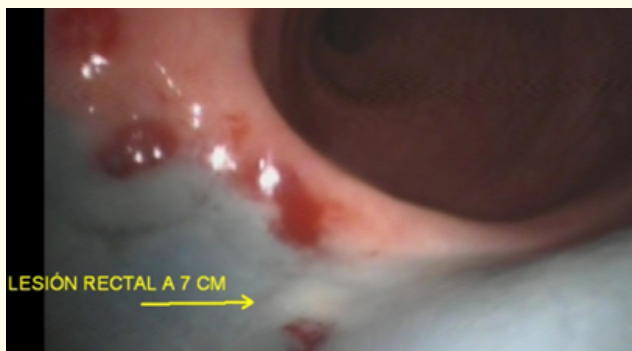

Figure 4: Endoscopic mucosal resection.

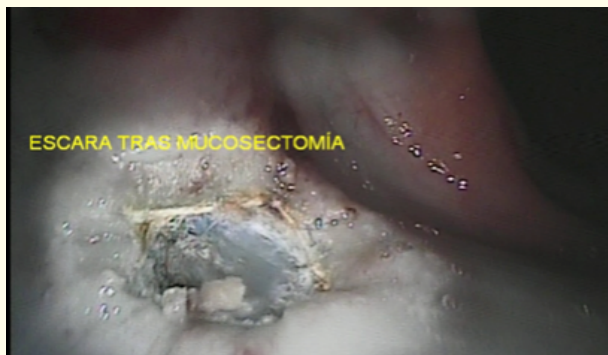

Figure 5: Wound after endoscopic mucosal resection and polypectomy.

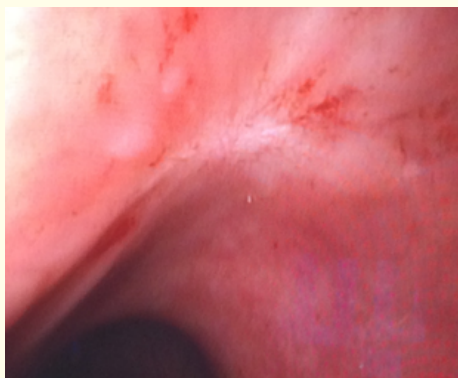


Figure 6: Scar after endoscopic mucosal resection and polypectomy.




Figure 7: Clips marking the lesion after the surgery identifying the biopsy scar.




Figure 8: Single anal port with three 5 mm trocars.

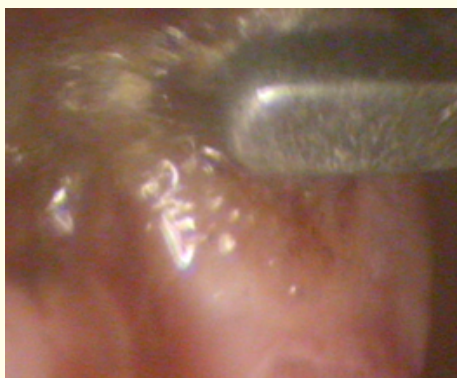

Figure 9: Tumor resection performed with electrocoagulation.

Discussion

The treatment of rectal NET is determined by the size of the primary lesion. Small lesions (< 1 cm) confined to the mucosa or submucosa (T1) can be controlled with endoscopic mucosal resection with reported rates of complete resection up to 95.2% [1,2]. The procedure may require a lower anterior resection or an abdominal-perineal resection and for lesions 1 - 2 cm in size, transanal endoscopic microsurgery may be considered [1,3].

Conclusions

Transanal endoscopic microsurgery (TEM) allows the removal of the entire local thickness of lesions up to 15 cm from the anal margin; It has the advantage of easier viewing better exposure and complete excision of the lesion with minimal morbidity. Transanal resection is a safe technique that in selected cases prevents major surgery. We consider a clinical follow-up with an annual low endoscopy for no more than 5 years.

Bibliography

1. D Mandair and Caplin ME. "Colonic and rectal NET's". *Best Practice and Research Clinical Gastroenterology* 26.6 (2012): 77-789.
2. Jernman J., et al. "The Novel WHO 2010 Classification for Gastrointestinal Neuroendocrine Tumours Correlates Well with the Metastatic Potential of Rectal Neuroendocrine Tumours". *Neuroendocrinology* 95.4 (2012): 317-324.
3. Sekiguchi M., et al. "Excellent prognosis following endoscopic resection of patients with rectal neuroendocrine tumors despite the frequent presence of lymphovascular invasion". *Journal of Gastroenterology* 50.12 (2015): 1184-1189.
4. SH Kim., et al. "Natural Course of an Untreated Metastatic Perirectal Lymph Node After the Endoscopic Resection of a Rectal Neuroendocrine Tumor". *Intestinal Research* 13.2 (2015): 175-179.

Volume 5 Issue 12 December 2018

© All rights reserved by Alexander Forero-Torres., et al.