

## **Intraosseous Lymphoma of Mandible, From Diagnosis to Resolution, A 2 Years Follow Up, A Case Report**

**Abdul-Aziz Alaqueeli\*, Muraja Aldoori, Belal Alani and Moustafa Alkhalil**

*Department of Cranio-Maxillofacial Surgery, Hamad Medical Corporation, Doha, Qatar*

**\*Corresponding Author:** Abdul-Aziz Alaqueeli, Department of Cranio-Maxillofacial Surgery, Hamad Medical Corporation, Doha, Qatar.

**Received:** November 09, 2020

### **Abstract**

Primary (Intraosseous) lymphoma of the jaw is rarely seen and it is often misdiagnosed and delayed, hence, heavily impacting the patient's life. They usually occur in immunocompromised patients.

Clinically, the manifestations are usually similar to an odontogenic tumor, cyst, or infection. Radiographically, it appears as an ill-defined radiolucent area that resembles dental related infection or pathology, odontogenic cyst, or tumour. The initial presentation is commonly followed by multiple unnecessary dental extractions and/or root canal treatments.

We present a medically fit patient diagnosed with mandible primary lymphoma and two years follow up, from March 2018 till November 2020, in the department of Cranio-Maxillofacial Surgery, Hamad medical corporation, Doha, Qatar.

**Keywords:** *B Cell Lymphoma; Intraosseous Lymphoma; Mandible Radiolucency Extra-Nodal; Chemotherapy*

### **Introduction**

Primary lymphomas in the facial skeleton are rare, it is a neoplasm of lymphoid tissue (B- or T-lymphocyte) which is the second most common malignant tumour in the head and neck after squamous cell carcinoma [1,2]. Twenty-four percent affect extra-nodal locations [3,4]. The most frequent extra-nodal sites include the gastrointestinal tract, skin, bones, and Wanderer's ring. Lymphoma's in the oral cavity are usually extra-nodal and are found either in soft tissue (peripheral), or intraosseous [1]. The most common intraoral location is the gingiva followed by the palate, while the most frequent locations in the head and neck are the tonsils followed by the parotid gland [5]. The mandible accounts for only 0.6% of isolated malignant non-Hodgkin's lymphomas [3]. The uncommon site and presentation lead to a radiological and clinical diagnostic challenge and easily misdiagnosed [6,7].

In this case report, the authors describe a rare case of lymphoma of the mandible, its workup, treatment and Two years follow up, from Nov. 2018 till Nov. 2020.

This article already approved by the medical research centre and ethical committee of Hamad Medical Corporation according to the policies and regulations of the institute.

### Case Report

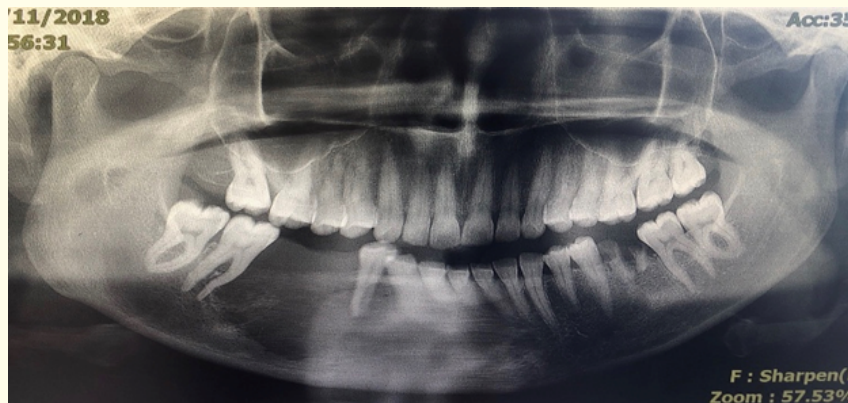A 26-year-old female presented to the department of Cranio-Maxillofacial Surgery, Hamad Medical Corporation, Qatar, with enlargement of the right side of mandible. The patient reported having a small swelling started one year ago, she had dental treatment two months before to presenting to our facility, during which her dentist removed a tooth and a cystic lesion for which no records were found, the patient then started to have pain and tenderness in the region, used oral antibiotics, but didn't improve, meanwhile, the size of the swelling started to increase rapidly, with no other symptoms.

Upon examination, the patient has a 4 \* 5 cm hard swelling over the right side of mandible with mild tenderness and multiple enlarged lymph nodes in levels 1B, no paraesthesia or dysesthesia was identified, and no B symptoms were reported.

Intra oral examination showed complete obliteration of the buccal vestibule from the canine region to the 2<sup>nd</sup> molar tooth with hard yet compressible mass with no thrill to be reported. The tumour was laying deep to an intact mucosal surface with no ulceration nor inflammation. Auscultation revealed no Bruit. A surgical consent signed by the patient, prior to biopsy aspiration was done which showed no fluid, then, tissue biopsy obtained under local anesthesia, sent to the pathologist for histopathological examination.

### Radiology findings

A panoramic x-ray was done which showed an ill-defined radiolucency occupying the premolar\molar region of the right body of mandible, extending from the canine to the second molar. No cortication seen, but displacement of the roots was noticed (Figure 1).



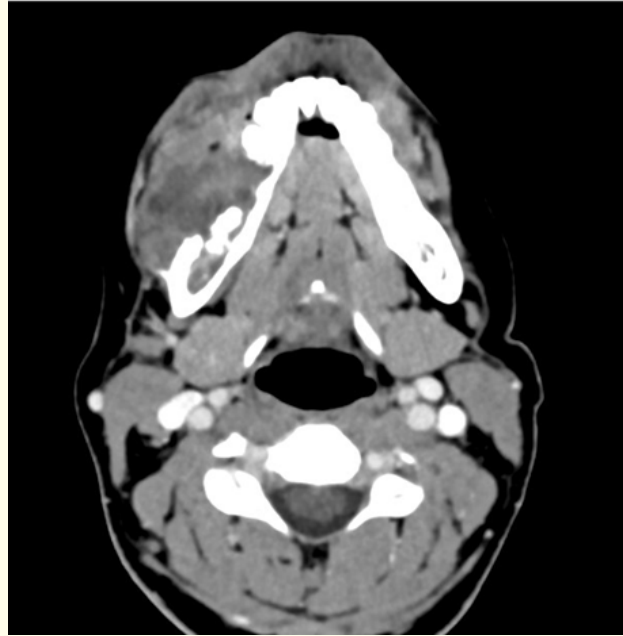
**Figure 1:** Panoramic view on the presentation.

CT scan showed evidence of large lobulated mass lesion epicentered on the right mandibular body with extensive bony erosion and bone marrow extension. The mass lesion is also exophytically projecting outside involving both gingival and buccal mucosa and extending

## Endocarditis on a Cardiac Tumor: The Importance of an Echocardiography

---

superiorly and inferiorly into the gingival buccal sulcus. The mass lesion measured 57\*27\*61 mm in AP\*TV\*CC dimensions respectively. It showed an inhomogeneous density and rounded configuration. Features keeping up with a neoplasm likely squamous cell carcinoma (Figure 2).



*Figure 2: CT axial view, before treatment.*

PET scan showed an intense uptake (SUV max up to 22.9) of the mass lesion on the right mandibular body with 6cm in maximum diameter and significant soft tissue component bulging laterally eroding the lateral cortex. Furthermore, intense uptake is seen in a maximum 16\*15 mm sized right submandibular and smaller submental lymph nodes (Figure 3 and 4).

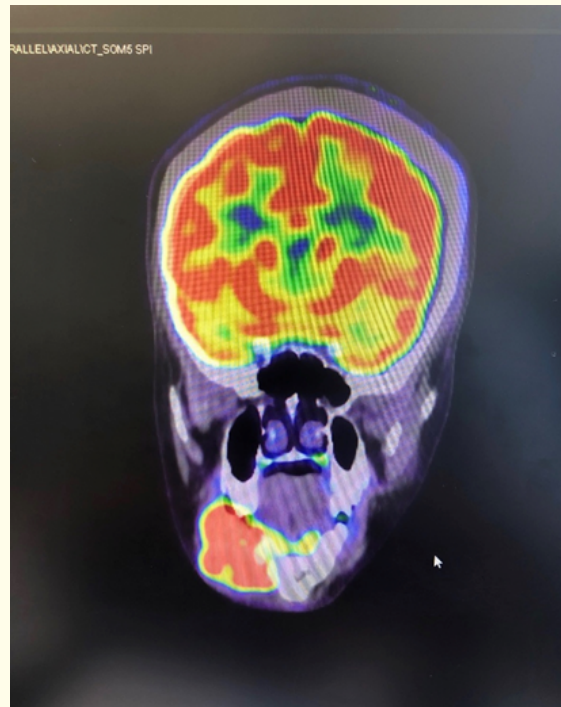
### Histopathology findings

#### Microscopic findings

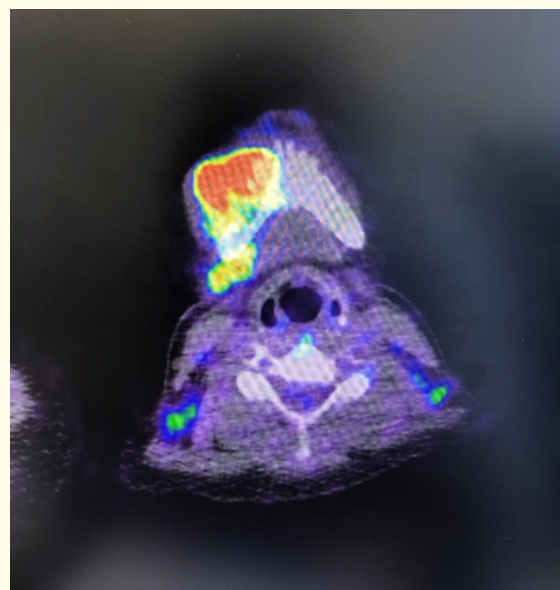
Sections showed fibrous tissue infiltrated by sheets of large lymphocytes with high NC ratio, irregular nuclear membrane, vesicular chromatin, inconspicuous nuclei, many mitoses with wide areas of necrosis, and single-cell apoptosis. No Hodgkin-like or Reed-Sternberg like cells identified.

#### Ancillary studies

By immunohistochemical stains, the diffuse process is confirmed by the negativity for C21. The large cells are B cells that are positive for CD20, CD23, CD79a, PAX-5, CD10, BCL 6, C-myc, with Ki-67 positive in 90% of cells.



**Figure 3:** PET scan coronal view, before treatment.



**Figure 4:** PET scan axial view, before treatment.

## Endocarditis on a Cardiac Tumor: The Importance of an Echocardiography

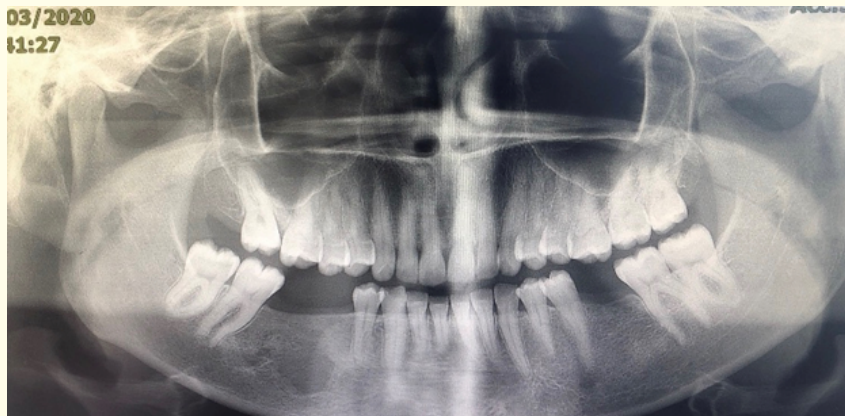---

The diagnosis was Double hit high-grade Large B-cell Lymphoma. Ann arbour classification IIA.

### Treatment

Bone marrow biopsy showed no evidence of involvement by B-cell neoplasm. Then the case discussed in Lymphoma MDT in Hamad General Hospital, Qatar, and planned for chemoradiotherapy. Accordingly, the patient received 6 cycles of DA-EPOCH (Dose-adjusted Etoposide, Prednisolone, Vincristine, Cyclophosphamide, Doxorubicin), one cycle monthly, and radiotherapy given as a 36 Gy to the right mandibular area for a total of 4 weeks.

Post-treatment we assessed the patient and follow-up imaging done to compare the tumour pre and post treatment and found to have significant improvement (Figure 5).



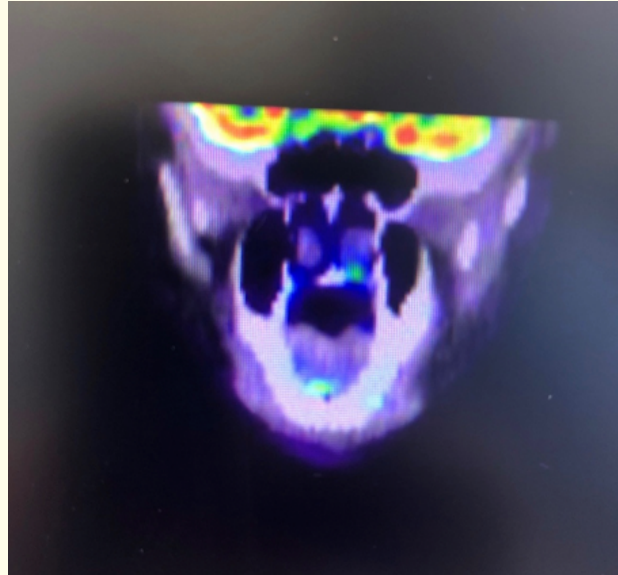
*Figure 5: Panoramic view, post-treatment.*

Last PET scan, after more than 1 year, there was no significant uptake (SUV 2.9) corresponding to the previously seen mass lesion centered on the right mandibular body with near-complete morphologic resolution as well (Figure 6 and 7). There are new sclerotic changes in the mandible, but cortical defect of the outer surface is still present. Also, complete resolution of right submandibular and submental lymph nodes. Otherwise, tracer uptake in the head and neck region is physiologic.

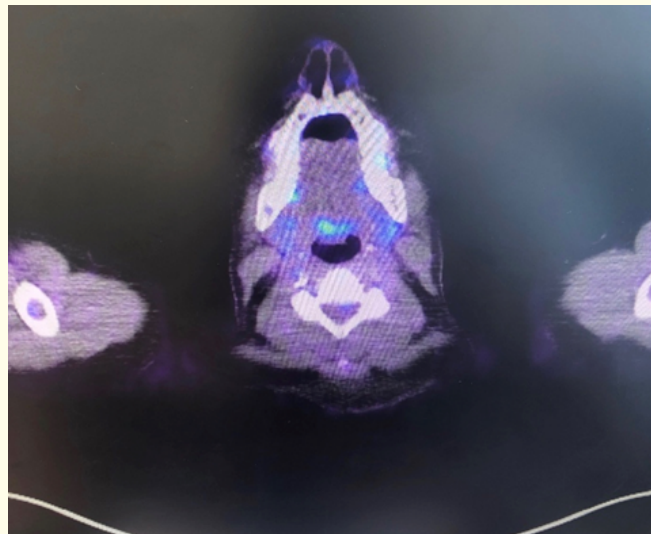
### Discussion and Conclusion

There are no particular characteristics of primary lymphoma of the mandible, neither clinically nor radiographic. Clinically, lymphoma can cause a vague and dull pain, that can be easily misdiagnosed as dental pain/periapical lesion developed from an odontogenic source of infection. Radiographically, osteolytic changes usually are only detected late in the disease as an ill-defined radiolucency quite similar to chronic osteomyelitis or a dental abscess.

Histologically, NHLs are characterized by a proliferation of lymphocytic cells commonly mistaken for a periapical granuloma or cyst [1]. The Main characteristic of jaw tumours is rapid local destruction of the bone with no obvious odontogenic infection, the clinician must be aware of the jaw tumours symptoms, which can help in early detection and treatment [8].



*Figure 6: PET scan coronal view, post-treatment.*



*Figure 7: PET scan axial view, post-treatment.*

## Endocarditis on a Cardiac Tumor: The Importance of an Echocardiography

---

Intraosseous NHL is rare, accounts for 5% of all extra-nodal lymphomas [9]. The Intra-bony lymphomas were first described by Parker and Jackson [10]. They arise from the medullary cavity and manifest as a localized, solitary lesion. Primary mandibular involvement makes up around 5% of all NHL of bone and 8% of mandibular tumours [11]. The symptoms continue to persist, despite the treatment attempts, whether pharmacologic or dental. Therefore, tissue sampling and pathological diagnosis to be done by a clinician are mandating.

Histopathologic evaluation, together with immunophenotypic and cytogenetic studies, elucidate the pattern of involvement and histologic type. The most common subtype of NHL, including primary mandibular NHL Diffuse large B-cell lymphoma (formerly known as diffuse histiocytic lymphoma) [12,13].

Imaging and whole-body CT-scan is needed to explore other locations, as NHL can involve any organ. In case of clinical signs of osseous involvement besides the mandible, a bone scan is indicated, while Fluorodeoxyglucose PET-scan provides no further information compared to CT [14].

Microscopically, DLBCLs consist of large tumour cells with large nuclei that are more than twice the size of lymphocytes. These tumour cells can have centroblastic or immunoblastic features. Centroblasts show round or irregular nuclei and membrane-bound nucleoli, but immunoblasts have round nuclei that are centrally located prominent nucleoli. DLBCLs express BCL2 in about 50% of cases. Multi-agent chemotherapy together with anti-CD20 (rituximab) is usually the treatment of choice for DLBCL [3].

To be classified as a primary NHL of bone there must be no evidence of visceral or lymphatic involvement and no distant metastases for at least 6 months following the diagnosis [16]. The most widely used system for staging lymphomas is the Ann Arbor classification, for both Hodgkin's and non-Hodgkin's lymphomas [17]. Stage I comprises lymphomas localized and confined to one side of the diaphragm with a single lesion. Stage IE indicates a single extra-lymphatic organ or site involved [18]. Stage I NHL has a 5-year survival rate of 70% and the median survival time for IE is 10 years [2,3]. The 5-year survival rate for stage IE NHL of the maxillo-mandibular region is approximately 50% [4].

This patient was diagnosed on November 2018 and then followed regularly. Her last visit was in March 2020, generally, she was well, the bony expansion completely remodelled and there was no sign of recurrence. The last panoramic view figure 5 showed almost complete resolution of the lesion with bone trabeculation formation.

Treatment for mandible intraosseous lymphoma, consists of a combination of chemo- radiotherapy [20]. Surgical treatment is limited to obtain a tissue sample (biopsy) of the lesion that is sufficient for a histopathological examination [19] and the control of the persistent or recurrent local disease [21].

In conclusion, radiolucent osteolytic and ill-defined borders, associated with pain are important features of a malignant tumour including Lymphomas. Therefore, the clinicians should be aware that, although Intraosseous lymphoma in the head and neck region is rare, it may occur in the mandible. Nevertheless, complete resolution and remodeling of the bone should be expected after the appropriate medical management.

### Conflict of Interest

The authors declare that there is no conflict of interest.

### Bibliography

1. Neville BW. "Oral and Maxillofacial Pathology". Edition 3. St. Louis, Saunders/Elsevier 16 (2009): 182-187.
2. Rooney N and Ramsay AD. "Lymphomas of the head and neck. 2; The B-cell lymphomas". *European Journal of Cancer Part B: Oral Oncology* 30B (1994): 155-159.
3. Angiero F, et al. "Primary non-Hodgkin's lymphoma of the mandibular gingiva with maxillary gingival recurrence". *Oral Oncology Extra* 42 (2006): 123-128.
4. Bachaud JM, et al. "Les lymphomes malins primitifs de la mandibule. Etude de 3 cas et revue de la littérature". *Revue de Stomatologie et de Chirurgie Maxillo-Faciale* 93 (1992): 372-376.
5. Guevara-Canales JO, et al. "Systematic review of lymphoma in oral cavity and maxillofacial region". *Acta odontológica Latinoamericana* 24 (2011): 245-250.
6. Ugar DA, et al. "Primary Lymphoma of the Mandible: Report of a Case". *Journal of Oral and Maxillofacial Surgery* 53 (1995): 827-829.
7. Gusenbauer AW, et al. "Primary lymphoma of the mandible: report of a case". *Journal of Oral and Maxillofacial Surgery* 48 (1990): 409-415.
8. Regezi JA, et al. "Oral Pathology: Clinical Pathologic Correlations". St. Louis, Saunders/Elsevier 9 (2008): 225-240.
9. Toliuis V, et al. "Primary non-Hodgkin's lymphoma of bone". *Medicina* 40.4 (2004): 379-385.
10. Parker F and Jackson H. "Primary reticulum cell sarcoma of bone". *Surgery, Gynecology and Obstetrics* 68 (1939): 45-53.
11. Huvos AG. "Bone tumours. Diagnosis, treatment, and prognosis". 2nd edition. Philadelphia, London, Toronto: WB Saunders and Co (1991): 625-637.
12. Pazoki A, et al. "Primary non-Hodgkin's lymphoma of the Jaws: report of four cases and review of the literature". *Journal of Oral and Maxillofacial Surgery* 61 (2003): 112-117.
13. Armitage J and Weisenburger D. "New approach to classifying Non-Hodgkin's lymphomas: clinical features of the major histologic subtypes". *Journal of Clinical Oncology* 16 (1998): 2780.
14. Trost O, et al. "Lymphome Bmandibulaire isolé révélé par une anesthésie du nerf alvéolaire inférieur". *Revue de Stomatologie et de Chirurgie Maxillo-Faciale* 110 (2009): 101-104.
15. Barnes L. "Surgical Pathology of the Head and Neck, edition 3". New York, Informa Healthcare (2009).
16. Steinbacher DM and Dolan RW. "Isolated non-Hodgkin's lymphoma of the mandible". *Oral Oncology Extra* 42 (2006): 118-119.



17. Kolokotronis A., *et al.* "Local-ized B-cell non-Hodgkin's lymphoma of oral cavity and maxillofacial region: A clinical study". *Oral Surgery, Oral Medicine, Oral Pathology, Oral Radiology, and Endodontology* 99 (2005): 303-310.
18. Ishimaru T., *et al.* "Hodgkin's Lymphoma of the Mandibular Condyle: Report of a Case". *Journal of Oral and Maxillofacial Surgery* 63 (2005): 144-147.
19. Longo F., *et al.* "Primary non-Hodgkin's lymphoma of the mandible Report of a case". *International Journal of Oral and Maxillofacial Surgery* 33 (2004): 801-803.
20. Yamada T., *et al.* "Enlargement of mandibular canal without hypesthesia caused by extranodal non-Hodgkin's lymphoma". *Oral Surgery, Oral Medicine, Oral Pathology, Oral Radiology, and Endodontology* 89 (2000): 388-392.
21. Steinbacher DM and Dolan RW. "Isolated non-Hodgkin's lymphoma of the mandible". *Oral Oncology Extra* 42 (2006): 187-189.

**Volume 5 Issue 1 January 2021**

**©All rights reserved by Abdul-Aziz Alaqeeli, *et al.***