

Results of Management of Penetrating injuries of the Spine in Northern Nigeria: A Case Series

Shobode MA*, Ekundayo OO, Abubakar K, Oyenusi AS, Waheed TA, Abubakar MK, Ibraheem GH and Onuminya JE

National Orthopaedic Hospitals, Dala, Kano, Nigeria

***Corresponding Author:** Shobode MA, Spine Surgery Unit, Department of Clinical Services, National Orthopaedic Hospital, Dala, Kano, Nigeria.

Received: March 26, 2021; **Published:** April 30, 2021

Abstract

Background: Missile and non- missile penetrating injuries of the spine are rare. We present a case series of 3 patients managed at our facility with penetrating injuries of the spine in the last 5 years.

Objective: To highlight the need for urgent surgical intervention in patients with worsening neurological signs following penetrating injuries to the spine.

Materials and Methods: Three patients presented within the study period (January 2016 to January 2021). There were 2 males and 1 female. Orthogonal plain radiograph was sufficient to define the location and level of injury. The injuring objects were made of ferromagnetic materials so none of the patients had an MRI scan pre-operatively. CT myelography was also not done as none of the patients could afford it. ASIA Impairment Scale was used as outcome measures.

Results: 1 had a missile injury (arrow) while 2 had non missile penetrating injuries (knife and scissors). All three had neurological impairment and presenting in spinal shock. The sub-axial cervical spine and the thoracolumbar spine were affected. All presented within 24 hours of injury. All three had emergency surgical retrieval of the injuring objects with one post-operative death from complications of aspiration pneumonitis recorded. The remaining two had significant post-operative neurological recovery and discharged home as ASIA D.

Conclusions: Penetrating injuries with neurologic impairment are rare. Early surgical intervention with retrieval of the impaling objects is recommended.

Keywords: Penetrating Injury; Missile/Non Missile Injury; Spinal Cord

Introduction

Missile and non- missile penetrating spine injuries (NPSI) are rare. With rising incidences of civil strife, insurrection, banditry and terrorist activities in the Northern region of Nigeria, these injuries are seen at an increasing rate. Sadly, children and teenagers are often caught in the middle of these attacks. We report three cases of these injuries caused by three different weapons. All three patients pre-

sented in spinal shock within 24 hours. One case was accidental while the other two were assaulted. All had the injuring objects retained in the spine at presentation. They had emergency wound exploration and retrieval of the objects with no wound complications. With the exception of one mortality, the remaining two were discharged home ambulant (ASIA D).

Case 1

A 28 year old male military officer who presented with weakness of all limbs following a scissors stab injury to the neck.

He was attacked by an ‘aggrieved’ man in a bar while watching a game of soccer. An altercation about unfair officiating in the soccer match had ensued prior to the assault which riled the assailant.

No injuries to other parts of his body. Entry point was located 3 cm behind the superior border of the Sternocleidomastoid muscle in the left posterior cervical triangle.

Plain radiographs showed a pair of scissors abutting on the C3/C4 canal space.

He presented within 6 hours in spinal shock with absent bulbocavernosus reflex. He was resuscitated with crystalloids and had emergency decompressive laminectomy and retrieval of the injuring object (scissors). Surgery was done under general anaesthesia with endotracheal intubation. The spine was approached via a posterior midline incision with left unilateral muscle strip dissection and the course of the scissors traced and gently dissected. Hemi-laminectomy of C3 and C4 was done. Intramedullary penetration of the scissors tips was confirmed intra-operatively. Dural tear was repaired.

Wound was irrigated and closed in layers over a drain. Duration of surgery was 1 hour. Drain was taken out on the first postoperative day. He was admitted in the intensive care unit but continued to deteriorate. He died a week after surgery from complications of aspiration pneumonitis.

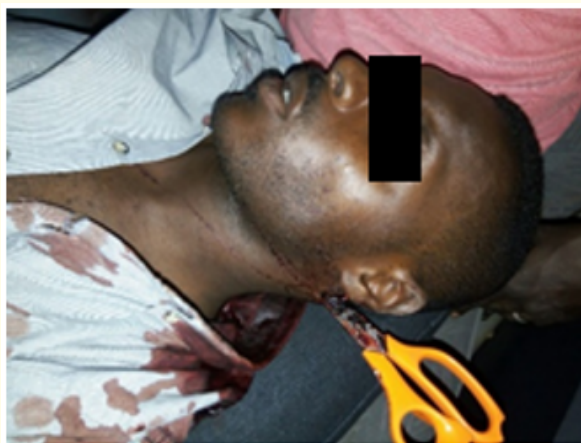

Figure 1a

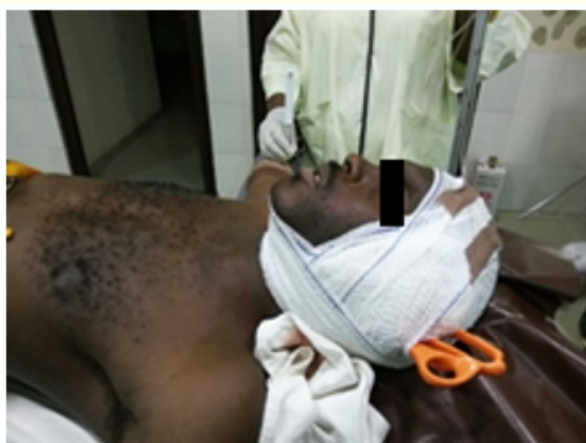

Figure 1b

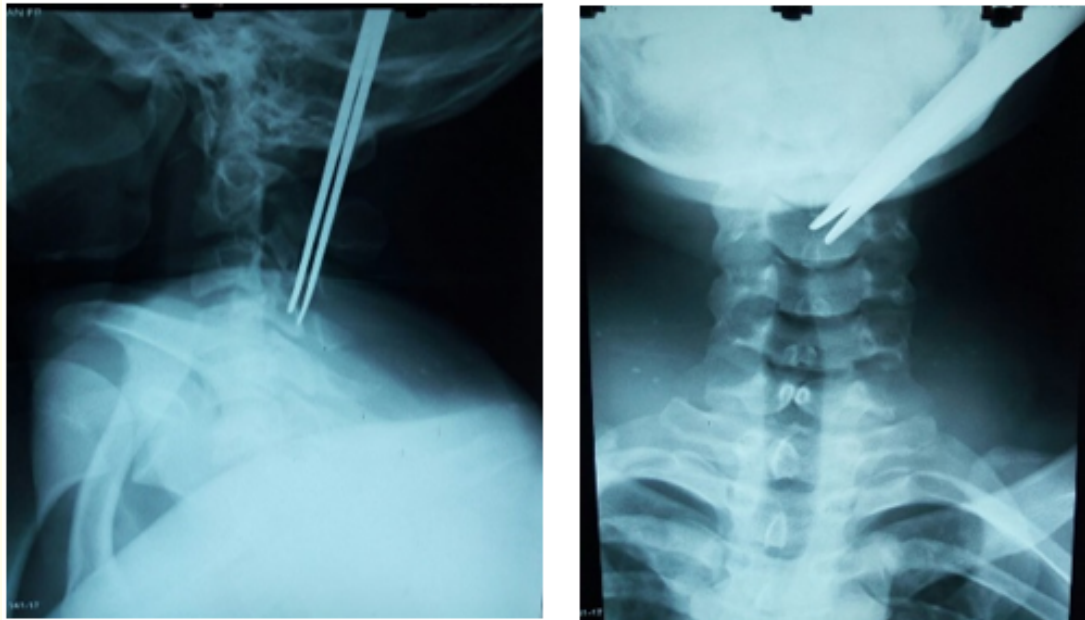


Figure 1c

Figure 1d

Figure 1: Preoperative image with retained scissors in the neck. Preoperative Lateral and Antero-posterior plain radiographs showing the tips of the scissors in the cervical spinal canal.

Case 2

A 10 year old herder who was attacked by cattle rustlers on the outskirts of Jigawa state, Northern Nigeria.

He was shot in the back with an arrow while attempting to escape from his assailants. No injury to other body parts.

He developed sudden onset inability to move his lower limbs and was brought in within 24 hours of the attack in spinal shock. He had an arrow lodged in the mid-back within 5cm to the right of the midline. He presented in spinal shock with absent bulbocavernosus reflex. He was resuscitated with crystalloids and had tetanus prophylaxis.

Orthogonal plain radiographs of the lumbar spine done showed metallic opacity within the spinal canal at T10/T11.

Consent was taken for an emergency decompressive laminectomy. He was intubated in a left lateral position as he was unable to lie supine.

He was thereafter positioned prone on bolsters under general anaesthesia with endotracheal intubation.

The spine was approached via a posterior midline incision with right unilateral muscle strip dissection. Lamina fracture of T11 was noted and a right hemi-laminectomy was done. Intramedullary penetration by the injuring agent was confirmed intra-operatively.

The arrow was retrieved by cutting it in situ after dislodging it from the canal to avoid further injury to the cord and soft tissues by the wedge-shaped arrowhead. Dural tear was repaired.

Spine stabilization with pedicle screw - rod instrumentation was not necessary as there was no demonstrable instability intra-operatively. Wound was irrigated and closed in layers over a drain. Duration of surgery was 45 minutes. Drain was taken out on the first postoperative day.

He had remarkable improvement of neurology and commenced ambulation with a walking frame and lumbar support on the second postoperative day. He was discharged 2 weeks after surgery with ASIA IS grade D and continued to make sustained neurological improvement at 1 year post-injury.

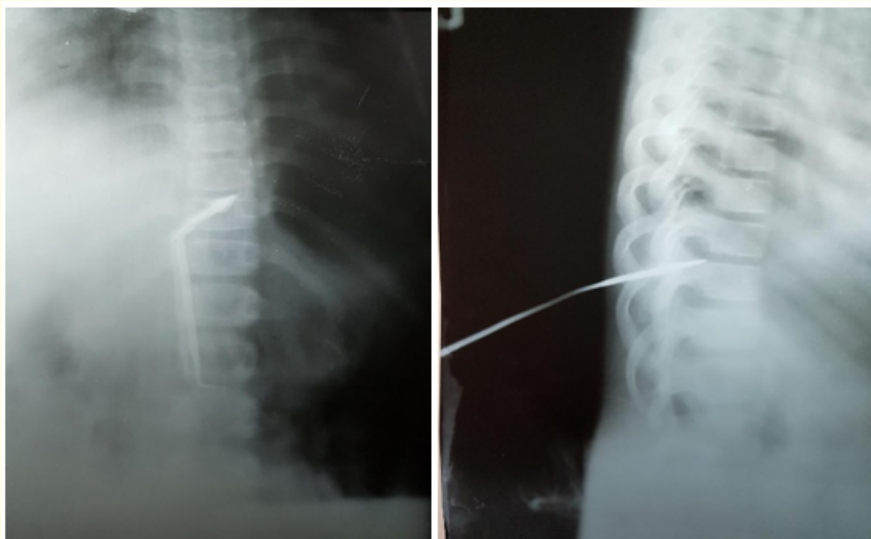


Figure 2a

Figure 2b

Figure 2: Antero-posterior and lateral plain radiographs of the thoracic spine showing the arrow lodged in the T10/T11 spinal canal.

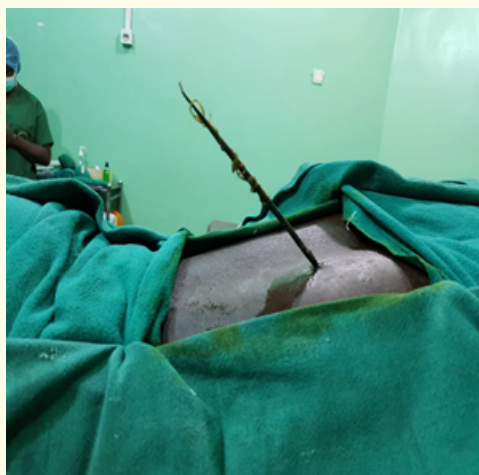

Figure 2c: Positioning of the patient with the arrow in situ.

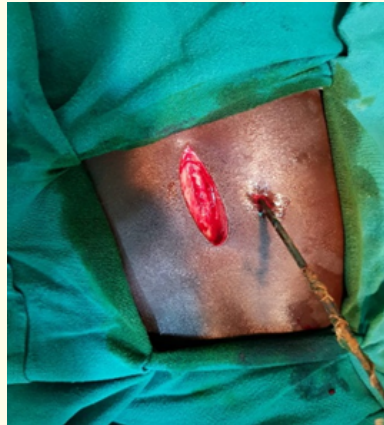

Figure 2d: Shows the posterior midline incision separate from the entry wound of the arrow.

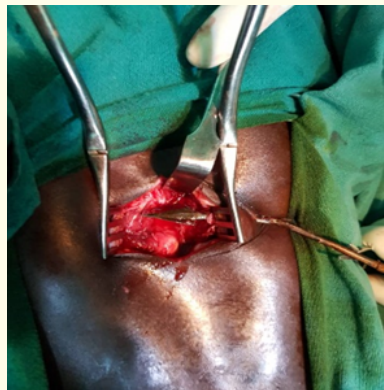

Figure 2e: Shows the wedge-shaped tip of the arrow after careful dissection from the spinal cord.

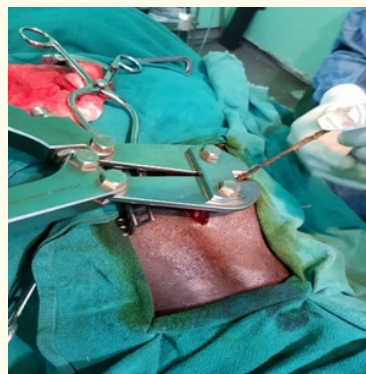


Figure 2f: The arrow was cut in-situ to prevent the wedge-shaped tip from causing further damage to soft tissue.

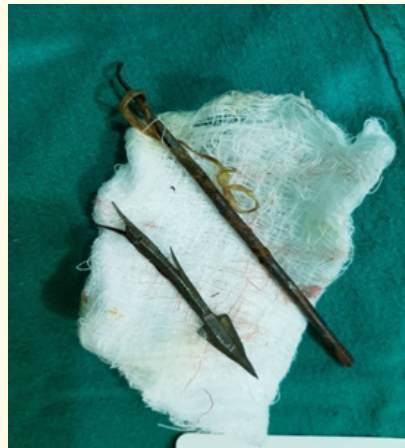

Figure 2g: The arrow after retrieval.

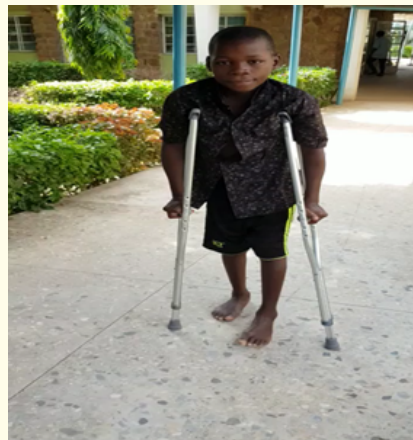

Figure 2h: Shows the patient standing with bilateral axillary crutches 48hrs after the surgery.

Case 3

A 13 year old girl that presented with inability to use both lower limbs following a penetrating back injury. She tripped and fell on her back with a bag containing a knife on her way to the farm. She was brought in within 8 hours of the injury in spinal shock.

Plain radiographs and CT scan showed the knife abutting on T11 vertebral body. She was worked up for and had an emergency decompressive laminectomy. She was intubated in a left lateral position and thereafter placed prone on bolsters under general anaesthesia.

The spine was approached via a posterior midline incision with bilateral muscle strip dissection with the knife path incorporated in the wound. T10 and T11 hemi-laminectomy was done.

The knife was retrieved after dislodging it from canal and vertebral body. There was a 15 mm rent in the dura which was repaired.

Wound was irrigated and closed in layers over a drain. Duration of surgery was 2 hrs.

She was discharged as ASIA C.



Figure 3a: The sack containing the knife.

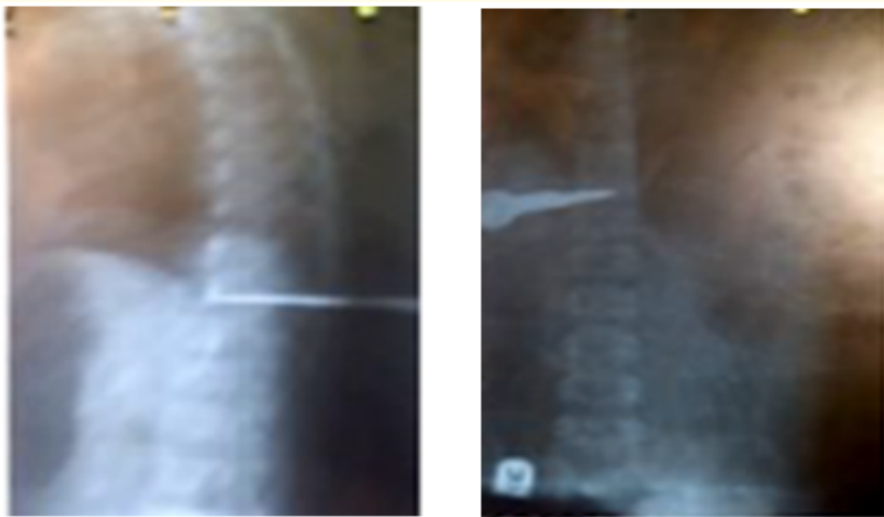


Figure 3b and 3c: Pre-operative Antero-posterior and lateral plain radiographs showing the knife lodged in the spinal canal at T11.

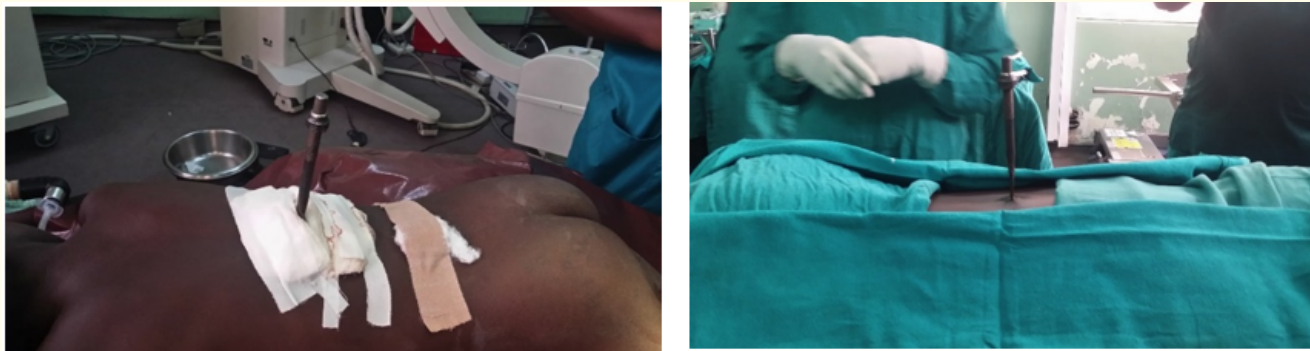

Figure 3d and 3e: Positioning for surgery and draping with the knife in situ.

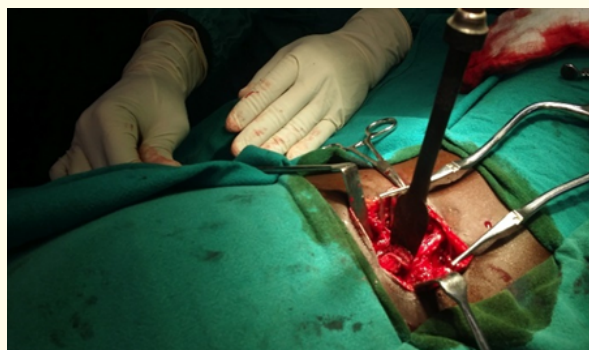


Figure 3f: Dissection of the knife free from the spine.

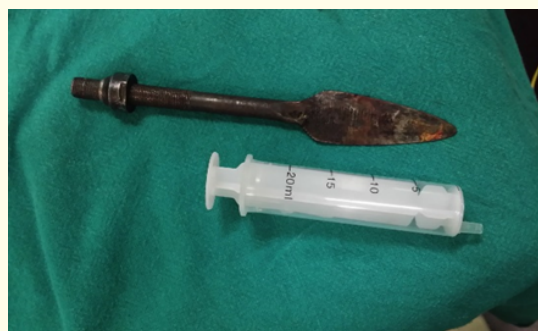

Figure 3g: The knife after retrieval.

Discussion

Acute traumatic spine injuries are common orthopaedic emergencies worldwide, usually resulting from high energy blunt trauma [1]. Road traffic injuries account for the highest percentage of the patho-mechanics globally [2,3]. However, owing to the resurgence of armed conflicts, insurgency, banditry, terrorism and ethno-religious strife in parts of northern Nigeria, there is an increase in certain injury mechanisms and injury characteristics noted amongst patients seen in the region.

Spinal column injuries affect, to varying degrees, soft tissue, disco-ligamentous system, bony vertebra or the neural elements [3]. These may be isolated spinal column injury but more commonly associated with neurological involvement. They result in debilitating disabilities/neurological impairments, deformities and even significant mortalities.

Penetrating injuries, although rare [13,16], result mainly from missile wounds which are commonly inflicted by gunshots [4]. The non-missile penetrating variants are even rarer and the majority of these injuries result from stab with knives, sharp rods and other metallic objects. The assailants rarely leaves the injuring weapon in the body of the victims. Very few cases of retained objects have been reported in the literatures [5].

As with most cases of assault, the assailants go in for the kill and the upper part of the body, which is often the most accessible and within the reach of the assailants, is therefore the more commonly affected. The thoracic region is predominantly affected (54 - 63%) followed by the cervical (about 30%) with the lumbosacral region coming a distant third (7%) [5]. The injuries are often associated with no spinal instability even after surgical intervention. None of the three cases required an internal fixation.

The literature describes three spinal cord injury patterns commonly resulting from these injuries. Most patients present with incomplete cord injury [16]. Brown Sequard syndrome is the predominant type of lesion seen in stab injuries as the assailants often attack from the sides of the victims. Most will present in spinal shock often making categorization of the lesion difficult post-operatively as the surgeon is unsure if the injury is complete at presentation or made complete by his intervention. A few patients however present with no neurological deficit. There is a tendency for the patients to present early as the sight of an object lodged in the spine is quite frightening for the patient and those around him at the time. In these case series, all three patients presented within 48 hours for treatment.

There is paucity of information about the management guidelines for these injuries with most researchers describing their experiences with different methods of care and variable outcomes [6,4,16]. The patients should be managed using the Advanced Trauma Life Support protocol [16]. Fluid or blood products resuscitation should be instituted as required. Transportation of the patients is often a challenge as there is the risk of driving the object further into the spinal canal. This is often the case in underserved regions of the world (Third world countries) where ambulance services and pre-hospital care is suboptimal. Urgent orthogonal plain radiographs and/or Computerized Tomographic Scan are often sufficient to delineate and localize the object in most instances [15]. The use of Magnetic Resonance Imaging compatibility is of a huge concern as most of the weapons used are ferromagnetic.

The choice of care is never in doubt [12,13]. A retained weapon must be removed unlike when the weapon is withdrawn by the assailant. Positioning for anaesthesia is also a challenge. Most get intubated in prone or lateral decubitus position. A complete assessment is made to detect injury to major vascular structures, bronchi and other visceral organs. Attempts at removal or manipulation of the retained weapon before a thorough clinical evaluation including appropriate imaging studies must be discouraged as it could provoke severe haemorrhage and more neural/soft tissue damage.

Most researchers agree that early intervention is key and that the likelihood of neurological recovery is better compared to other varieties of spinal cord injury [10,12]. Surgical retrieval of the weapon, thorough debridement, exploration and irrigation of the wound and

antibiotics cover are important steps in the management of these patients. This is particularly important in patients with incomplete cord injury, spinal shock, persistent cerebrospinal fluid leak and retained foreign object in the spine. Like in other cases of spinal cord injury, the use of steroid is controversial and might be associated with increased infection risk [6-9].

Conclusion

Penetrating spine injuries are uncommon and management guidelines are unclear and at best, anecdotal¹¹. There is however a consensus that those with retained foreign object should have emergency wound exploration to retrieve the object [12]. The three patients presented in this series had retained injuring objects and therefore had emergency wound exploration and decompressive laminectomy to retrieve the objects and give the spinal cord a chance for recovery. Steroid use is controversial and a course of antibiotics cover must be instituted based on local antibiotics use guidelines as the risk of infection is high. Early presentation and treatment is key to good outcome.

In our series, all three patients presented early and also had surgical intervention within 12 hours of arrival in the emergency room. None of the three patients had steroid prescription in any form. All patients with penetrating spine injuries should be monitored and followed up for a period of time as late neurological deficit including residual/progressive spasticity may develop. Late presentation/intervention may lead to irreversible neurological damage.

Bibliography

1. Van Den Berg ME., *et al.* "Incidence of spinal cord injury worldwide: a systematic review". *Neuroepidemiology* 34 (2010): 184-192.
2. El-Khoury GY and Whitten CG. "Trauma to the upper thoracic spine: Anatomy, biomechanics, and unique imaging features". *The American Journal of Roentgenology* 160 (1993): 95-102.
3. Price C., *et al.* "Epidemiology of traumatic spinal cord injury and acute hospitalization and rehabilitation charges for spinal cord injuries in Oklahoma, 1988-1990". *American Journal of Epidemiology* 139 (1994): 37-47.
4. Shahlaie K., *et al.* "Non-missile penetrating spinal injury. Case report and review of the literature". *Journal of Neurosurgery Spine* 4 (2006): 400-408.
5. Thakur RC., *et al.* "Non-missile penetrating injuries of the spine". *Acta Neurochirurgica* 113 (1991): 144-148.
6. Heary RF., *et al.* "Thoracolumbar infections in penetrating injuries to the spine". *Orthopedic Clinics of North America* 27 (1996): 69-81.
7. Levy ML., *et al.* "Use of methylprednisolone as an adjunct in the management of patients with penetrating spinal cord injury: Outcome analysis". *Neurosurgery* 39 (1996): 1141-1149.
8. Heary RF., *et al.* "Steroids and gunshot wounds to the spine". *Neurosurgery* 41 (1997): 576-583.
9. Bono CM and Heary RF. "Gunshot wounds to the spine". *The Spine Journal* 4 (2004): 230-240.
10. Wallace DJ., *et al.* "Management of non-missile penetrating spinal injury". *Neurosurgical Review* 42.4 (2019): 791-798.
11. Yoon J., *et al.* "Non missile penetrating spinal injury". *Journal of Clinical Neuroscience* 67 (2019): 239-243.
12. Bhatoe HS and Singh P. "Missile injuries of the spine". *Neurology India* 51.4 (2003): 507-511.

13. Fiani B., *et al.* "Nonmissile penetrating spinal injuries: Mechanisms, expectations, and management". *Surgical Neurology International* 11 (2020): 406.
14. Agarwal P., *et al.* "Stab wound to the intramedullary spinal cord: Presurgical and surgical management options for a retained blade to optimize neurological preservation". *Surgical Neurology International* 7.42 (2016): S1096-S1098.
15. Hope N., *et al.* "Penetrating neck injuries: the point of plain films". *Clinical Case Reports* 4.2 (2016): 216-218.
16. Nowicki JL., *et al.* "Penetrating neck injuries: a guide to evaluation and management". *Annals of the Royal College of Surgeons of England* 100.1 (2018): 6-11.

Volume 5 Issue 5 May 2021

©All rights reserved by Shobode MA., *et al.*