

Real Time 3 D Transesophageal Echocardiography Assisted Closure of Mitral Leaflet Perforation

Shailendra K Motwani^{1*}, Navneet Mehta², Ravindra S Rao³ and Ajeet Bana⁴

¹Associate Consultant, Cardiac Anesthesiology, Eternal Hospital, Jaipur, Rajasthan, India

²Director and Head of Department Cardiac Anesthesiology, Eternal Hospital, Jaipur, Rajasthan, India

³Consultant, Interventional Cardiology, Eternal Hospital, Jaipur, Rajasthan, India

⁴Chief of Cardiac Surgery; Chairman, Cardiac Sciences, Eternal Hospital, Jaipur, Rajasthan, India

***Corresponding Author:** Shailendra K Motwani, Associate Consultant, Cardiac Anesthesiology, Eternal Hospital, Jaipur, Rajasthan, India.

Received: July 02, 2020; **Published:** July 31, 2020

Abstract

Real Time 3 D Transesophageal Echocardiography helps in creation of high quality, accurate images of the various cardiac structures.

Three dimensional echocardiography is an invaluable tool to accurately diagnose and guide the management of various mitral valve diseases and their complications.

Precise localization of mitral valve leaflet perforation can be very challenging on 2 D echo. It may be particularly difficult to identify the precise site of perforation with respect to leaflet.

Real time 3 D Echo helps to accurately locate the site of the lesion and improve the feasibility of successful intervention.

In our case report we will demonstrate the role of 3 D echo to accurately localize the site of perforation and its usefulness in non-surgical closure. We will also demonstrate the outcome and follow up of the patient.

Keywords: Real Time 3 D Transesophageal Echocardiography; Mitral Regurgitation; 2 D Echo

Introduction

Mitral regurgitation is a complex yet common valvular disease, which requires careful assessment to elucidate the etiology.

Precise localization of mitral valve leaflet perforation can be very challenging on 2 D echo. Real Time 3 D Transesophageal Echocardiography creates high quality, accurate images of the various cardiac structures. It is an invaluable tool to accurately diagnose and treat various mitral valve diseases and their complications. It helps to accurately locate the site of the lesion and improve the feasibility of successful intervention.

In our case report we revealed the role of 3 D echo to accurately localize the site of perforation and its usefulness in non-surgical closure.

We also followed up the immediate and long term outcome of the patient.

Case Report

Our patient was a 34 year old female. The patient presented to us with complaints of breathlessness on minimal exertion and edema feet on and off for about 20 years. She was a known case of Valvular heart disease since 1992. She had history of hypothyroidism. She was NYHA III. Auscultation revealed blowing, holosystolic murmur which was best heard in axilla. Her Pro BNP was 1100. The echocardiography revealed severe eccentric MR with isolated AML (A2) perforation; Dilated LA; LVEF 55%; No RWMA. Other valves/structures were normal.

After thorough pre procedural assessment the patient was planned for closure of the mitral valve perforation with Amplatzer Vascular Plug II. General anaesthesia was given with all considerations for mitral regurgitation and hypothyroidism. Transesophageal echocardiography probe was inserted. Procedure was completed by the cardiology team under the guidance of 3D TEE and the perforation was closed with Amplatzer Vascular Plug II size 8. After the confirmation from the cardiologist regarding the success of the procedure the patient was extubated on table and shifted to HDU for further care and then to the ward as per protocol. The post procedure period was uneventful and the patient was discharged home with follow up instructions as given by the cardiologist. The patient had an uneventful recovery. The follow up was done by the cardiology team with echo and MRI images as shown below.

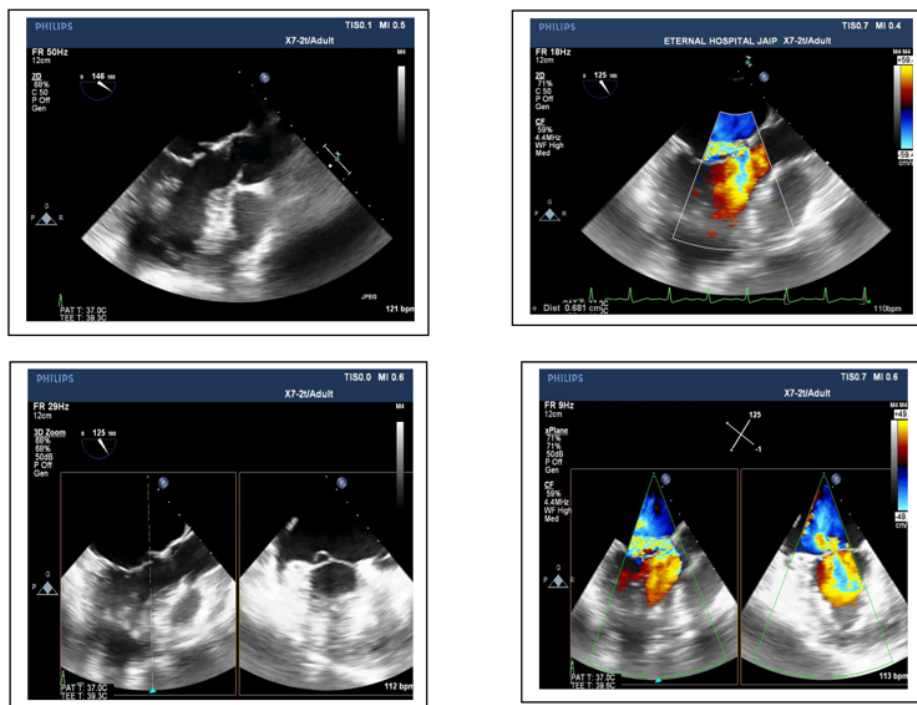


Figure 1: Pre procedure images showing severe MR.

Discussion

For patients with significant mitral valve disease who require intervention, multiplane transesophageal echocardiogram (TEE) has an important role in percutaneous cardiovascular procedures. The advantages include real time imaging, portability, and availability, which

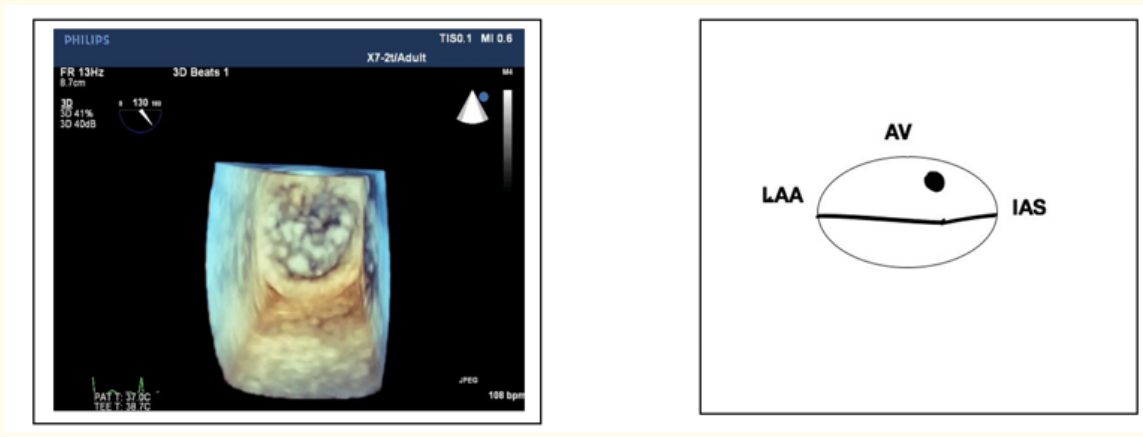


Figure 2: Images showing the Location of AML (A2 scallop) perforation.

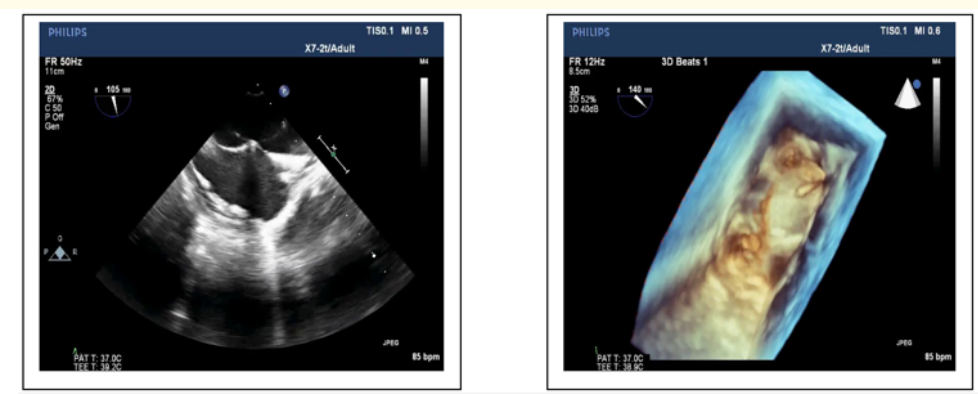
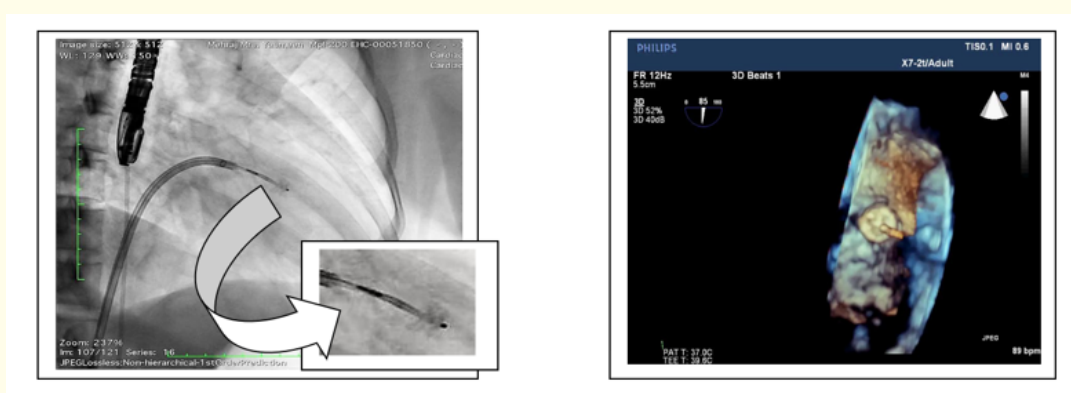

Figure 3: Images showing the passage of catheter through the perforation.



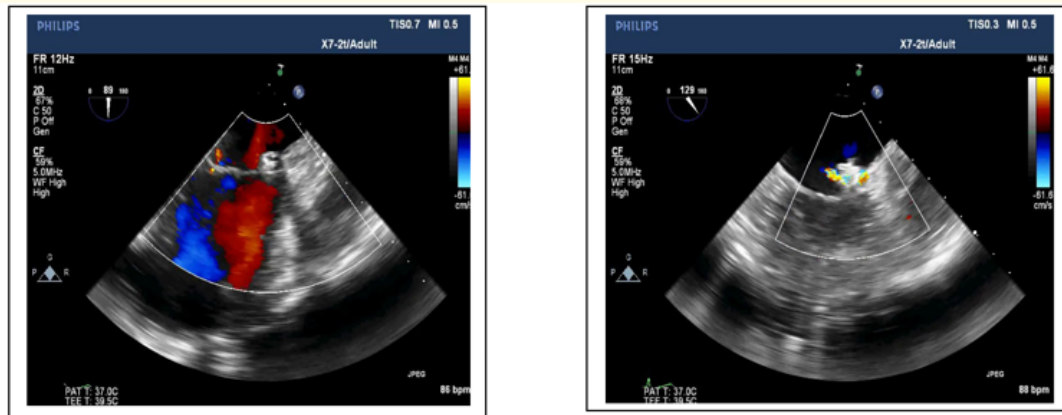


Figure 4: Images with the Amplatzer vascular plug in AML.

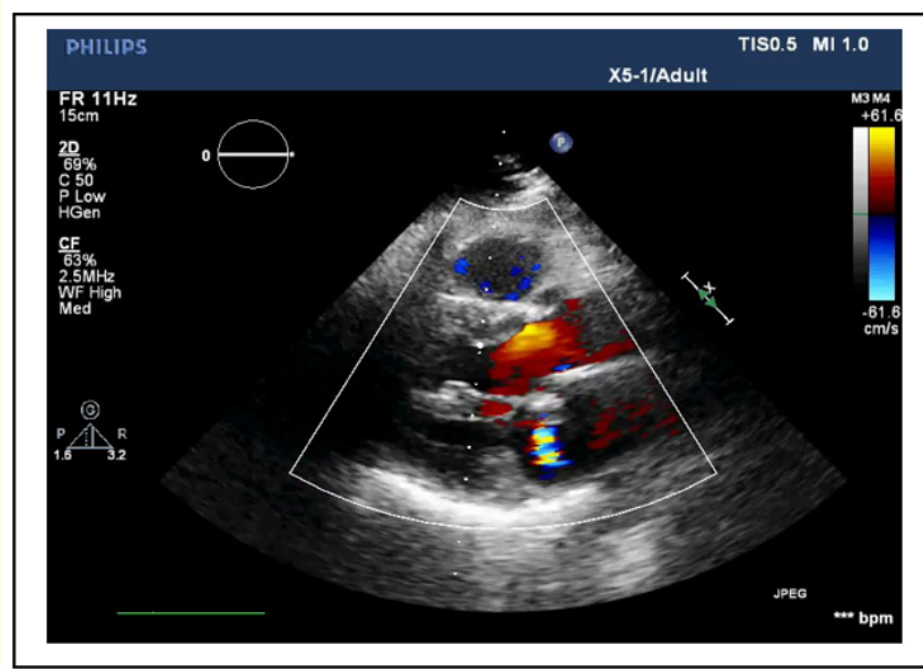


Figure 5: Did the device remain stable?

make it an effective imaging modality. The echocardiographer should have the knowledge and expertise to assess mitral valve disease and convey the findings to the operator preoperatively.

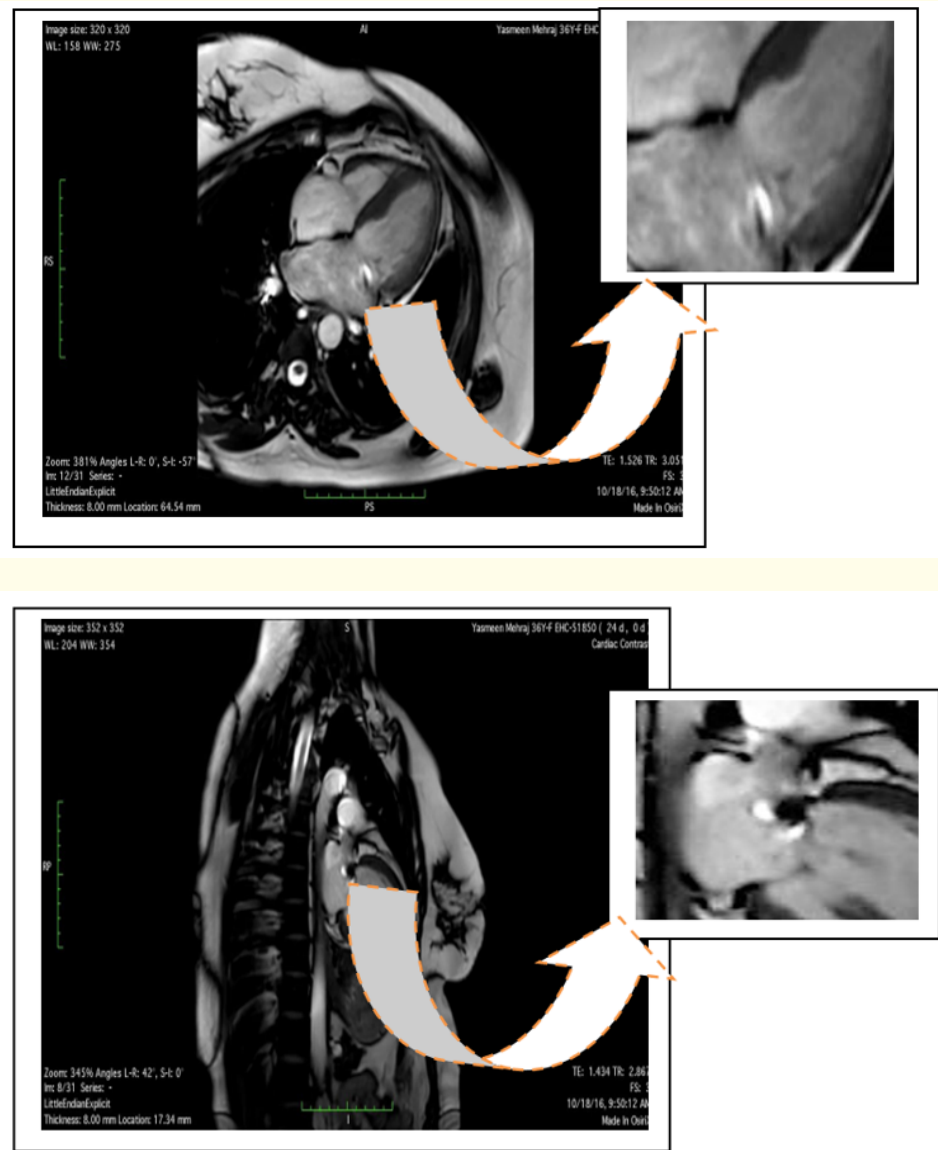


Figure 6: Echo and MRI images at one month follow up.

Cam Tu Nguyen, *et al.* (2011) demonstrated that echo guidance of transcatheter procedures for valve interventions improves device delivery and patient safety and the outcomes by allowing the operator to identify the location of catheters and avoiding unnecessary complications [1].

The use of 3D echocardiography is complimentary to 2D multiplane TEE and can overcome some of the limitations of 2D multiplane TEE. The addition of 3D TEE is crucial in evaluation of patients undergoing mitral valve surgery and often provides clarity in this regard, helping to determine the feasibility of intervention.

Nishath Quader, *et al.* (2014) used 2D and 3D echocardiography for the pre-operative assessment of mitral regurgitation patient and recommended that 3D echocardiography can overcome some of the limitations of 2D multiplane TEE and thus is crucial in evaluation of patients undergoing mitral valve surgery [2].

Marija Vukicevic, *et al.* (2016) used 3D printed modelling of the mitral valve for catheter based structural interventions and demonstrated that patient-specific mitral valve models can be reconstructed from Clinical 3D transesophageal echocardiography and computed tomography images and fabricated using the multi-material 3D printing technology and catheter-based repair devices could be evaluated within specific patient 3D printed valve geometry [3].

Conclusion

The use of 3D Echocardiographic guidance provides detailed information on anatomy, details of the adjacent structures and intraprocedural instrument position, thus results in improvement in procedural efficacy, safety and improved patient outcomes.

Bibliography

1. Cam Tu Nguyen, *et al.* "Echocardiographic guidance for diagnostic and therapeutic percutaneous procedures". *Cardiovascular Diagnosis and Therapy* 1.1 (2011): 11-36.
2. Nishath Quader, *et al.* "Two and three dimensional echocardiography for pre-operative assessment of mitral valve regurgitation". *Cardiovascular Ultrasound* 12 (2014): 42.
3. Marija Vukicevic, *et al.* "3D Printed Modelling of the Mitral Valve for Catheter-Based Structural Interventions". *Annals of Biomedical Engineering* 45.2 (2016): 508-519.

Volume 4 Issue 8 August 2020

©All rights reserved by Shailendra K Motwani, *et al.*