

The Great Role of Lung U/S in Management of COVID-19 Pneumonia

Walid Shibl^{1*} and Ibrahim El Alfy²

¹ICU Consultant, QCH, Ministry of Health, Saudi Arabia

²ICU Consultant Head of Department DMC, Ministry of Health, Saudi Arabia

***Corresponding Author:** Walid Shibl, ICU Consultant, QCH, Ministry of Health, Saudi Arabia.

Received: May 11, 2020; **Published:** June 24, 2020

Abstract

Lung U/S is a cheap, safe, repeatable and now available in most of critical care areas, for many years it reveals a great role in management of pneumonia. COVID-19 pneumonia is a viral pneumonia with different types of presentation, Lung U/S can has a great role in management of COVID-19 pneumonia, we present a case report of 42-year-old male COVID-19. Patient admitted to our ICU because of severe ARDS with PO₂ 46 mmgh on 15L NRM and we did Lung U/S using 10 segments method by phase array probe on several occasions [on admission, after any change in management, after deterioration of respiratory status and before weaning] and we found lung U/S was very helpful in patient management, it helps in several ways, first, in diagnosing the phenotype and assessment of severity, second, in evaluating the response to treatment and last it has a great role in predicting successful weaning from mechanical ventilator.

Keywords: Lung U/S; COVID-19; Pneumonia

Introduction

In COVID-19 pneumonia, lung abnormalities may develop before clinical manifestations and nucleic acid detection, experts have recommended early chest computerized tomography (CT) for screening suspected patients [1].

The high contagiousness of SARS-CoV-2 and the risk of transporting unstable patients with hypoxemia and hemodynamic failure make chest CT a limited option for the patient with suspected or established COVID-19. Lung ultrasonography gives the results that are similar to chest CT and superior to standard chest radiography for evaluation of pneumonia and/or adult respiratory distress syndrome (ARDS) with the added advantage of ease of use at point of care, repeatability, absence of radiation exposure and low cost [2].

Quian., *et al.* performed lung ultrasonography on 20 patients with COVID-19 using a 12-zone method [3] with these characteristic findings:

1. Thickening of the pleural line with pleural line irregularity;
2. B lines in a variety of patterns including focal, multifocal, and confluent;
3. Consolidations in a variety of patterns including multifocal small, non-translobar, and translobar with occasional mobile air bronchograms;
4. Appearance of A lines during recovery phase;
5. Pleural effusions are uncommon.

We did a critical care U/S including lung and diaphragmatic U/S for a 42-year-old male patient with severe COVID-19 Pneumonia, on admission, Lung U/S revealed thick pleura, condense B-Lines in almost all lung areas, subpleural consolidation and spare areas with A-Lines, we found good diaphragmatic excursion 2.63 cm with M-mode U/S, this good diaphragmatic swings which denote a good compliance may give a clue about phenotyping of COVID-19 pneumonia, good excursion go with L-phenotype with good compliance, moreover, F/U Lung U/S was very helpful in management of the patient during his stay in ICU until weaning from mechanical ventilator.

Case Report

A 42-year-old male patient K/C of HTN was admitted to our ICU because of severe COVID-19 pneumonia, he was fully conscious cooperative hemodynamically stable with BP 130/85, HR 90/min, he was tachypnic, RR 45/min, O₂ saturation 84% on 15L NRM.

Heart exam: S1S2.

Chest exam: Bilateral basal crackles.

Abdomen exam: Soft, lax.

Investigations:

- HB 14 gm/dl, WCCs 4500/cmm, Neutrophils 75%, Lymphocytes 20%, Platelets 125000/cmm, D-Dimers 745 micgm/L, LDH 980 IU/L, normal PT, PTT, liver and kidney function and serum electrolytes are normal.
- ABG on 15L NRM PH 7.42, PCO₂ 35, PO₂ 46, O₂ Saturation 86%, HCO₃ 23.

X-ray chest

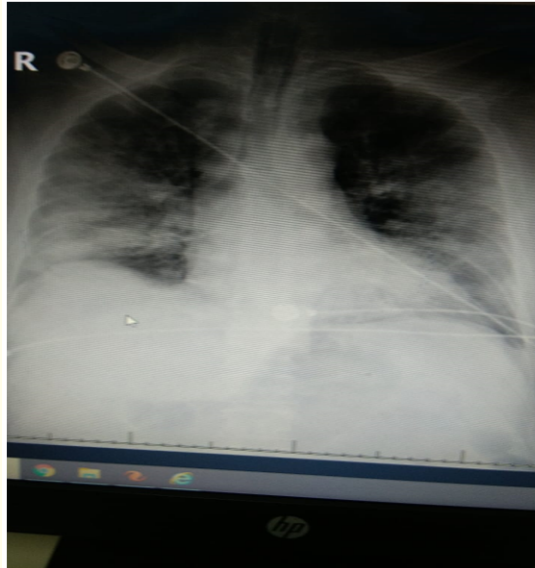

Figure 1: X-ray chest on admission picture of ARDS.

Lung U/S

We did Lung U/S several times, first, on admission which revealed wide spread condense B-Lines with thick pleura and subpleural consolidation, as well as well as spared areas of A-Lines, we measure Lung water score over 10 lung zones, bilateral upper anterior and

mid-axillary, bilateral lower anterior and mid-axillary and bilateral lower posterior axillary, it was 19/30 because we did not assess the RT and LT upper posterior axillary in supine patient.

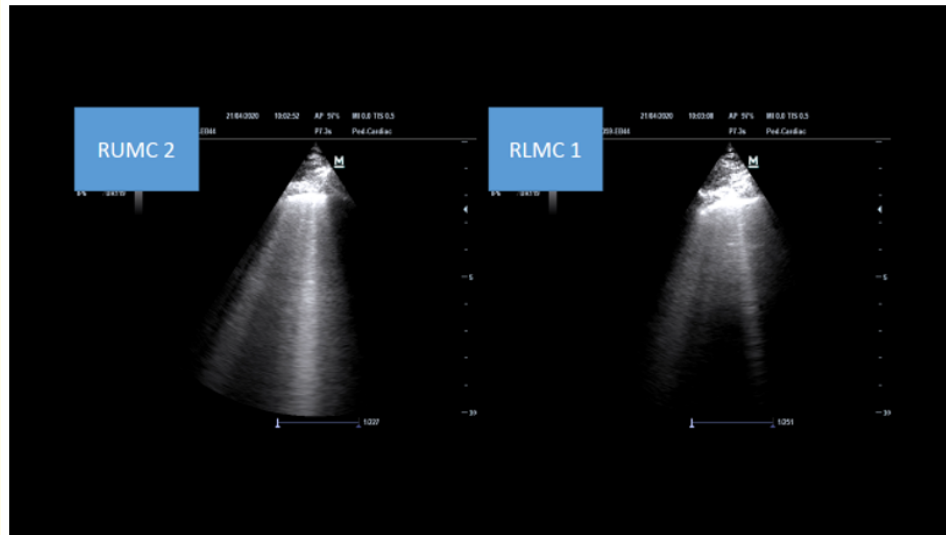


Figure 2: Lung water score of both RT upper anterior Lung zone revealing thick pleura, condense B lines and spared areas [lung water score 2], RT Lower anterior lung zone revealing less dense B-Lines with spared areas of A-Lines [Lung water score 1].

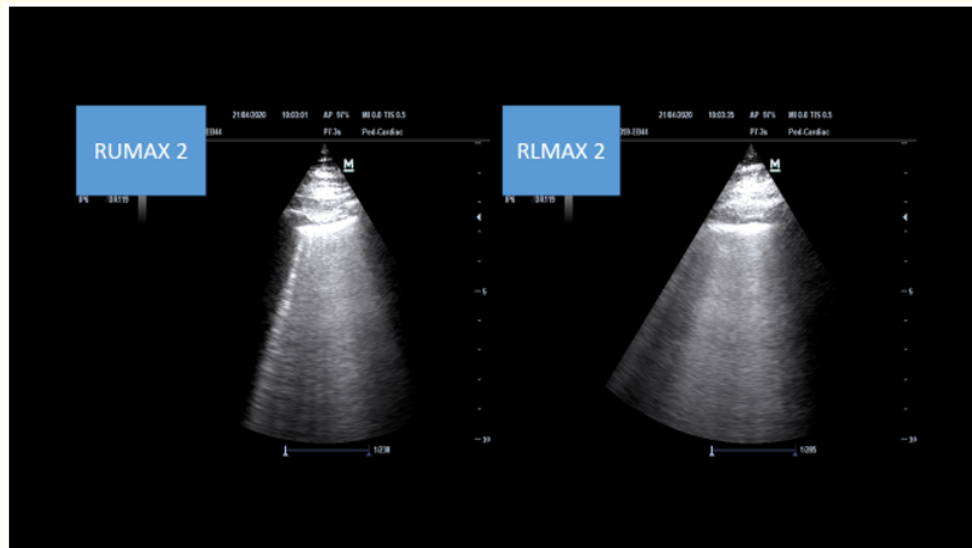


Figure 3: Lung water score of both upper and lower RT mid-axillary Lung zones revealing thick pleura, condense B Lines [lung water score 2].

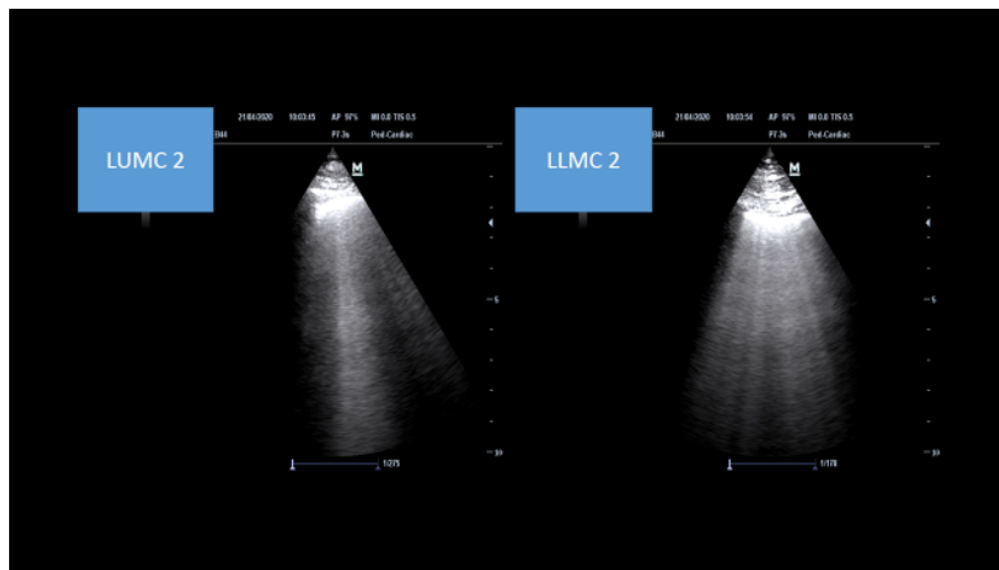


Figure 4: Lung water score of both LT upper and lower anterior mid-clavicular Lung zones revealing dense B-Lines [Lung water score 2].

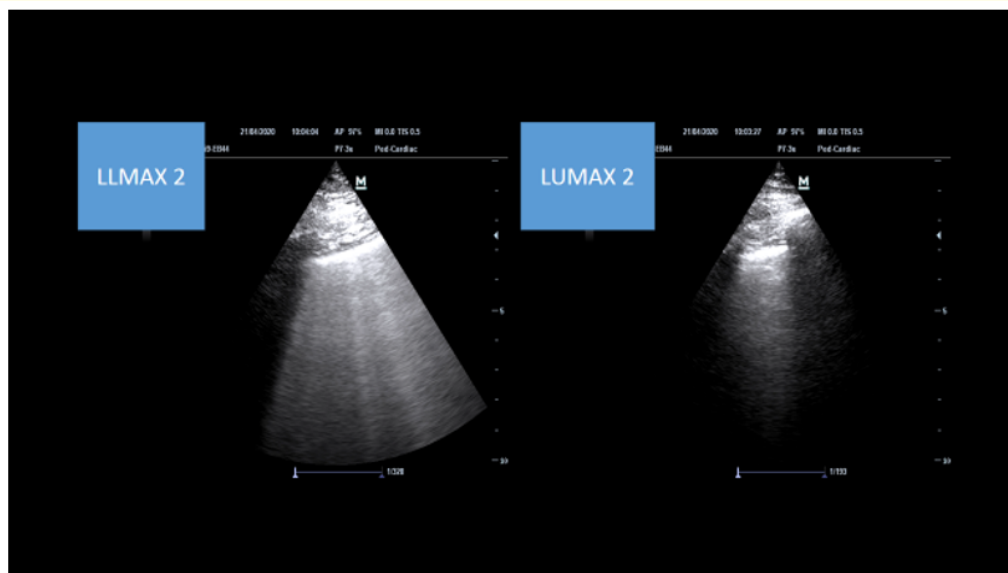


Figure 5: Lung water score of LT upper and Lower mid-axillary revealing dense B-Lines [score 2].

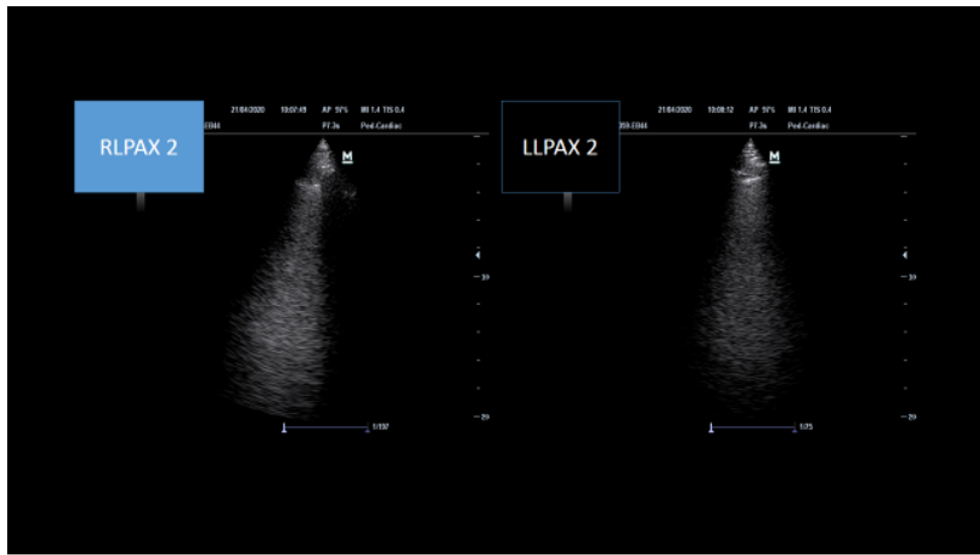


Figure 6: Lung water score of both RT and LT posterior axillary lung zones [condense B-Lines, score 2].

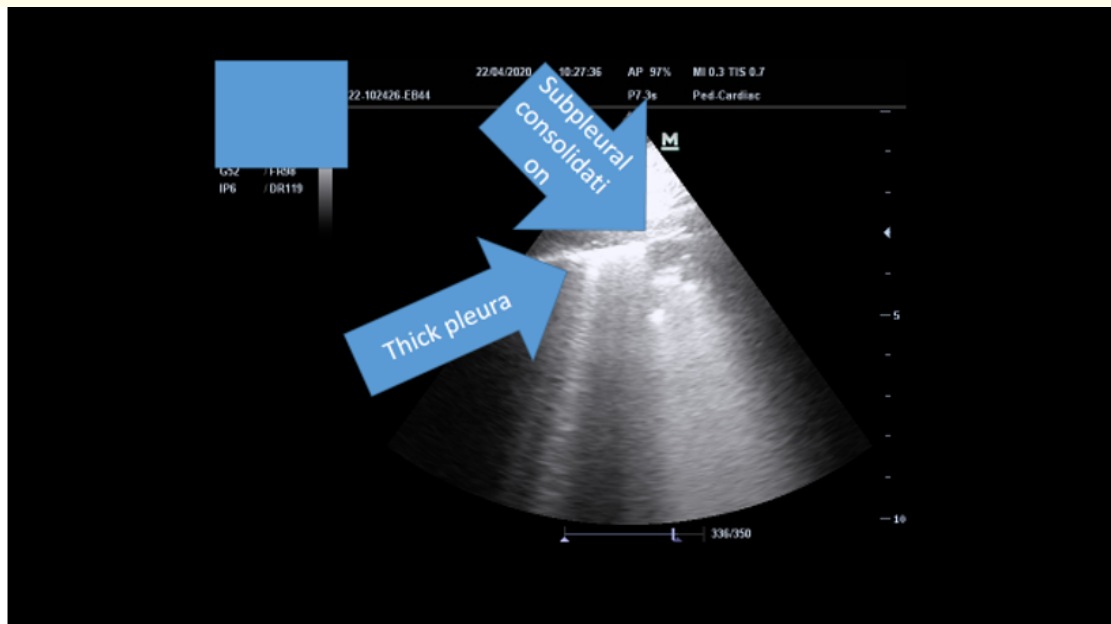


Figure 7: Subpleural consolidation and thick pleura.

We measure the diaphragmatic excursion by M-mode, it was 2.63 cm which is considered a good movement of the diaphragm.

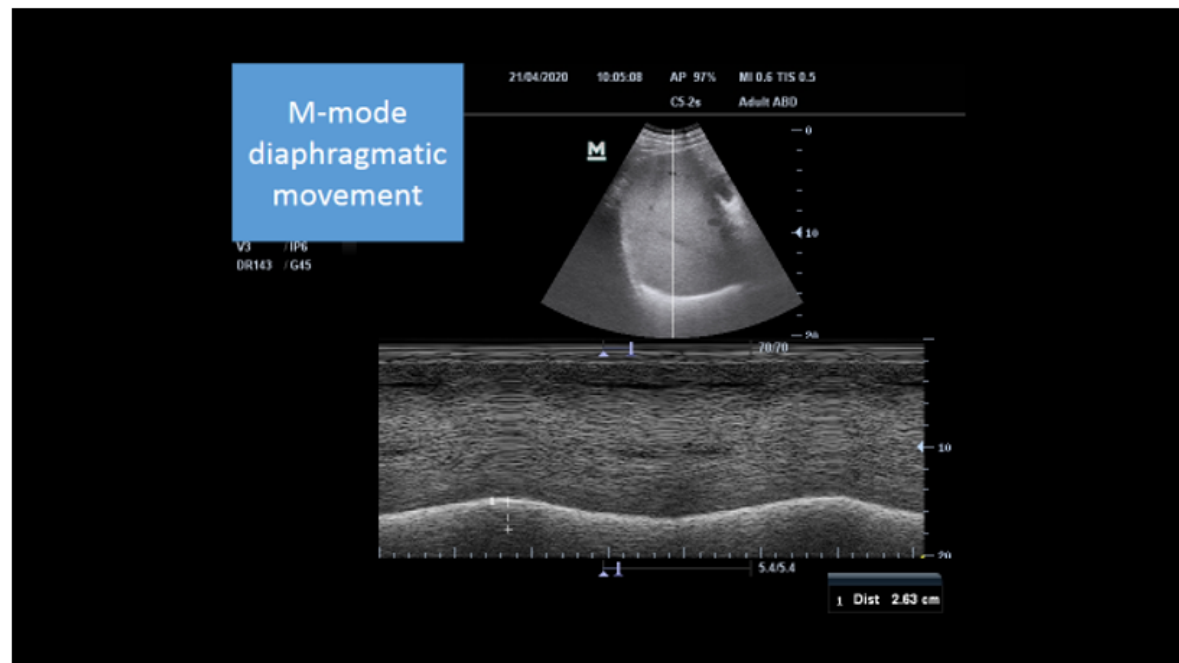


Figure 8: Good excursion of diaphragm on admission.

Bed side Echocardiography reveals normal sized RT ventricle and normal EF.

So, on admission Lung U/S help in, first, diagnosing of interstitial pneumonia as evidenced by condense B-Lines with thick pleura and subpleural consolidation and in assessment of severity by calculating lung water score, second, it help us to know the phenotype of COVID-19 pneumonia because the high excursion of diaphragmatic swings confirming the high compliance and L-phenotype COVID-19 pneumonia.

Patient was full conscious cooperative with good work of breathing and great diaphragmatic movement, so we connect the patient to trail of non-invasive CPAP 12CMH₂O.

3 hours after connecting to CPAP patient improved with decrease of RR to 30/min and O₂ saturation increase to 93% on FIO₂ 50%.

Next day repeat Lung U/S.

As you see, Lung U/S helps in evaluating the response to management, in our patient after antiviral, hydroxychloroquine, steroid and trail of CPAP Lung water score improved from 19/30 on admission to 15/30 after trail of CPAP.

48 hours later, all inflammatory markers came high D-Dimers increase to 7530 micgm/l. LDH 1360 IU/L, Lymphocytes dropped to 5%, patient deteriorate with O₂ saturation dropped to 77% on CPAP 8 and we increase to 15 and prepare for mechanical ventilator.

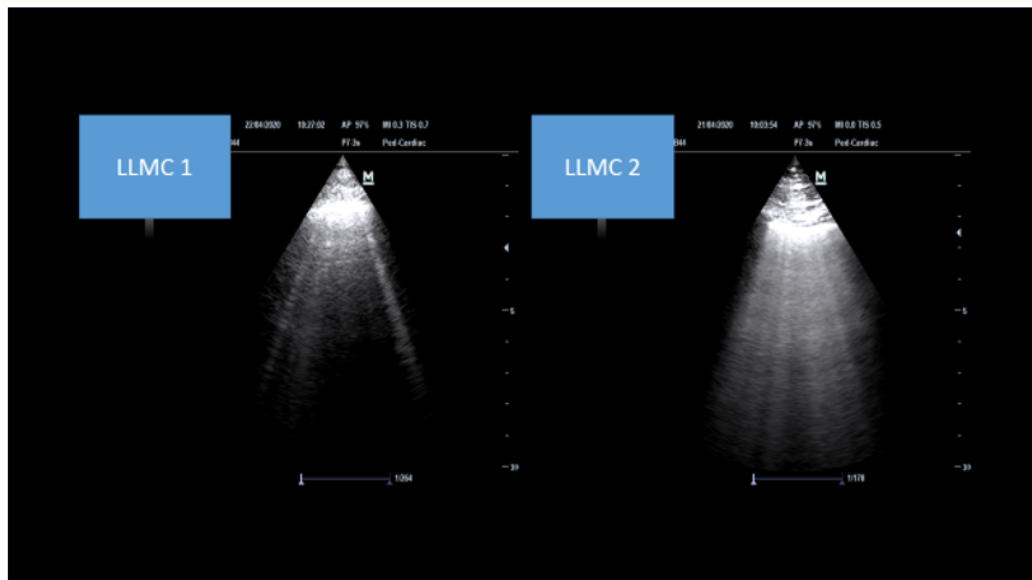


Figure 9: Improving of lung water score in LT lower mid-clavicular zone [lingua] from dense B-Lines score 2 on admission to separate B-Lines with spare area [score 1] after CPAP.

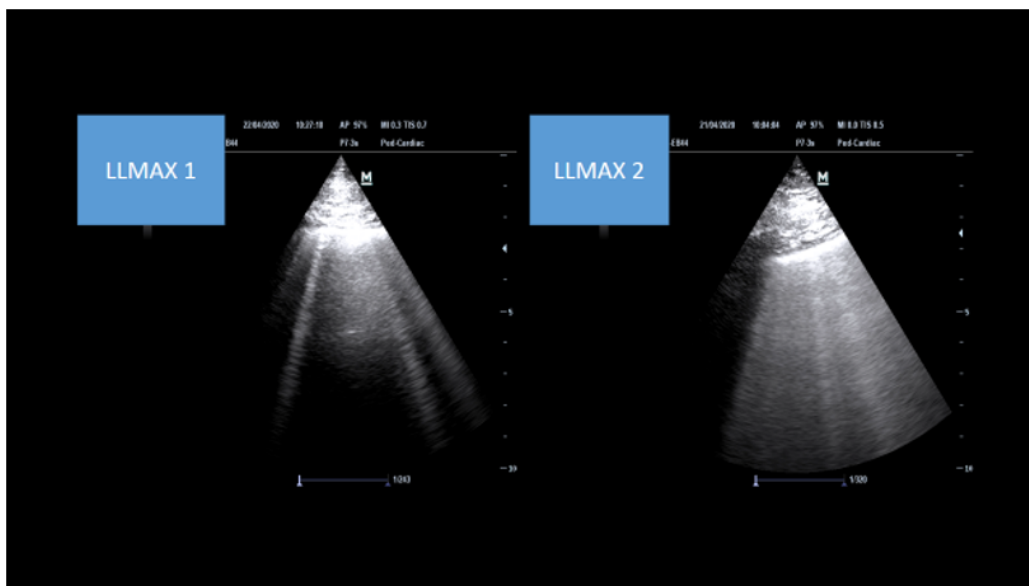


Figure 10: Improved lung water score in LT lower mid-axillary lung zones from dense B-Lines score 2 to [separated B-Lines and spare area score 1].

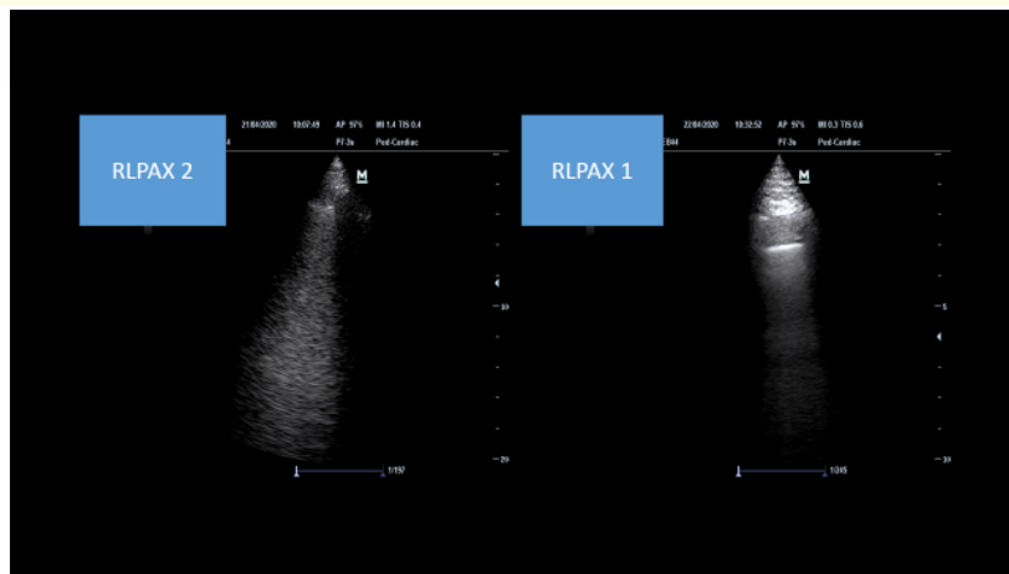


Figure 11: Improved lung water score in RT Lower posterior axillary lung zone from dense B-Lines score 2 on admission to A-Lines [score 0].

Before connecting to mechanical ventilator we repeat Lung U/S, it reveals worsening of Lung water score with condense B-Lines all over the lung zones [lung water score 20/30].

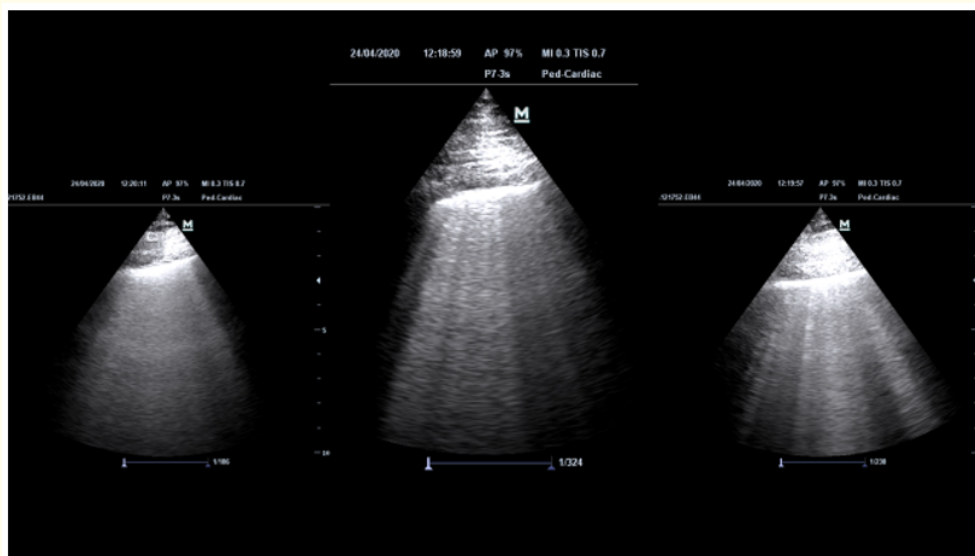


Figure 12: Worsening of lung water score after a trail of CPAP.

We increased anticoagulant to therapeutic dose and tocilizumab was added, patient was fully sedated and connected to mechanical ventilator high setting [P/C 15, PEEP 12, FIO₂ 80%, I:E 1:1.2, RR 24/min].

ICU course:

- Patient developed peripheral line infection which was treated with linezolid and *C. difficile* induced diarrhea treated with flagyl and vancomycin and IVI LR.
- Over the next days patient improved and we did another Lung U/S before weaning.

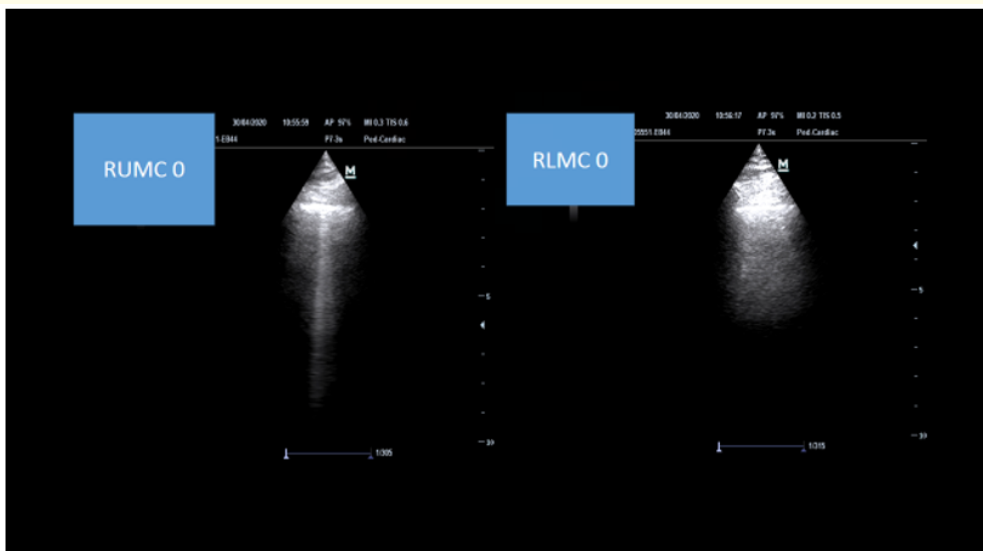


Figure 13: Lung water score 0 at RT upper and lower mid-clavicular lung zones revealing only 1 B-Line at RT upper anterior and A-Lines at RT Lower anterior lung zone with reareation score 4 compared to Lung water score before intubation.

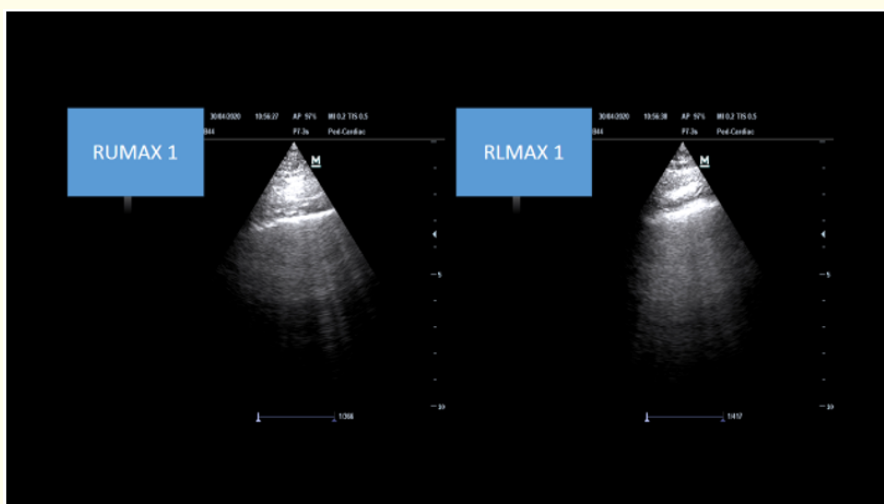


Figure 14: Lung water score at RT upper and lower mid-axillary lung zones [score 1] with reareation score of 2.

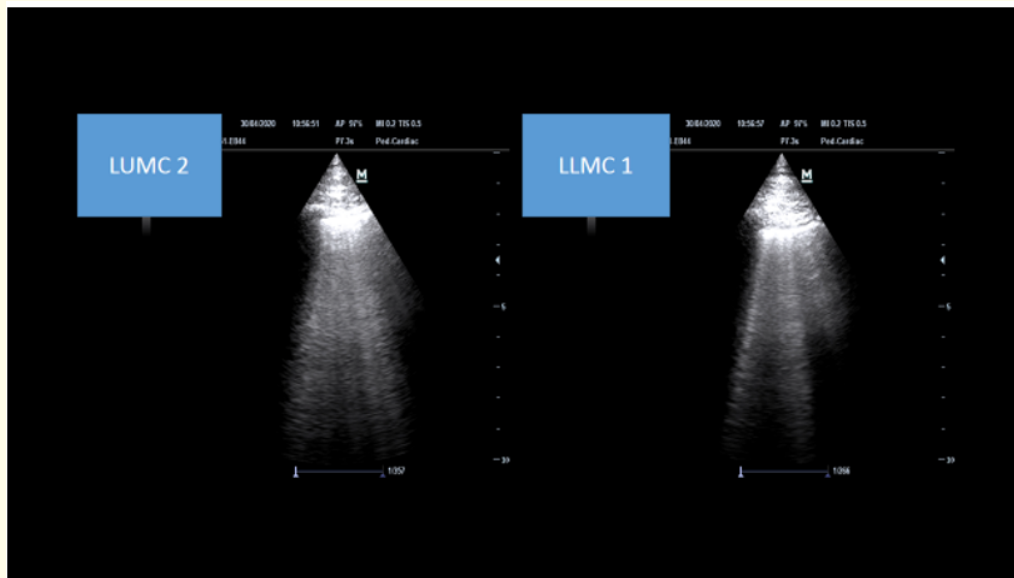


Figure 15: Lung water score at LT upper and lower mid-clavicular lung zones [score 1] with reareation score of 2.

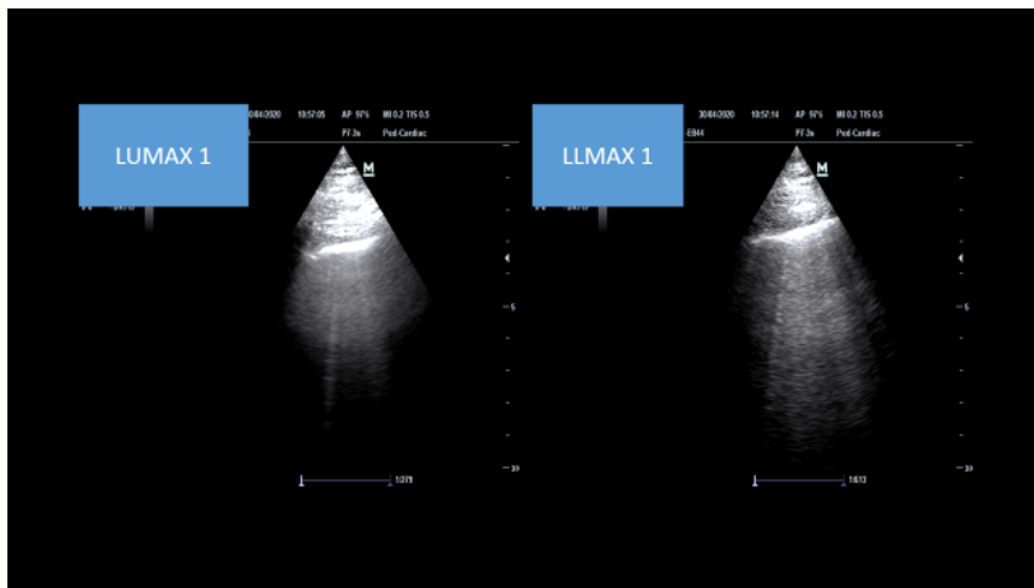


Figure 16: Lung water score at LT upper and lower mid-axillary lung zones [score 1] with reareation score 2.

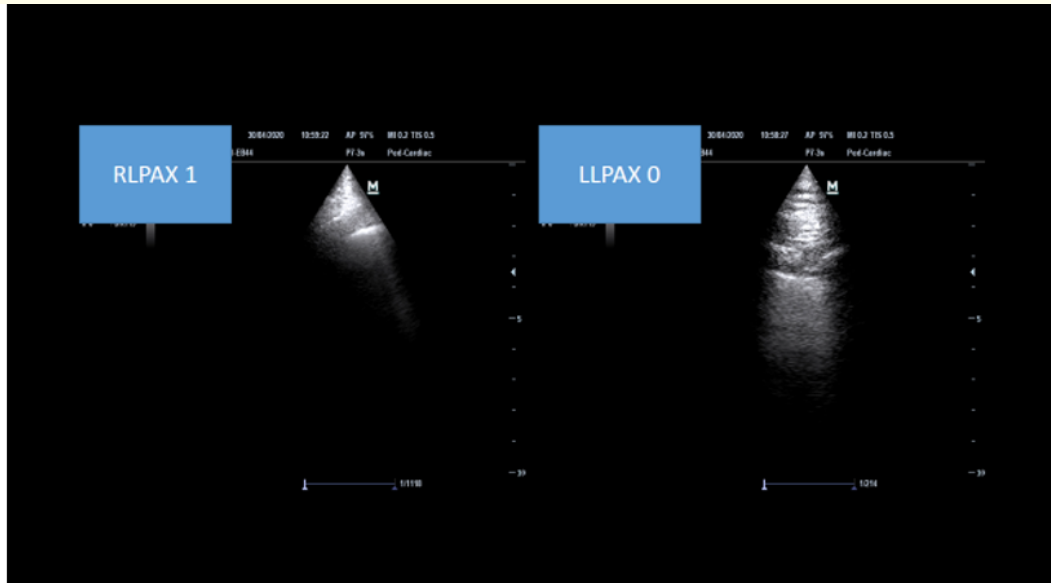


Figure 17: Lung water score at RT lower posterior axillary lung zone [score 1], LT Lower posterior axillary A-Lines [score 0] with reareation score 4.

So, repeat Lung U/S revealed drop of Lung water score from 20/30 before intubation to 8/30 after 6days from mechanical ventilator with reareation score of 10, patient was successfully extubated.

As you see from this case study lung U/S has a great role in diagnosis of interstitial pneumonia with a clue about phenotype, in assessing the severity by counting the lung water score and in following the response to management until suitability for weaning by confirming the drop of lung water score and high reareation score.

(All the videos and photos of the case report in YouTube case study)

Discussion

This is a case study of a 42-year-old male patient admitted to our ICU because of severe COVID-19 pneumonia, we did a critical care U/S including lung and diaphragmatic U/S, on admission, Lung U/S revealed thick pleura, condense B-Lines in almost all lung areas, subpleural consolidation and spare areas with A-Lines, we found good diaphragmatic excursion 2.63 cm with M-mode U/S, this good diaphragmatic swings which denote a good compliance may give us a clue about phenotyping of COVID-19 pneumonia, good excursion go with L-phenotype with good compliance.

We followed up Lung U/S water score of the patient after treatment, with any change of patient respiratory status and before extubation and compared with baseline, on admission Lung water score was 19/30, slightly improved to 15/30 after a trail of CPAP to deteriorate after 2days and reach 20/30, patient was mechanically ventilated and received immunomodulating drugs, 6 days later patient improved significantly and lung water score dropped to 8/30 with reareation score of 10 and patient was successfully extubated.

Huang., *et al.* utilized lung ultrasound to evaluate peri-pulmonary lesions of 20 noncritical COVID-19 patients at Xi’an Chest Hospital in China. The authors conclude that computed tomography may be inferior to lung ultrasound in detecting smaller peri-pulmonary lesions and effusions in COVID-19 patients. Lung ultrasound in these patients demonstrated (1) posterior and inferior lung field lesions, (2) B

lines, (3) distorted pleural lines, (4) subpleural pulmonary consolidations, and (5) air bronchograms [4]. While these findings may not be specific to COVID-19 compared to other viral pneumonias, identification of these patterns during a pandemic could certainly assist providers in determining individuals who are likely to be infected [5].

Jin., *et al.* performed lung ultrasound on 20 confirmed COVID-19 patients from Xiangya Hospital and Peking Union Medical College Hospital in China. Their early findings demonstrated that the use of ultrasound provided similar results to those of computed tomography and superior results to those of standard chest radiographs. Their findings included (1) thickening of the pleural line with irregularity, (2) B lines, (3) consolidation, (4) the appearance of A lines during recovery and (5) the absence of pleural effusions. They concluded that ultrasound was an effective way to assess the severity of a patient's pulmonary disease and to trend their disease progression and guide eventual respiratory weaning [5].

We followed up our patient during ICU management by Lung U/S, we followed the patient Lung water score on admission, during treatment, with deterioration and before extubation, moreover we calculate Lung reareation score before extubation, this was very important during patient management, on admission Lung water score was 19/30, improved slightly to 15/30 with a trail of CPAP to deteriorate to 20/30 2 days later and patient was connected to invasive mechanical ventilator, 6 days later patient improved with drop of Lung water score to 8/30 and very high reareation score of 10 before successful extubation.

An LUS score of aeration can be calculated as follows: for each given region of interest, points are allocated according to the worst ultrasound pattern observed: normal = 0, well-separated B-lines = 1, coalescent B-lines = 2, and consolidation = 3. An LUS score ranging between 0 and 36 was calculated as the sum of each region. This score is a global picture of lung aeration and can be regularly monitored. An increase in score indicates a decrease in aeration [6].

In ARDS patients, LUS reareation score not only estimates adequately PEEP-induced lung recruitment but also allows regional analysis of recruitment mechanisms. Recruitment mainly results from reareation of poorly aerated lung regions rather than from reareation of consolidations: coalescent B-lines are transformed into separated B-lines with reareation score of 1 or A-lines with a reareation score of 3, and separated B-lines are transformed into A-lines with a reareation score of 1. Recruitment of consolidations is rarely observed but recruitment from consolidation to dense B-Lines will give score 1 and to separate B-Lines score 3 and if consolidation turn to A-Lines this will give reareation score 5 [7].

In patients passing successfully a 1h spontaneous breathing trial, ultrasound changes of lung aeration are predictive of extubation success or failure: in patients definitively weaned, overall lung aeration does not significantly change during the spontaneous breathing trial, whereas in patients with post-extubation distress, lung aeration decreases during the spontaneous breathing trial [6].

An ultrasound reareation score of +8 or higher was associated with a PEEP-induced lung recruitment greater than 600 ml. A statistically significant correlation was found between LUS reareation score and PEEP-induced increase in Pa(O₂) and weaning success [7].

To my knowledge this is the first time to use Lung U/S not only to diagnose and assess severity of COVID-19 pneumonia but also to F/U the disease during its course in ICU until successful weaning, moreover, it is the first time to use diaphragmatic excursion and swings to get an idea about the phenotype of COVID-19 pneumonia, good excursion denote good compliance and L-phenotype.

Conclusion

Lung U/S is a great tool in management of COVID-19 patient during his stay in ICU, it can help in phenotype diagnosis, assess severity and response to treatment and predict the success of weaning.

Bibliography

1. National Health Commission of the people's Republic of China. Diagnosis and treatment of novel coronavirus pneumonia (trial, the fifth version) [EB/OL] (2020-02-05).
2. Mayo PH., *et al.* "Thoracic ultrasonography: a narrative review". *Intensive Care Medicine* 45.9 (2019): 1200-1211.
3. Qian., *et al.* "Findings of lung ultrasonography of novel corona virus pneumonia during the 2019–2020 epidemic". *Intensive Care Medicine* 46.5 (2020): 849-850.
4. Huang Y., *et al.* "A preliminary study on the ultrasonic manifestations of peripulmonary lesions of non-critical novel coronavirus pneumonia (COVID-19)". *SSRN* (2020).
5. Jin YH., *et al.* "A rapid advice guideline for the diagnosis and treatment of 2019 novel coronavirus (2019-nCoV) infected pneumonia (standard version)". *Military Medical Research* 7.1 (2020): 4.
6. Soummer., *et al.* "Ultrasound assessment of lung aeration loss during a successful weaning trial predicts postextubation distress". *Critical Care Medicine* 40.7 (2012): 2064-2072.
7. Bouhemad B., *et al.* "Bedside ultrasound assessment of positive end-expiratory pressure-induced lung recruitment". *American Journal of Respiratory and Critical Care Medicine* 183.3 (2011): 341-347.

Volume 4 Issue 7 July 2020

©All rights reserved by Walid Shibl and Ibrahim El Alfy.