

Accidental Dislodgment of External Ventricular Drains (EVD) -Technical Lessons from a Six Months Retrospective Review

Ugwuanyi UC*, Alg VS, Akhunbay-Fudge C and Watkins LD

Victor Horsely Department of Neurosurgery, The National Hospital for Neurology and Neurosurgery, Queen Square London, UK

***Corresponding Author:** Ugwuanyi U.C, Victor Horsely Department of Neurosurgery, The National Hospital for Neurology and Neurosurgery London, UK and Neurosurgery Division, National Hospital Abuja Nigeria, Wellington Neurosurgery Centre Abuja Nigeria.

Received: October 29, 2019; **Published:** November 26, 2019

Abstract

Introduction: External Ventricular Drainage (EVD) is a temporary diversion of cerebrospinal fluid from the ventricular system into closed outside system. It is the commonest emergency neurosurgical procedure in most Neurocritical care units. Several methods of anchorage have been used by different surgeons with different rates of accidental dislodgement.

Aims and Objectives: To examine the different methods of anchorage of EVD and their associated complications.

Methods: 44 cases of accidentally dislodged EVD were selected out of total 76 EVDs inserted over a six months period (Dec 2008-May 2009) at the National Hospital for Neurology and Neurosurgery, London UK. Four methods (I-IV) of anchoring tunneled ventricular catheters were examined. Parameters studied were indications and anchoring methods for EVD insertion. Any associated complications including infections such as ventriculitis were equally studied.

Results: 44/76(57.8%) of all EVDs inserted during the study period suffered accidental dislodgement. There were 26 males and 18 females (M: F = 1.44:1). Mean age was 56.6 years. Commonest indication for initial EVD was subarachnoid hemorrhage with intraventricular extension 22/44 (50%). Method II 29/44 (65.91%) was the commonest method employed at initial EVD insertion. Accidental dislodgements requiring revision was recorded in 18/44(40.9%) mostly on those with types I and II anchorage methods ab-initio. The commonest indication for revision was premature dislodgement in 18/44 (40.9%). Method III was used exclusively for those revisions. Further revisions were observed in 6/44 (13.63%) cases but due to blockage and ventriculitis rather than premature removal. Ventriculitis was observed in 12/44(27.27%) and 10/12(83.33%) were observed in previously revised cases.

Conclusion: Method III is more secured with less risk of dislodgement and reduced chances of life-threatening complications such as ventriculitis. It should therefore be recommended as the procedure of choice ab-initio.

Keywords: External Ventricular Drain; Accidental Dislodgement; Anchoring Methods; Ventriculitis

Introduction

External ventricular drainage (EVD) is frequently necessary in neurological and neurosurgical intensive care patients. Urgent neurosurgical intervention for a patient presenting with acute hydrocephalus, regardless of cause, is almost always CSF diversion. This helps

to normalize the intracranial pressure and provide valuable time for further diagnostic studies and definitive treatments of the primary cause of disease.

Hydrocephalus results from derangement of normal CSF physiology. Pressure gradient develops across the brain parenchyma from the intraventricular compartment to the extra-axial subarachnoid space [1]. This hydrostatic pressure causes the ventricles to enlarge and compress the brain parenchyma and subarachnoid cisterns against the rigid skull. Neurological dysfunction becomes inevitable and often fatal in acute conditions.

Infection has been reported as the most common cause of acquired hydrocephalus. In bacterial meningitis, hydrocephalus can develop within days or a few weeks of initial presentation [2]. Intraventricular cysts associated with neurocysticercosis can acutely obstruct CSF flow [3], while edema associated with cerebellar encephalitis can obstruct the fourth ventricle [4]. Intracranial hemorrhage is reported as the second most common cause of acquired hydrocephalus [1]. The realistic frequency range for hydrocephalus following sub-arachnoid hemorrhage on initial CT brain is 15 - 20% [5]. Supratentorial intracerebral hemorrhage is a recognized cause of acute hydrocephalus either due to intraventricular extension or due to mass effect and midline shift causing obstruction at the level of foramen of Monroe [6]. Similarly, posterior fossa (infratentorial) bleed cause deformation and obstruction of the fourth ventricle and acute hydrocephalus [7]. Intraventricular or periventricular mass lesions can cause acute hydrocephalus or exacerbation of a chronic condition [8]. Third ventricular colloid cyst, pineal region tumors, cerebellar and fourth ventricular tumors are common examples. Edema or hemorrhage associated with ischemic stroke, traumatic brain injury or post craniotomy can impair normal CSF flow and cause acute hydrocephalus.

Acute hydrocephalus is a regular occurrence in our daily neurosurgical practice. Early recognition and management prevent avoidable death. Progressive deterioration in the level of consciousness, cardiovascular instability, and respiratory irregularity are important clinical features especially in the presence of any of the predisposing disease conditions outlined above. CT scan of the brain provides a quick imaging evaluation of the brain and its ventricles. Temporal horns greater than 2 mm and frontal horns diameter: internal diameter ratio at the level of frontal horns, of greater than 50% is diagnostic hallmarks of hydrocephalus [9]. Evans ratio (frontal horns diameter/ maximal biparietal diameter) greater than 30% is also used as a diagnostic method. When associated with periventricular hyperintensity on T2 MRI weighted images or on FLAIR MRI sequence and periventricular hypodensity on CT scan, this suggests acute hydrocephalus with trans-ependymal diffusion of CSF into the adjacent brain parenchyma.

Treatment of acute hydrocephalus with CSF diversion has been shown to improve outcome in most cases [10]. Methods used for CSF diversion include external ventricular drainage (ventriculostomy), endoscopic third ventriculostomy, ventriculo-peritoneal shunt, ventriculo-atrial shunt, lumbar puncture/drainage. In acute hydrocephalus, external ventricular drainage of CSF is most often used because it is rapidly deployable even at bedside. It allows measurement/monitoring of intracranial pressure and CSF flow and can be lifesaving. It is however a stop-gap measure to allow valuable time to investigate and deal with the primary cause.

Infection is the most important complication of ventriculostomy. Reported rate vary from 4 - 20% and usually from skin flora contaminants [11]. The most dreaded infection is ventriculitis. Hemorrhage associated with passing the ventricular catheter can be up to 7% but is only symptomatic in less than 1% [12]. In aneurysmal subarachnoid hemorrhage, ventriculostomy is associated with a high risk of re bleeding in poor grade and unprotected cases [13]. Other complications include blockage by blood products and poor positioning both of which require immediate revision.

Accidental dislodgement of external ventricular drains is a frequent occurrence, yet it is under reported. It occurs when ventricular catheter is inadvertently pulled at bedside or during transfer from one part of the hospital to the other such as during radiological investigations. Leakage of CSF and wetting of pillows and bed sheets is often observed. A CSF fistula provides a direct communication between the ventricular cavity and the exterior. Consequently, there is a high risk of ventriculitis due to bacterial transmigration from the skin flora

into the ventricular cavity. Improper anchorage of the ventricular catheter will predispose to accidental dislodgement necessitating immediate revision. Various methods have been employed in anchoring the ventricular catheter after insertion and tunneling. Unacceptable high rate of dislodgement has been observed in some methods while some methods provide a relatively secure anchorage. This study therefore examines the various anchorage methods in relation to the rates of premature dislodgements and other associated complications.

Methods

Case notes of 44 accidentally dislodged EVD out of total 76 cases of EVD inserted over a six months period (DEC 2008-May 2009) were retrospectively reviewed. The rest of the 32 cases did not merit the selection criteria for this study because they did not suffer any premature dislodgement throughout their period of treatments irrespective of the initial EVD anchorage methods.

At the time of this study there was no strict unit policy and the on-call Resident was at liberty to choose whatever anchorage technique of convenience. It was then observed that some anchorage methods were associated with unacceptably high rate of premature dislodgements. Consequently, the selection method for the period under study was to sequentially isolate all prematurely dislodged EVDs for analysis.

Four methods (I-IV) of anchoring tunneled EVD tubes were examined. Parameters studied were indications (Table 1) and anchoring methods (Figure 2-4). In Method I, the tunneled ventricular catheter was anchored to the surrounding scalp with silk 2.0, in similar fashion like a wound drain. Method II is similar to Method I but it has an added anchoring device attached. Method III involves a 360 degrees loop of the tunneled catheter and anchorage at three different points equidistant from each other with both anchoring device and silk 2.0. Method IV involves extended subcutaneous tunneling through the neck down to the anterior chest wall or anterior abdominal wall where it is externalized. This method is commonly used in children to reduce premature dislodgment due to pulling. The main parameters of study interest include indications for EVD insertion, anchorage methods at initial surgery, anchorage method specific dislodgement rates, anchorage methods deployed for re-do cases and commonly observed complications with premature dislodgements. Data analysis with simple descriptive statistics.

It is done under general anesthesia. Prophylactic antibiotic is with 750 mg cefuroxime axetil IV. Our preferred method of ventriculostomy via a burr hole on the Kocher's point- 1 cm anterior to the coronal suture in the mid papillary line and 3 cm lateral to the sagittal plane about 11 cm from the nasion. The non-dominant frontal horn is preferred for access but the pathology and pre-operative imaging play an important role in this decision. Dura is incised with size 11 surgical blade and the underlying arachnoid, pia and cortical matter is cauterized with a bipolar pencil set low at 10. The ventricular catheter is gently passed in a trajectory aiming at the inner canthus of the ipsilateral eye and at a depth of 5 - 7 cm the anterior horn of the lateral ventricle is usually penetrated as evidenced by free flow of CSF which may be under pressure initially. Passage of ventricular catheter should never go beyond 7 cm to prevent inadvertent damage to the underlying thalamus and deep blood vessels. Thereafter, the catheter is tunneled under the scalp, externalized and anchored with any of the methods described above and making sure not to alter the intra-ventricular length. It is then connected to an external drainage device and regulated accordingly usually at a drainage height of 15 cm. In that way pressure build up in excess of 15 is permissible to drain. Figure 6 and 7 displays the complete frontal EVD set up.

Results

44 cases of accidentally dislodged EVD were selected out of a total 76 (57.8%) cases of EVD inserted within the study period. There were 26 males and 18 females (M: F = 1.44: 1) and mean age was 56.6 years (Figure 1).

Indications for initial EVD insertion (Table 1) were subarachnoid hemorrhage with intraventricular extension 22/44 (50%), Intra-cerebral hemorrhage with intra-ventricular extension 7/44 (15.91%), Pre-operative Obstructive Tumour 7/44 (15.91%), Infection 4/44 (9.09%), VP Shunt Malfunction 2/44 (4.55%), Post-operative Obstruction - 2/44 (4.55%).

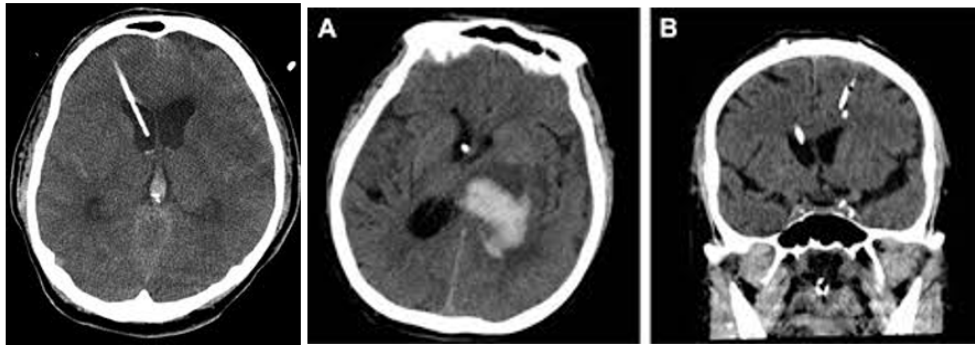


Figure 1: Non contracted CT brain (NCCT) showing Right frontal EVD, intracerebral hemorrhage (ICH) with intraventricular extension (IVH) and acute obstructive hydrocephalus.

Indication for EVD	No	Percentage
SAH with IVH	22	50
ICH with IVH	7	15.9
Obstructive Tumor	7	15.9
Post CSF Infection	4	9.1
Post op precaution	2	4.5
VP malfunction	2	4.5
Total	44	100

Table 1: Indications for EVD insertion.

At initial EVD insertion, 11/44 (25%) had Method I (Figure 2), 29/44 (65.9%) had Method II (Figure 3), 3/44 (6.8%) had Method III (Figure 4) while only 1/44 (2.27%) had Method IV (Figure 5). Table 2 captures anchorage method specific premature dislodgements.

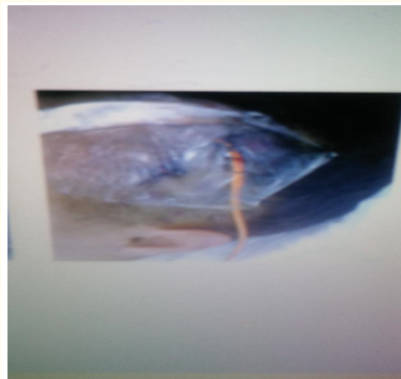


Figure 2: Method I.

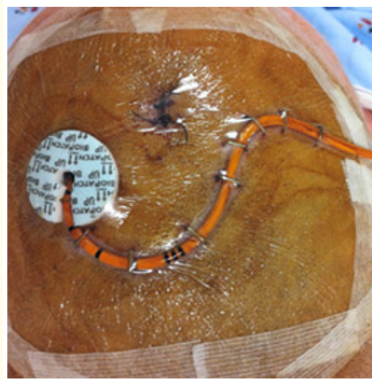

Figure 3: Method II.

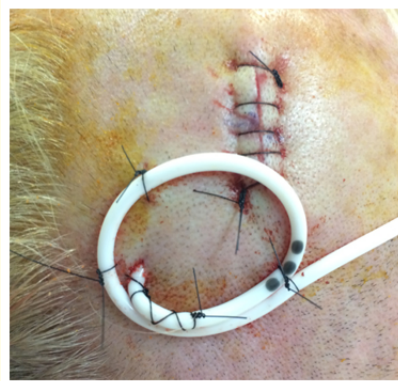

Figure 4: Method III.

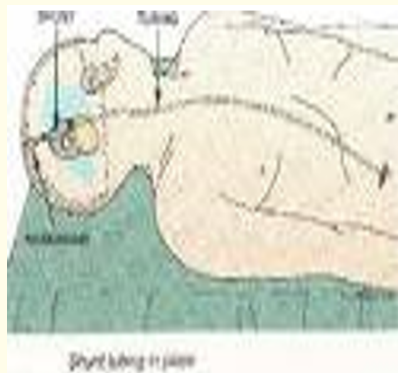


Figure 5: Method IV.

Anchorage Method	Freq of Prem dislodgements	Percentage
I	11	25
II	29	65.9
III	3	6.8
IV	1	4.5

Table 2: Anchorage method specific premature dislodgements.

Total number of EVD revisions were 18/44 (40.9%) of study population). They were all done using Method III technique.

Indications for revision were accidental dislodgement 13/18 (72.2%), Ventriculitis 1/18 (5.55%), Blockage 2/18 (11%), and following surgical excision of obstructive tumor 2/18 (11.11%) (Figure 4).

6/18 (33.3%) patients who were previously revised needed further revisions and the indications were ventriculitis and blockage in 5/18 (27.77%) and blockage alone in 1/18 (5.55%) There was no recorded accidental dislodgement in those requiring further revisions probably because Method III was used.

Associated complications observed in 12/13 (66.6%) cases of accidental dislodgement were ventriculitis alone 7/12 (58.33%), ventriculitis and blockage 4/12 (33.33%), ventriculitis with systemic Sepsis 1/12 (8.33%). Overall rate of ventriculitis associated with accidental EVD dislodgement was therefore 12/44 (27.27%).

Discussion

External ventriculostomy is often an emergency and lifesaving procedure usually performed out of hours by on call neurosurgical trainees. The indication is mainly to relieve acute obstructive hydrocephalus to prevent coning and death. The salient technical aspects of this procedure are also clearly outlined in the section on methodology above.

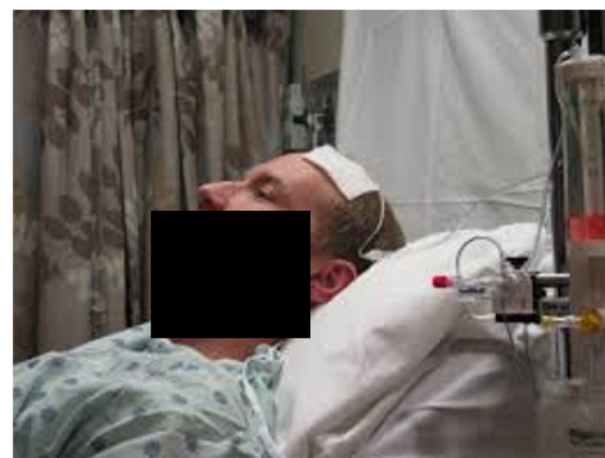

Figure 6: EVD in-situ.

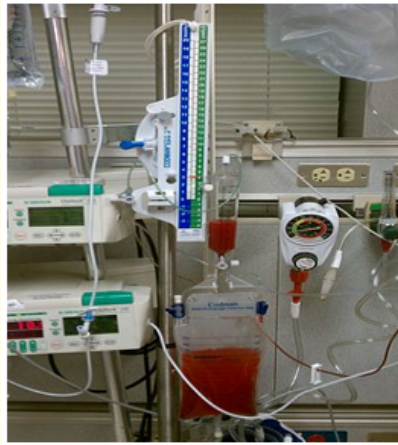

Figure 7: External Drainage System.

The main focus of this discussion is on the various anchoring methods for the tunneled ventricular drains and their associated complications. The commonest complication observed in this study was premature dislodgement which was recorded in 13/44 (29.5%) cases and contributed 13/18 (72%) of all the revised cases. Whereas Methods I and II were observed to be associated with high rates of accidental catheter dislodgement 6/13 (46.5%) and 7/13 (53.8%) respectively, Methods III and IV did not record any case of premature dislodgements. Therefore, the preference for all the revised cases was Method III. It provided a more secured construct with no recorded incidence of dislodgement. This technique is also recommended by Fadi, *et al.* as a practice guideline [1]. Although Method IV provides a very good security, it did not feature much in this study because the setting was an adult neurosurgery center and most patients studied were adult patients.

Accidental catheter dislodgment often occurs at bedside during change of linen, in a restless patient who pulls on the tubes, or during transfer from one part of the hospital to another such as during radiological investigations. Traction on the catheter is often inevitable and potentially dislodges the tube, especially when inappropriately secured. Leakage of CSF and wetting of head dressings, pillows and beddings will occur when the track remains patent. On the other hand, worsening of CSF obstructive symptoms with rising ICP, drop in GCS, hypertension and bradycardia will occur when the track is closed with no chance of CSF leak. Both scenarios are neurosurgical emergencies. First the leakage of CSF will inevitably lead to ventriculitis which is very difficult to treat with associated high mortality. The EVD must be revised as a matter of urgency and placed at another site and the previous stoma sutured water tight. When there is no associated CSF leak, the chances of CSF infection and ventriculitis is much reduced but the emerging acute obstructive hydrocephalus must be addressed as a matter of urgency. If the CSF is sterile and clear, a permanent CSF diversion such as VP shunt could be considered, otherwise a temporary EVD is conducted at another site. The method of anchorage at this stage must discourage any further premature dislodgements and Method III is reliable.

In this study, ventriculitis was observed in 12/44 (27.2%) cases especially in the prematurely dislodged and blocked EVDs. The factors that predispose to EVD related infections such as ventriculitis include site leakage [12], bloody CSF in subarachnoid hemorrhage (SAH) and intracerebral hemorrhage (ICH) with intraventricular extension (IVH) [13] all featured prominently in this study. In view of the morbidity, prolonged hospital stay, burden on scarce health resources and mortality associated with EVD related infections such as ventriculitis, all efforts must be in place to prevent it ab initio and this starts from adopting the appropriate techniques at initial insertion.

Conclusion and Recommendation

Method I and II for EVD insertion are associated with high rate of accidental dislodgement which is associated with high rate of ventriculitis and should therefore be discouraged.

Methods III and IV provide a more secured EVD, less likelihood of premature dislodgement, reduced risk of ventriculitis and should therefore be adopted always as a practice guideline.

Bibliography

1. Fadi F Nasr and Jojn H Honeycut. "Management of Acute hydrocephalus". In: Christopher M. Loftus ed. *Neurosurgical Emergencies*, Second Edition Thieme (2008): 27.
2. Frat J., *et al.* "Reversible acute hydrocephalus complicating *Listeria monocytogens* meningitis". *European Journal of Clinical Microbiology and Infectious Diseases* 20 (2001): 512-514.
3. Shanley JD and Jordan MC. "Clinical aspects of CNS cysticerosis". *Archives of Internal Medicine* 140 (1980): 1309-1314.
4. Aylett SE., *et al.* "Cerebellitis presenting as acute hydrocephalus". *Child's Nervous System* 14 (1998): 139-141.
5. Hassan D., *et al.* "Management problems in acute hydrocephalus after subarachnoid hemorrhage". *Stroke* 20 (1989): 747-753.
6. Summer MM., *et al.* "External ventricular drainage for acute obstructive hydrocephalus developing following spontaneous intracerebral hemorrhage". *Neurological Sciences* 23 (2002): 29-33.
7. Greenberg J., *et al.* "Acute hydrocephalus in cerebellar infarct and hemorrhage". *Neurology* 29 (1979): 409-413.
8. Wissoff JH and Epstein F. "Surgical management of symptomatic pineal cysts". *Journal of Neurosurgery* 77 (1992): 896-900.
9. Le May M and Hockberg FH. "Ventricular differences between hydrostatic hydrocephalus and hydrocephalus ex-vacuo by CT". *Neuroradiology* 17 (1979): 191-195.
10. Adams RE and Drainger MM. "Response to External ventricular drainage in spontaneous intracerebral hemorrhage with hydrocephalus". *Neurology* 50 (1980): 519-523.
11. Park P., *et al.* "Risk of infection with prolonged ventricular catheterization". *Neurosurgery* 55 (2004): 594-601.
12. Lozier AP., *et al.* "Ventriculostomy-related infection: a critical review of the literature". *Neurosurgery* 51 (2002): 170-182.
13. Mayhall CG., *et al.* "Ventriculostomy-related infections. A prospective epidemiologic study". *The New England Journal of Medicine* 310 (1984): 553-559.

Volume 3 Issue 12 December 2019

©All rights reserved by Ugwuanyi UC., *et al.*