

## Diode Laser Treatment for Oral Venous Malformations: Insights from Three Clinical Cases

Hajar Benhaioun\*, Kawtar Belmekki, Soukaina Oujdad and Sidi Mohammed Bouzoubaa

Oral Medicine and Oral Surgery Department, Hassan II University, Morocco

\*Corresponding Author: Hajar Benhaioun, Oral Medicine and Oral Surgery Department, Hassan II University, Morocco.

Received: March 02, 2026; Published: May 11, 2026

### Abstract

Vascular malformations are congenital vascular anomalies characterized by abnormal vessel development and variable clinical presentation. The international society for the study of vascular anomalies (ISSVA) classification has standardized their categorization, improving diagnostic clarity and therapeutic decision-making. Although many oral vascular malformations are asymptomatic and require only observation, intervention becomes necessary in cases of bleeding, functional impairment, or esthetic concern. Diode laser photocoagulation has emerged as a minimally invasive therapeutic option offering effective vascular control with limited postoperative morbidity. This study presents three clinical cases illustrating the use of a 980 nm high-power diode laser in the management of oral vascular lesions, including a venous malformation, multiple varices, and a solitary oral varix in patients aged between 55 and 70 years. Diagnosis was established through clinical examination and positive diascopy. Treatment was performed using a 980 nm diode laser in continuous wave mode (1.0 W; 10 J/cm<sup>2</sup>) with a non-contact technique and controlled irradiation intervals to reduce thermal damage. Depending on lesion size, one to four sessions were required. Postoperative evolution was favorable in all cases, with fibrin formation observed within 24 hours and complete healing achieved within 2 to 3 weeks. No significant intraoperative bleeding, scarring, or major complications were reported. Diode laser photocoagulation induces selective microvascular coagulation through hemoglobin absorption, ensuring rapid hemostasis, reduced operative time, and minimal postoperative discomfort. Compared with conventional surgical approaches, it eliminates the need for sutures and promotes faster healing. These findings, consistent with current literature, support the safety and effectiveness of diode laser therapy in the management of oral vascular anomalies. The 980 nm diode laser represents a reliable, minimally invasive, and well-tolerated treatment option that provides favorable functional and esthetic outcomes with minimal morbidity.

**Keywords:** Oral Vascular Malformation; Venous Malformation; Oral Varix; Diode Laser; 980 nm Laser; Photocoagulation; Minimally Invasive Therapy; Oral Surgery

### Abbreviations

ISSVA: International Society for the Study of Vascular Anomalies; OVM: Oral Venous Malformation

### Introduction

Vascular malformations are intricate congenital abnormalities with varied clinical presentations, progression, and treatment options that profoundly affect patients' lives. Over time, their classification and management have evolved significantly [1].

In 1863, Virchow RLK introduced the first classification system based on microscopic channel architecture. However, the emergence of various classification systems over the years led to confusion, misapplication of terminology, misdiagnoses, and suboptimal management practices. To address these issues, Arnold C. Merrow and colleagues revised the ISSVA (“International Society for the Study of Vascular Anomalies”) classification of vascular lesions, categorizing them into vascular tumors and vascular malformations. The ISSVA system has since become the universally accepted gold standard, with its most recent update published in May 2018 [2].

Various treatments have been employed in managing vascular lesions, including oral corticosteroids, intralesional injections with fibrosing agents, interferon  $\alpha 2b$  therapy, embolization, surgery, and laser therapy [3]. Among these, diode laser treatment stands out as an excellent minimally invasive option. It offers significant therapeutic benefits while minimizing the risk of scarring or mucosal discoloration in most cases, making it a highly favorable choice for patients [4].

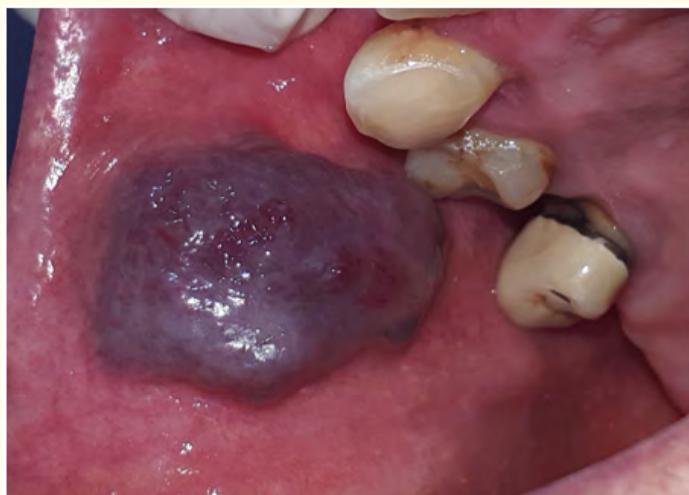### Aim of the Study

The aim of this work is to demonstrate the clinical benefits of using diode laser (980 nm) therapy in the management of oral vascular malformations through the presentation of three detailed clinical cases.

### Materials and Methods

#### Case 1

A 70-year-old female patient with well-controlled hypertension presented with a progressive enlargement of the right buccal mucosa evolving for more than 10 years and causing functional discomfort. Clinical examination revealed a 2.5 cm sessile, purplish-blue lesion with well-defined margins. The lesion was soft, mobile, non-tender, non-indurated, and pulsatile (Figure 1).



**Figure 1:** Clinical aspect of the lesion before treatment of case 1.

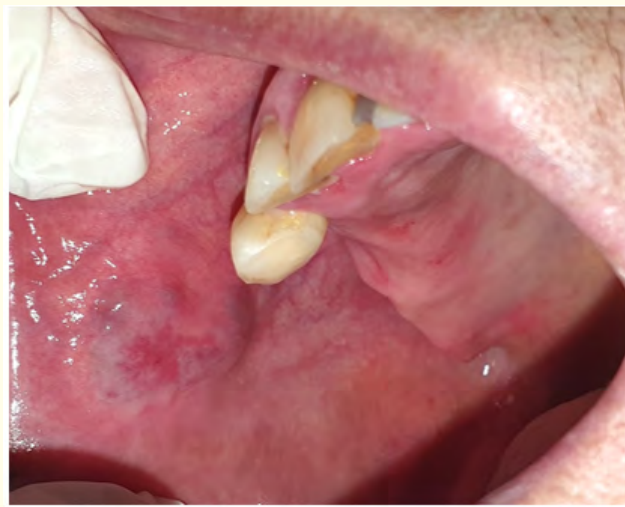No cervical lymphadenopathy was detected. Diascopy was positive, supporting the diagnosis of venous malformation.

Treatment was performed under local anesthesia using a 980 nm high-power diode laser in continuous wave mode (1.0 W; 10 J/cm<sup>2</sup>). A flexible quartz fiber was positioned 2 - 3 mm from the lesion using a non-contact technique with circular movements. Irradiation consisted

of 10-second applications followed by 30-second intervals. Laser application was stopped once tissue whitening and coagulation were achieved. Four sessions were performed at two-week intervals. Paracetamol (1g every 6 hours as needed) was prescribed for three days.

### Case 2

A 55-year-old female patient in good general health presented with multiple oral vascular lesions causing esthetic and functional discomfort. Clinical examination revealed two small (< 0.3 cm) purplish rounded lesions on the right buccal mucosa and one 0.7 cm oval lesion on the ventral surface of the tongue. All lesions were soft, mobile, painless, and pulsatile, with no lymphadenopathy. Clinical features supported the diagnosis of multiple varices (Figure 2).

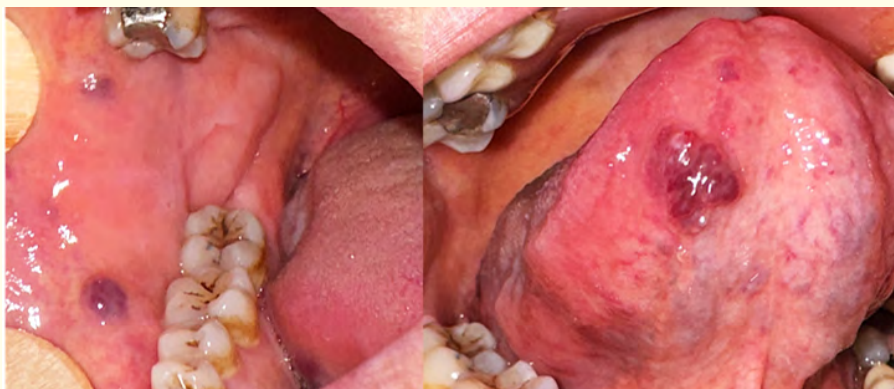

**Figure 2:** Complete shrinkage of the lesion of case 1.

Treatment consisted of one session of 980 nm diode laser photocoagulation using the same protocol described in case 1.

### Case 3

A 60-year-old patient under follow-up for ductal carcinoma and considered for bisphosphonate therapy presented with a 0.5 cm round, painless, purplish-blue lesion on the left buccal mucosa, evolving for more than five years. The lesion was sessile, soft, slightly pulsatile, and well-defined, with no cervical lymphadenopathy. Diascopy confirmed the diagnosis of an oral varix (Figure 3).



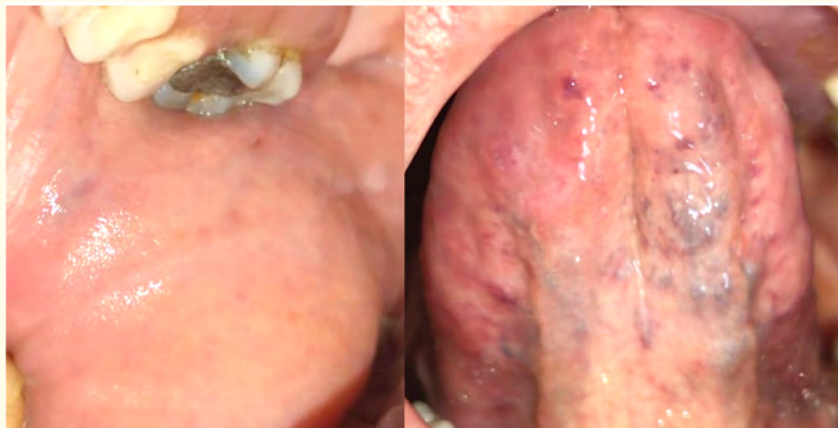
**Figure 3:** Clinical aspect of the lesion before treatment of case 2.

One session of 980 nm diode laser photocoagulation was performed using the same protocol described previously.

## Results

### Case 1

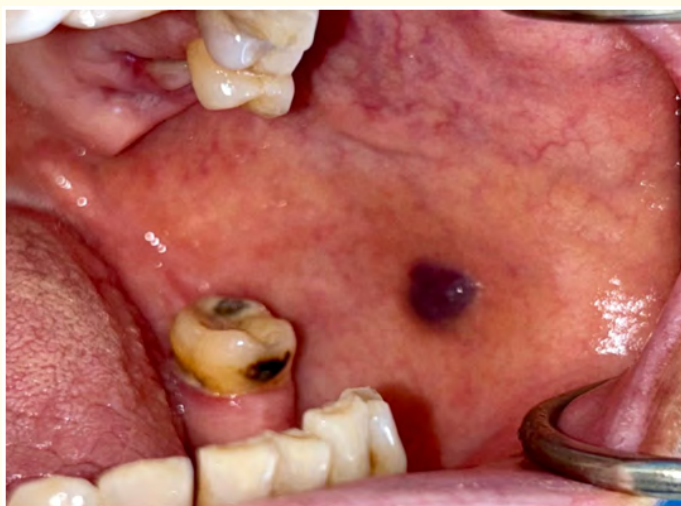Fibrinous exudate formation was observed within 24 hours after each session. The patient reported mild postoperative discomfort without other complications. Three weeks after the final session, complete healing was achieved with no scarring or clinical recurrence (Figure 4).



**Figure 4:** Complete healing 2 weeks after the laser session of case 2.

### Case 2

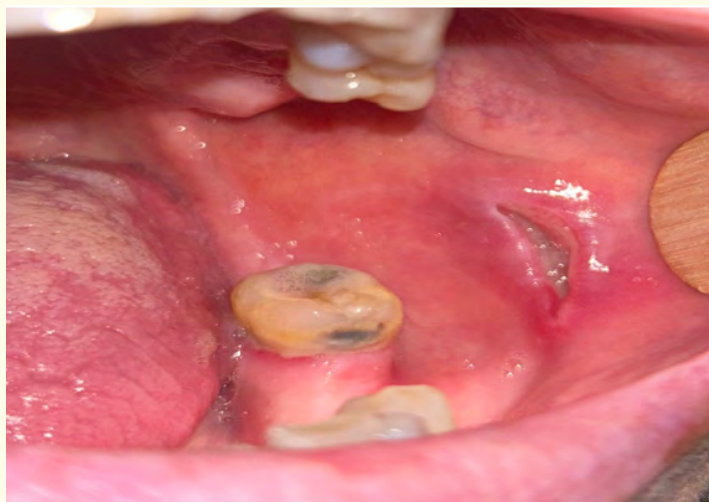At 24 hours, fibrin coating was observed. Complete healing occurred within two weeks. The patient reported no pain or discomfort, and no complications were noted (Figure 5).



**Figure 5:** Clinical presentation of the varix of case 3.

### Case 3

At 24 hours, mild discomfort and fibrin formation were observed. At two weeks, lesion shrinkage was noted. Complete healing was achieved at three weeks without complications (Figure 6).



**Figure 6:** Healing progress at the 2 weeks follow-up of case 3.

### Discussion

Vascular tumors can be benign, locally aggressive or malignant. For benign vascular tumors, it is important to distinguish between infantile hemangiomas and congenital hemangiomas. Infantile hemangiomas typically emerge within the first two months of life, reaching a peak in proliferation between 6 and 12 months. On the other hand, congenital hemangiomas are present at birth, do not undergo a proliferation phase and could evolve rapidly, partially or do not progress at all (non-involuting congenital hemangiomas) [5,6].

Vascular malformations are classified into four sub-groups: simple vascular malformations (capillary, lymphatic, venous, arteriovenous malformations and arteriovenous fistula); combined vascular malformations which is defined as two or more vascular malformations found in one lesion (capillary-venous malformation, capillary-lymphatic malformation...); malformations of major named vessels, and malformations associated with other anomalies [2,6].

In this work, history and clinical behavior favored a diagnosis of venous malformations in the first case, multiple varices in the second case and an oral varix in the third case.

Commonly, due to their benign appearance and lack of progression, vascular malformations do not entail treatment and only need simple observation over time. However, it requires intervention in the case of any symptomatic changes, such as bleeding, functional discomfort related to breathing, speaking, swallowing or disfigurement [5].

Numerous approaches have been established for the management of vascular malformations, including oral propranolol, corticosteroid therapy by oral administration or intralesional injection, and surgical treatment [7].

Among these, laser therapy represents an excellent alternative treatment for hemangiomas, particularly on oral mucosa, due to their capabilities of absorption, diffusion, and transmission, as well as their potential for tissue vaporization, coagulation, and incision. It offers

significant therapeutic benefits such as the absence of intraoperative bleeding and pain, the no need for suturing, which decrease healing time [8,9].

An additional advantage is observed with patients under anticoagulant therapy, as laser therapy does not require any drug suspension, thereby enhancing its minimally invasive nature.

Reports on side effects associated with laser treatment of vascular anomalies are scarce in the literature. When mentioned, erythema, edema and pigmentation changes are the most observed [9].

For all the reasons above, we opted for laser therapy for the management of all the cases previously described. The laser therapy procedure was carried out with a 980 nm high-power diode, continuous pulse laser, in two sessions for the three cases.

Studies indicate that thermal energy of the laser photons spread radially within the blood vessel, inducing selective microvascular effects through photocoagulation. It is important to choose a laser with a wavelength that is well absorbed by hemoglobin.

The wavelengths of diode, Nd:YAG and CO<sub>2</sub> lasers are considered the most effective in the management of hemangiomas.

Suter, *et al.* reported in their study that the excision of minor benign oral lesions by diode lasers was associated with the absence of postoperative complications for most patients compared to CO<sub>2</sub> laser [10]. A report of 2 clinical cases also showed the usefulness of 980-nm diode laser for the management of oral cavity vascular abnormalities [11].

The scientific literature reports the use of diode lasers in the treatment of oral vascular anomalies, with wavelengths of 808 nm, 810 nm, and 940 nm. In a study of 47 patients, Almeida, *et al.* demonstrated the efficacy and the safety of using an 808 nm diode laser in treatment of 47 cases of oral vascular anomalies [12].

Furthermore, Fekrazad, *et al.* described the use of the 810 nm diode laser as a conservative approach for the treatment of oral hemangioma, using a defocused irradiation mode [13].

The use of high-power diode lasers in the treatment of vascular lesions significantly reduces intraoperative bleeding, which consequently shortens operative time and allows for faster postoperative hemostasis. This effect is due to the high absorption of laser photons by hemoglobin molecules within the tumor vessels [14,15].

It is also important to mention that this absorption can be affected by several factors such as the size of vessels, depth of the lesion, and laser spot size [16].

Another clinical case study investigated postoperative evolution of 40 hemangiomas and venous malformations cases treated by diode laser. It concluded that Intralesional diode laser therapy is a safe and effective modality for managing hemangiomas and venous malformations providing significant cosmetic and functional benefits with a low recurrence rate [17].

In summary, diode laser photocoagulation (regardless of the wavelength) is a suitable tool for the treatment of oral venous malformations which offer a very efficient results and promoted rapid postoperative hemostasis with no intra or postoperative complications or discomfort for patients.

### Conclusion

Oral venous malformations are benign vascular tumors that are common in the head and neck but rare in the oral cavity. OVM usually do not require treatment.

For symptomatic OVM, several options can be taken to manage it. Compared to conventional techniques, diode laser therapy shows excellent results without significant complications.

Besides all, it is an affordable treatment option that ensures a high level comfort for both the patient and the clinician.

### Conflict of Interest

No conflict of interest.

### Bibliography

1. Carqueja Inês M., *et al.* "Vascular malformations: classification, diagnosis and treatment". *International Angiology: A Journal of the International Union of Angiology* 37.2 (2018): 127-142.
2. Ramakrishnan Karthik., *et al.* "Management of vascular malformations in the oral and maxillofacial region: A systematic review". *Journal of Stomatology, Oral and Maxillofacial Surgery* 122.6 (2021): 588-599.
3. Genovese Walter João., *et al.* "The use of surgical diode laser in oral hemangioma: a case report". *Photomedicine and Laser Surgery* 28.1 (2010): 147-151.
4. Van Doorne L., *et al.* "Diagnosis and treatment of vascular lesions of the lip". *The British Journal of Oral and Maxillofacial Surgery* 40.6 (2002): 497-503.
5. Lyssy Lauren A., *et al.* "Oral Hemangiomas". StatPearls, StatPearls Publishing (2023).
6. Buckmiller L M., *et al.* "Diagnosis and management of hemangiomas and vascular malformations of the head and neck". *Oral Diseases* 16.5 (2010): 405-418.
7. DeHart Austin., *et al.* "Hemangioma: Recent advances". *F1000Research* 8 (2019): F1000 Faculty Rev-1926.
8. Warriar S Aravind., *et al.* "Capillary hemangioma managed with laser ablation: a case report". *Journal of Lasers in Medical Sciences* 14 (2023): e39.
9. Farghaly Mohamed Ashraf., *et al.* "The role of diode laser in management of oral hemangiomas and venous malformations". *Journal of Indian Association of Pediatric Surgeons* 30.4 (2025): 464-468.
10. Suter Valérie G., *et al.* "CO<sub>2</sub> and diode laser for excisional biopsies of oral mucosal lesions. A pilot study evaluating clinical and histopathological parameters". *Schweizer Monatsschrift für Zahnmedizin* 120.8 (2010): 664-671.
11. Bouzoubaa Sidi Mohammed., *et al.* "Management of oral vascular anomalies with diode laser: report of 2 clinical cases". *Lasers in Dental Science* 4.2 (2020): 97-101.
12. Heimlich Fernanda Vieira., *et al.* "Experience with 808-nm diode laser in the treatment of 47 cases of oral vascular anomalies". *Brazilian Oral Research* 38 (2024): e025.
13. Fekrazad Reza., *et al.* "Defocused irradiation mode of diode laser for conservative treatment of oral hemangioma". *Journal of Lasers in Medical Sciences* 4.3 (2013): 147-150.

14. Sarfi Dounia., *et al.* "Diode laser photocoagulation of intraoral (and perioral) venous malformations: Cases series". *International Journal of Surgery Case Reports* 88 (2021): 106436.
15. Vidor Marcia M., *et al.* "Importance of the right protocol in using a diode laser (980 nm) for small oral vascular malformation treatment". *Cureus* 15.1 (2023): e33643.
16. Azma Ehsan and Melika Razaghi. "Laser treatment of oral and maxillofacial hemangioma". *Journal of Lasers in Medical Sciences* 9.4 (2018): 228-232.
17. Farghaly Mohamed Ashraf., *et al.* "The role of diode laser in management of oral hemangiomas and venous malformations". *Journal of Indian Association of Pediatric Surgeons* 30.4 (2025): 464-468.

**Volume 25 Issue 5 May 2026**

**©All rights reserved by Hajar Benhaïoun., *et al.***