

Roll Flap Technique to Enhance Buccal Gingival Thickness and Implant Emergence Profile: A Case File

Sourav Chowdhury¹, Vijayshree Pandey², Prashant Dwivedi³, Amrita Dutta⁴, Kasif Ahmad⁵, Verma Malti Sanjeev Kumar⁵, Dipanwita Dutta⁶, Garima Singh^{7*}, Dipti Singh⁸ and Sudhanshu Agrawal^{9*}

¹PG Student (JR III), Department of Periodontology, Chandra Dental College and Hospital, Barabanki, India

²PG Student (JR I), Department of Periodontology, Chandra Dental College and Hospital, Barabanki, India

³PG Student (JR I), Department of Oral Pathology and Microbiology, Chandra Dental College and Hospital, Barabanki, India

⁴Assistant Professor, Department of Periodontology, Kusum Devi Sunderlal Dugar Jain College and Hospital, Kolkata, India

⁵PG Student (JR II), Department of Periodontology, Chandra Dental College and Hospital, Barabanki, India

⁶PG Student (JR I), Department of Endodontics, Chandra Dental College and Hospital, Barabanki, India

⁷Associate Professor, Department of Periodontology, Chandra Dental College and Hospital, Barabanki, India

⁸Professor and Head, Department of Oral Medicine and Radiology, Chandra Dental College and Hospital, Barabanki, India

⁹Professor, Department of Periodontology, Chandra Dental College and Hospital, Barabanki, India

***Corresponding Author:** Sudhanshu Agrawal, Professor, Department of Periodontology, Chandra Dental College and Hospital, Barabanki, India and Garima Singh Associate Professor, Department of Periodontology, Chandra Dental College and Hospital, Barabanki, India.

Received: December 07, 2023; **Published:** January 10, 2024

Abstract

Purpose: Several techniques have been developed to enhance the buccal gingival breadth, gingival height and contour surrounding the implant. In this case file, a buccal rotational flap was used to improve the buccal emergence profile of implant site and increase gingival tissue thickness.

Case Report: A 35-years old patient with a non restorable decayed root 46 was selected. After an atraumatic extraction of the retained root, an immediate implant was placed. This case involves the use of a rotational flap during second-stage implant surgery performed after 3 months of implant placement, with the use of a modified healing abutment to attain a thick gingival collar.

Result: The case was followed up until the final crown was placed. The implant site was improved in this case; the buccal gingival thickness was increased, the gingival level was enhanced and the emergence profile was developed.

Conclusion: Results of roll flap technique are affected by many factors. They include the anatomical, surgical, biological and prosthetic factors.

Keywords: Rolling of Flap; Emergence Profile; Atraumatic Extraction; Immediate Implant

Introduction

The placement of an implant requires comprehensive knowledge of anatomy. It requires evaluation of tissue breadth, tissue height and the healing process, along with good surgical skills [1]. The ideal need of tissue around the implant is thick attached keratinized gingiva [2]. An adequate gingival attachment level, the existence of interdental papillae, and the contour of the crown are mandatory for achieving a healthy periodontium around the implant [3,4]. Several techniques have been applied to improve the soft tissue profile around the implant, such as the AlloDerm roll technique, along with or without connective tissue grafts [5-7].

Connective tissue grafts serve a good for achieving adequate gingival thickness and increasing gingival level but do need a second surgical site. They fail to provide color match with the receptor site and sometimes result in tissue shrinkage and necrosis even though done with high professional skills [9-12].

The roll technique is used to enhance the gingival margin thickness when the defect is smaller than 3 mm. This technique can be used in stage two surgery to enhance the labial gingival contour and the implant emergence profile [10,13]. The roll technique has many advantages and disadvantages. Advantages are the roll techniques helps in achieving a better emergence profile, with less scar tissue formation, more stable gingival margin, with no secondary site of surgery, maintains the blood supply to the rotated part, shorter healing period and faster tissue maturation, no need for advanced professional skills, cost effective and tissue harmony around the implant. While disadvantages are that it does not change the gingival biotype, tissue loss may occur at the implant site, not applicable for multiple implants, does not improve the interdental papillae level and it may leave a scar at the esthetic zone [14].

Case File

A 35-years old patient came in OPD of Chandra Dental College and Hospital, Barabanki (UP) with a non restorable decayed root 46. Treatment steps was explained and discussed with patient which included removing the retained root and placing an implant to allow for soft and bony tissue healing. After an atraumatic extraction of the retained root, an immediate implant was placed; a full-thickness envelope was raised with the adjacent papillae. Bone recontouring was done as per selected size of implant, and an implant 12 mm in length and 4.5 mm in diameter was placed. The implant was placed with moderate stability (torque 40 Ncm). The cover screw was placed, the flap was approximated, and the implant was completely covered. The implant was left to heal for 3 months, after which soft tissue and hard tissue was evaluated clinically (Figure 1a) and radiographically (Figure 1b) for re-entry surgery. Second surgery was performed by raising a three-sided flap that excluded the adjacent papillae. A buccal crestal incision was made, the cover screw was removed, and a modified healing abutment with a gingival collar with of flowable composite was prepared. The modified healing abutment was small in shape (diameter and length) with open contact with adjacent teeth to allow soft tissue growth and thickening. The healing abutment was torqued into place.

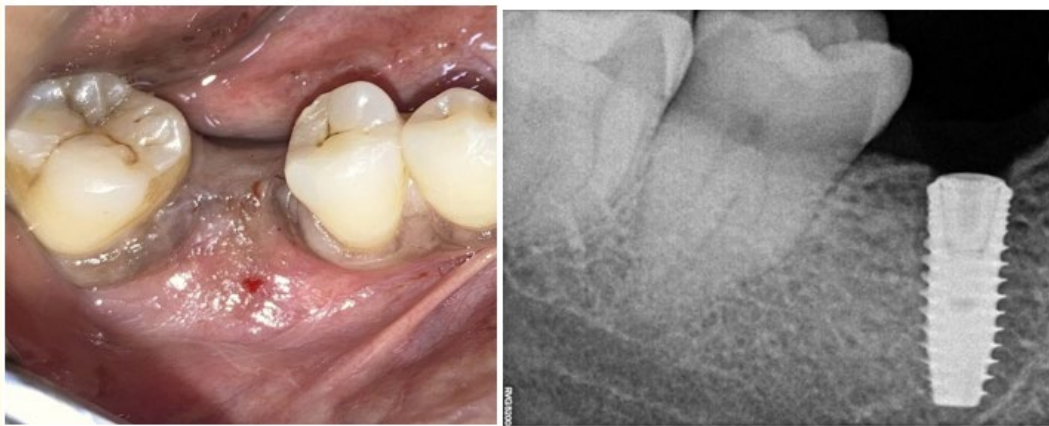


Figure 1a and 1b: Clinical image and radiographic image of healing after 3 months of extraction of retained root 46, and placement of an immediate implant.

One of the most important steps is the proper de-epithelialization. So, de-epithelization with done with B.P. blade no 11 and enabling the flap to be rotated inward and was adapted with the keratinized mucosa facing the healing abutment (Figure 2) and simple interrupted suturing was performed to fix the rotated flap buccally against the abutment (Figure 3). The healing abutment was ensured to be kept out of occlusion during centric movement and excursion. After one week, the suture was removed, and the wound healed uneventfully.

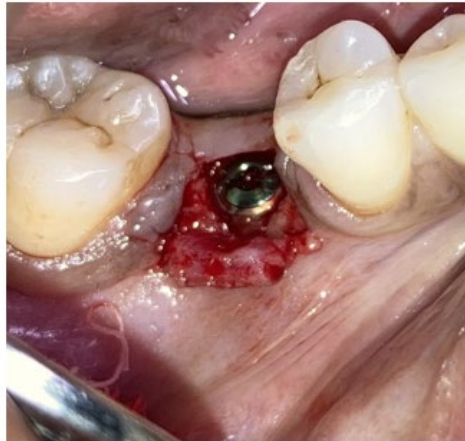

Figure 2: Second stage surgery is performed 3 months after implant placement and buccal rotational flap performed simultaneously with a modified healing abutment with flowable composite. A three-sided flap with a more lingually placed crestal incision and the papillae reserved is created. After de-epithelization with scalpel, two vertical incisions are made to the vestibule so that the flap could be freely rotated.

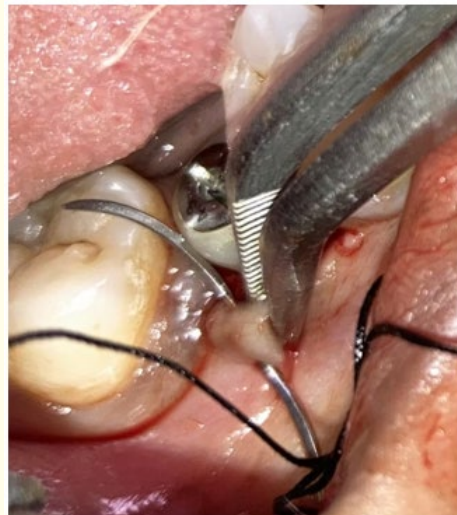


Figure 3: Suturing was performed buccally to fix the rotated flap against the abutment.

After one month, the treated site was evaluated with complete soft tissue maturation, to reveal an excellent emergence profile (Figure 4). The modified healing abutment was then removed (Figure 5), perfect thick gingival collar was attained and impression coping was screwed into the implant temporarily to make an impression. The permanent crown was placed, excess cement was removed, and occlusion was adjusted. The patient was seen again after 3 months, at which time the papillae were almost filling the interdental space and the scar was faded (Figure 6).

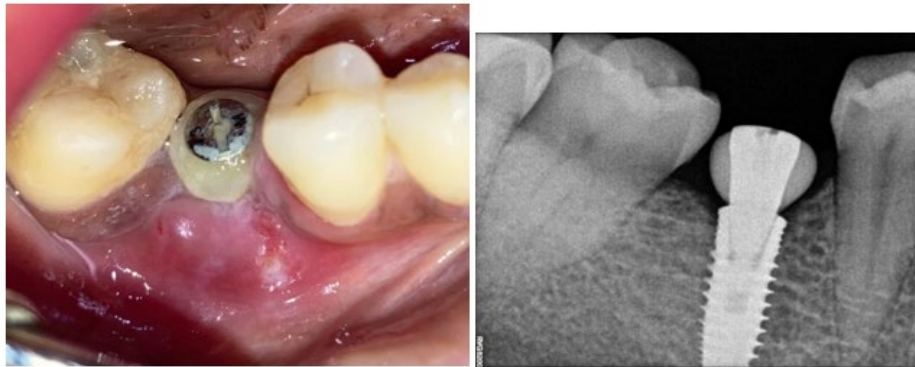

Figure 4: After 10 days, soft tissue healing is evaluated clinically and bone level is evaluated radiographically.

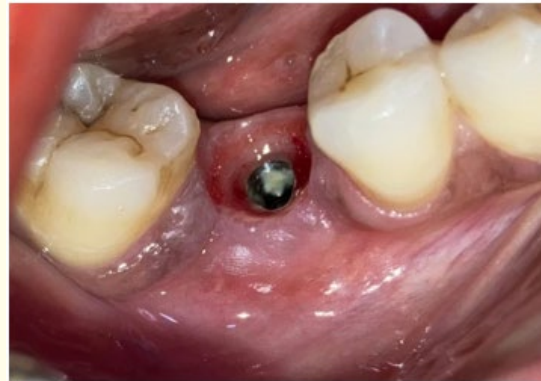

Figure 5: The healing abutment was then removed and perfect thick gingival collar was attained.

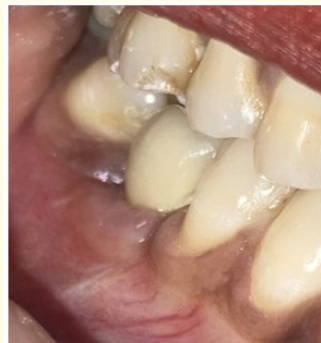

Figure 6: Final prosthesis is placed, and adequate gingival breadth is achieved.

Discussion

Achieving an adequate gingival tissue collar is the key to success in implant dentistry. Reduced gingival breadth and gingival recession are common challenges after tooth extraction and implant placement [14-19].

In this case, an immediate implant placement regimen was followed, but it resulted in the occurrence of buccal bone reduction that required a roll flap during the second stage surgery to address the buccal defect.

Since, a buccal gingival roll flap has many advantages when was used to increase the thickness of the gingiva and improve the crown appearance buccally. Harvesting the flap adjacent to the donor site gives additional advantage that it avoids second-site surgery and beneficial over the connective tissue graft, which is harvested from the palate [9,10].

The healing phase showed that, no shrinkage of the mucosa and no changes in color when the roll flap is placed at the gingival donor site [8,9].

Risk of graft loss or necrosis was negligible as the rolled flap provides the blood supply to the grafted part of the gingiva. This technique requires less skills as it is not very technique sensitive and provides a shorter healing time compared with a connective tissue graft. This technique provides thick gingival breadth that is needed to achieve better contour. Additionally, it increases the thickness of the gingiva to provide more soft tissue stability around the implant for the long term when compared with AlloDerm [8].

Some considerations must be followed to achieve better results while using the roll flap. Firstly, adequate amount of flap tissue thickness needs to be rotated to improve the gingival contour. Secondly, sufficient amount of keratinized tissue should be present buccally at the donor site before the roll flap is started (Presented case had more than 5 mm buccal). Thirdly, a papillae-preserving flap should be raised buccally to prevent the interdental papillary loss [20].

However, there are numerous surgical, prosthetic, biological and anatomical factors, procedures and elements that contribute in successful rotational flap technique. Surgical factors are namely choosing a flap design with papilla preservation flap, avoiding a vertical cut on the keratinized mucosa and more palatal/lingual placement of the crestal incision. Prosthetically elements that need to be kept in mind are proper implant position (not ending with a ridge lab crown), concave provisional crown at the cervical area and smooth crown surface. Biologically, gingival tissue grafted changes according to the donor site of the implant, thus should be considered and evaluated consistently. Keeping in mind the anatomical aspect, oral mucosal tissue changes according to the type of surface facing the implant and their should be adequate thickness of the rotated flap (> 1.5 mm).

The surgical procedure cannot regenerate the papillae, but the surgery should be conservative and should not include the papillae from the first surgery [21]. This technique does not improve the interdental papillae level as the papillae depend on the crestal bone-contact point distance [22].

This technique does not involve making a vertical incision in the keratinized mucosa, which avoids the formation of an unpleasant scar. Instead, the surgeon can use a pouch and tuck the rotated flap inside [10]. Using a temporary prosthesis will improve the gingival emergence profile to mimic a natural tooth profile [20].

The breadth of the rolled gingiva is crucial in this procedure to create more bulge and thickness on the buccal side of the implant [10].

Conclusion

The use of the roll flap technique can improve and enhance horizontal concavity of the buccal bone and enhance the breadth and level of the gingival margin level around the final prosthesis of implant. Thus increasing buccal gingival thickness and improved buccal contour.

Bibliography

1. Kois JC. "Predictable single tooth peri-implant esthetics: Five diagnostic keys". *Compendium of Continuing Education in Dentistry* 22.3 (2001): 199-206.
2. Müller H-P and Eger T. "Masticatory mucosa and periodontal phenotype: A review". *International Journal of Prosthodontics and Restorative Dentistry* 22.2 (2002): 172-183.
3. Chang M., et al. "Implant supported single-tooth replacements compared to contralateral natural teeth. Crown and soft tissue dimensions". *Clinical Oral Implants Research* 10.3 (1999): 185-194.
4. Cardaropoli D., et al. "Socket preservation using bovine bone mineral and collagen membrane: A randomized controlled clinical trial with histologic analysis". *International Journal of Prosthodontics and Restorative Dentistry* 32.4 (2012): 421-430.
5. Cranin AN. "Implant surgery: The management of soft tissues". *Oral Implantology* 28.5 (2002): 230-237.
6. Le B and Burstein J. "Esthetic grafting for small volume hard and soft tissue contour defects for implant site development". *Implant Dentistry* 17.2 (2008): 136-141.
7. Saade J., et al. "Pouch roll technique for Implant soft-tissue augmentation of small defects: Two case reports with 5-years Follow-Up". *Journal of Oral Implantology* 41.3 (2015): 314-320.
8. Harris RJ. "A short-term and long-term comparison of root coverage with an acellular dermal matrix and a subepithelial graft". *Journal of Periodontology* 75.5 (2004): 734-743.
9. Oates TW., et al. "Surgical therapies for the treatment of gingival recession: A systematic review". *Annals of Periodontology* 8.1 (2003): 303-320.
10. Park S-H and Wang H-L. "Pouch roll technique for implant soft tissue augmentation: A variation of the modified roll technique". *International Journal of Prosthodontics and Restorative Dentistry* 32.3 (2012): e116-e121.
11. Rosetti EP, et al. "Treatment of gingival recession: Comparative study between subepithelial connective tissue graft and guided tissue regeneration". *Journal of Periodontology* 71.9 (2000): 1441-1447.
12. Hirsch A., et al. "A 2-years follow-up of root coverage using sub-pedicle acellular dermal matrix allografts and subepithelial connective tissue autografts". *Journal of Periodontology* 76.8 (2005): 1323-1328.
13. Giordano F, et al. "Roll technique modification: Papilla preservation". *Implant Dentistry* 20.3 (2011): e48-e52.
14. Juboori MJ AL. "Rotational flap to enhance buccal gingival thickness and implant emergence profile in the esthetic zone: Two Case Reports". *The Open Dentistry Journal* 11 (2017): 284-293.
15. Hu "rzeler MB., et al. "Stage-two implant surgery in the aesthetic zone: A new technique". *International Journal of Prosthodontics and Restorative Dentistry* 30 (2010): 187-193.
16. Araújo MG and Lindhe J. "Dimensional ridge alterations following tooth extraction: An experimental study in the dog". *Journal of Clinical Periodontology* 32.2 (2005): 212-218.
17. Vignoletti F, et al. "Surgical protocols for ridge preservation after tooth extraction: A systematic review". *Clinical Oral Implants Research* 23.5 (2012): 22-38.
18. Thoma DS., et al. "Evaluation of a new biodegradable membrane to prevent gingival ingrowth into mandibular bone defects in minipigs". *Clinical Oral Implants Research* 20.1 (2009): 7-16.

19. Cardaropoli D, *et al.* "Socket preservation using bovine bone mineral and collagen membrane: A randomized controlled clinical trial with histologic analysis". *International Journal of Periodontics and Restorative Dentistry* 32.4 (2012): 421-430.
20. Al-Juboori MJ. "The influence of flap design and technique on dental implant success, prognosis and morbidity: Mini review". *International Journal of Contemporary Dental and Medical Reviews* (2015): 161214.
21. Al-Juboori MJ. "Interdental implant papillae grow up with temporary abutment displaced at monthly intervals". *Journal of Contemporary Dental Practice* 16.5 (2015): 422-426.
22. Tarnow DP, *et al.* "The effect of inter-implant distance on the height of inter-implant bone crest". *Journal of Periodontology* 71.4 (2000): 546-549.

Volume 23 Issue 1 January 2024

©All rights reserved by Sudhanshu Agrawal, *et al.*