

Andrews Bridge System - Method for Esthetic Rehabilitation in Anterior Ridge Defects Cases: Case Report

Shanta Chopra¹, Arpit Sikri^{2*}, Suvansh Gupta³ and Jyotsana Sikri⁴

¹M.D.S (Prosthodontics), India

²Senior Lecturer, Department of Prosthodontics, Santosh Dental College and Hospital, Santosh Deemed to be University, Ghaziabad (Delhi NCR), India

³Post Graduate, Department of Orthodontics, Genesis Institute of Dental Sciences and Research, Ferozepur, Punjab, India

⁴Senior Lecturer, Department of Conservative Dentistry and Endodontics, Santosh Dental College and Hospital, Santosh Deemed to be University, Ghaziabad (Delhi NCR), India

***Corresponding Author:** Arpit Sikri, Senior Lecturer, Department of Prosthodontics, Santosh Dental College and Hospital, Santosh Deemed to be University, Ghaziabad (Delhi NCR), India.

Received: October 28, 2020; **Published:** January 30, 2021

Abstract

Tooth loss due to Trauma, Periodontal problems, congenital defects can lead to severe alveolar ridge defects. These defects to be treated are not an easy task for Prosthodontics. In these cases, neither conventional fixed denture prosthesis nor removable partial denture can be planned. Implants procedure cannot be carried due to severe bone loss. Andrew's bridge can be a treatment of choice in these cases. It is a combination of removable and fixed denture prosthesis. This case report describes the fabrication of Andrew's bridge using a bar system as a component of removable partial denture and abutments as a fixed component in patients with Seibert Class III defect.

Keywords: Alveolar Ridge Defect; Implant; Andrew's Bridge; Bar System; Seibert Class III

Introduction

Prosthodontics is defined as a dental specialty about the diagnosis, treatment planning, rehabilitation, and maintenance of the oral function, comfort, appearance, and health of patients with clinical conditions associated with missing or deficient teeth and/or maxillo-facial tissues by using bio-compatible substitutes (GPT-9). Alveolar ridge defect due to trauma, periodontal problems, congenital defects often require more attention to achieve aesthetics, comfort, and masticatory function. Ridge defects are classified by Seibert in 1983 (Figure 1)

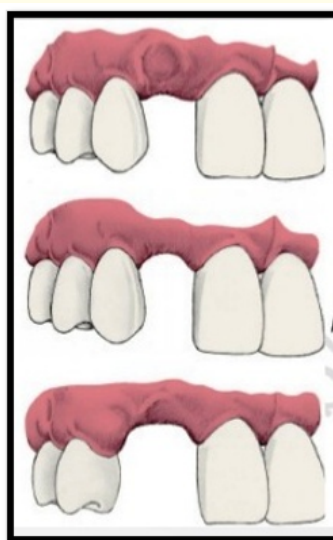


Figure 1

Class-I: Bucco-lingual loss of tissues.

Class-II: Apico-coronal loss of tissues.

Class-III: combination of bucco-lingual and apico-coronal loss of tissues.

In these cases, removable partial dentures are not accepted by the patient as they have compromised aesthetics and retention. The fixed prosthesis also cannot be given without bone grafting which makes treatment expensive and complex. So to overcome these problems, Dr. James Andrew's Amite Louisiana in 1975 [1]. introduced the first fixed removable partial denture. Fixed components are porcelain fused to metal crowns with prefabricated bar and removable components include a sleeve with an acrylic removable partial denture.

Case Report

A 40-year-old female patient reported to the Department of Prosthodontics, Dasmesh Institute of Dental Research and Science, Punjab with a chief complaint of missing lower anterior teeth. Her dental history revealed that she lost her teeth due to mobility 3 years back. She was wearing removable partial denture but was not happy with the aesthetics. Intra-oral examination revealed missing mandibular central and lateral incisors with Siebert's class III [2] ridge defect and abutment teeth have good bone support for fixed prosthesis (Figure 2). Moreover Patient had generalized intrinsic staining due to severe fluorosis.

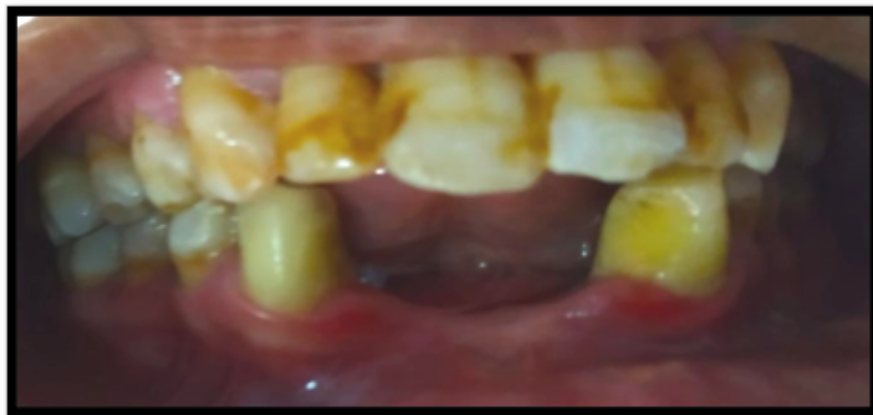

Figure 2

Treatment options

- Conventional removable partial denture.
- Surgical bone grafting followed by implant placement.
- Andrews fixed-removable partial denture.

The patient had already worn removable partial denture and was not satisfied with the aesthetics. The patient was not willing for implant placement since the success of the graft and implant were not assured moreover it is an expensive treatment. Ultimately, the Patient opted for Andrew's Bridge.

- Mandibular canines were chosen as abutments.
- After oral Prophylaxis, 33 and 43 were prepared to the desired height with flat end tapered diamond rotary bur with a chamfer finish line. Definitive impression was made with polyvinylsiloxane (Flexceed, GC) and was poured in type IV gypsum product (Kalabhai, Ultrarock) (Figure 3).
- Wax coping for metal-ceramic restoration was fabricated and the prefabricated plastic bar was attached on the mesial aspect of the wax pattern (Figure 4).
- Wax pattern was cast in chrome cobalt alloy (Bego, Germany), metal try-in done and marginal fit of the prosthesis was evaluated.
- Porcelain fused to metal was evaluated and required adjustment was done followed by cemented with glass ionomer cement (GC, America) (Figure 5).
- Picked up Putty impression made and the cast was retrieved (Figure 6).
- The plastic rider was placed over the bridge and anterior teeth arrangement was completed (Figure7).
- Anterior try in done and wax-up of the denture was completed.
- Denture fabricated with heat-cured acrylic resin using a compression molding technique. After the dewaxing procedure, the plastic rider component was visible and heat cured acrylic was packed (Figure 8).
- After Finishing and polishing of the denture, the plastic rider was removed was done and metal housing was placed on the bar (Figure 9).
- Yellow retention clips were picked up using auto-polymerizing resin (Figure 10)
- Oral hygiene instructions were given to the patient and regular follow up were scheduled (Figure 11).

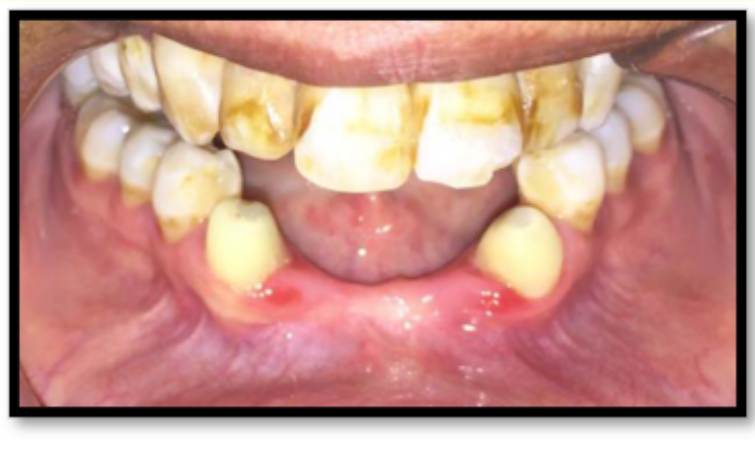

Figure 3

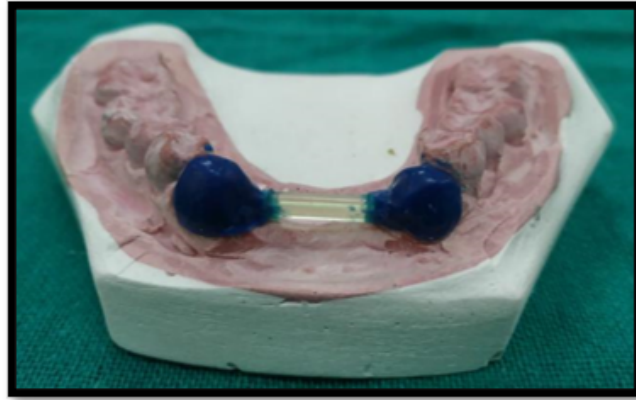


Figure 4

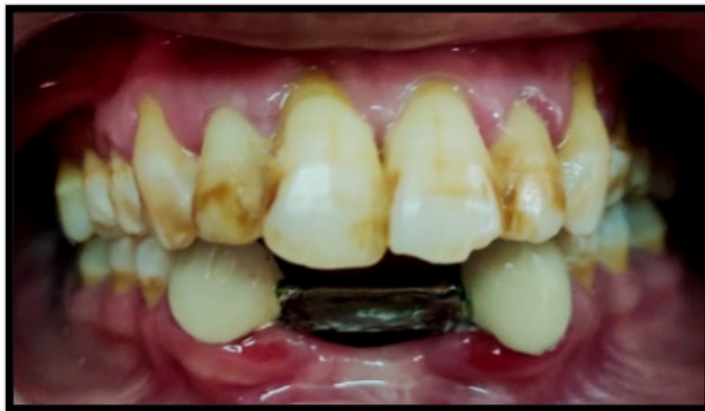

Figure 5

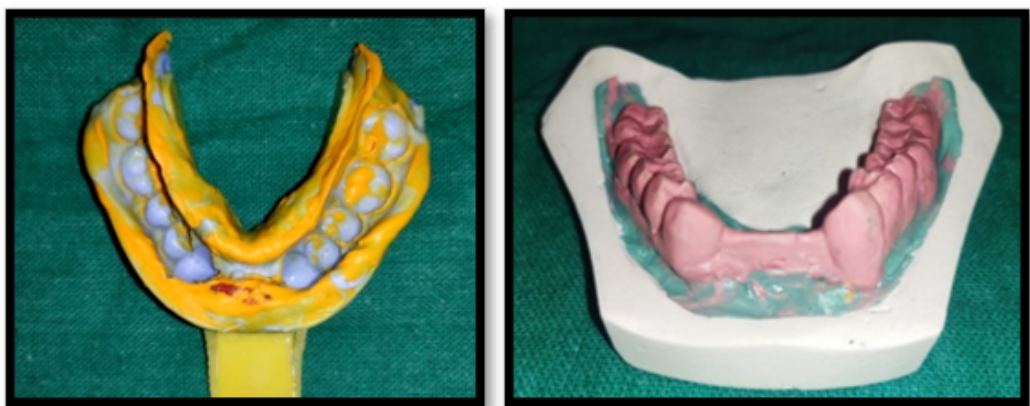

Figure 6

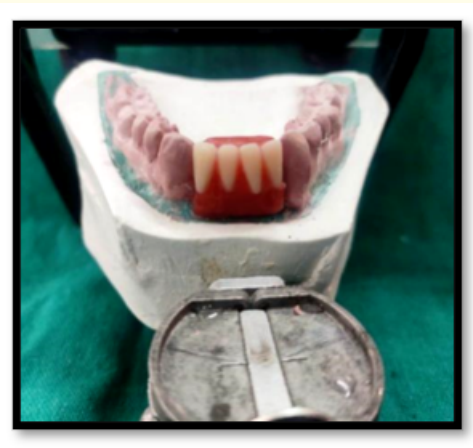

Figure 7

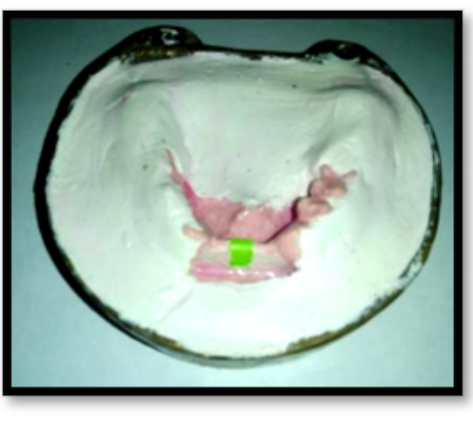


Figure 8

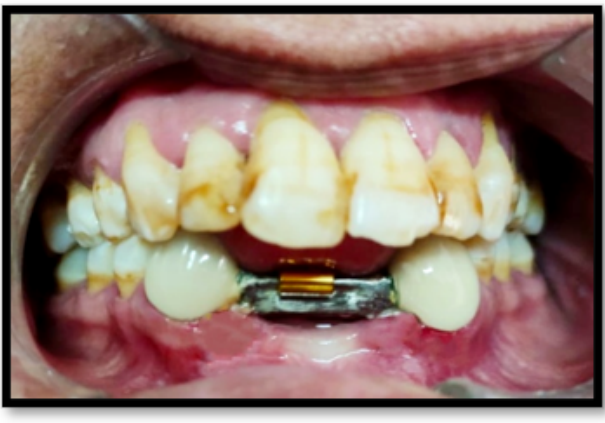

Figure 9

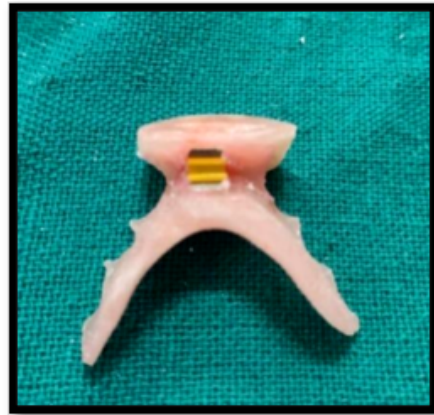

Figure 10

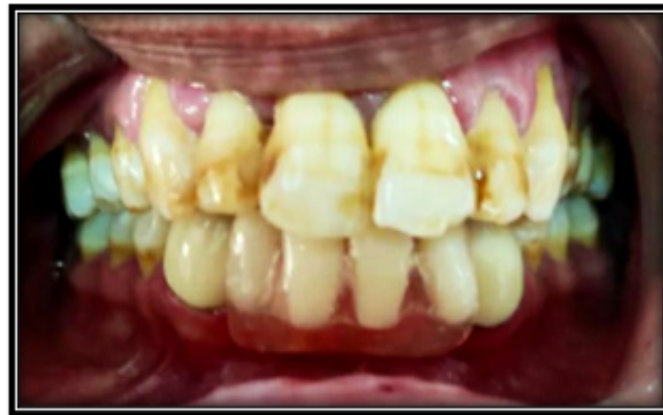

Figure 11

Discussion

After tooth loss, there are high incidences of about 91% of anterior ridge defect. The most commonly seen defects are the combined Class III defects (56% of cases) [3]. Rehabilitation of these defects is often challenging to do. Giving removable partial denture will be a discomfort to the patient and fixed prosthesis will be highly unaesthetic due to the formation of a black triangle, potential food trap, difficult to floss. Rehabilitation with an implant will be time-consuming and need bone grafts [4].

So Andrew's bridge is a promising treatment in the rehabilitation as its acrylic saddle provides improved aesthetics [5,6], eliminates food traps, improves phonetics, and can be easily removed by the patient for hygiene access.

Bibliography

1. Andrews JA. "The Andrew's Bridge: A Clinical Guide". Covington, LA: Institute of Cosmetic Dentistry; (1976): 3-7.
2. Seibert JS. "Reconstruction of deformed, partially edentulous ridges, using full thickness onlay grafts. Part I. Technique and wound healing". *Compendium of Continuing Education in Dentistry* 4 (1983): 437-453.
3. Garber DA and Rosenberg ES. "The edentulous ridge in fixed prosthodontics". *Compendium of Continuing Education in Dentistry* 2 (1981): 212-223.
4. Andrews JA and Biggs WF. "The Andrews bar-and-sleeve-retained bridge: A clinical report". *Dentistry Today* 18 (1999): 94-96.
5. Mueninghoff KA and Johnson MH. "Fixed-removable partial denture". *The Journal of Prosthetic Dentistry* 48 (1982): 547-550.
6. Chandra S., *et al.* "Treatment using functionally fixed prosthesis: A case report". *The Journal of Indian Prosthodontic Society* 41.1 (2014): 206-209.

Volume 20 Issue 2 February 2021

©All rights reserved by Arpit Sikri., *et al.*