

Periodontal Surgery and Operative Dentistry

Mohamed Hany Ahmad Abd Elghany^{1*}, Rakan Mohammed Abulaban², Ayman Alawi Bafaqeh², Fayez Saeed Alzahrani², Mahmoud Abdulalah Khatiri², Ayman Abdullah Alhaidari², Zuhair Osama Orkouby³, Abdulrahman Eyad Abulfaraj³, Ahmed Mohammed Ibrahim³, Hend Abdulrahim Lal Akhtar³, Abdulaziz Talal Maleh⁴ and Ashraf Salem Alhujaili⁵

¹Cairo University, Saudi Arabia

²Ministry of Health, Saudi Arabia

³Taibah University, Saudi Arabia

⁴Ibn Sina National college, Saudi Arabia

⁵Qassim University, Saudi Arabia

***Corresponding Author:** Mohamed Hany Ahmad Abd Elghany, Cairo University, Saudi Arabia.

Received: November 19, 2020; **Published:** December 11, 2020

Abstract

Introduction: A good periodontal health is of utmost importance in maintaining the long-term success of any restoration or prosthetic rehabilitation. If the basic laws of periodontal surgery are not followed, especially in cases of subgingival restorations, then the risk of failure of the restoration increases. In cases where the periodontal health is not diagnosed or not treated before the restoration is done are bound to fail in the long term. Similarly, cases where the restoration is improper with overhanging margins may cause increased accumulation of plaque and calculus, leading to failure of the restoration as well as periodontal bone loss.

Aim of Work: This review article aims at describing various considerations of operative dentistry that affect the periodontal health and periodontal factors that affect the margins of the restoration. It furthers emphasizes various periodontal surgical procedures that help in the longevity of the restorations.

Methodology: This review is a comprehensive research of PUBMED and Google scholar from 1990 - 2020.

Conclusion: The ultimate goal of any dental treatment is to maintain the natural dentition in its actual form. Any restorative phase should always be preceded by periodontal treatment. For a long term survival of any restoration, the restorative and periodontal phase should always be in harmony. Management of the gingival tissue is of high importance as it decides whether the prosthesis that is fabricated is properly fitting. A preoperative interdisciplinary management plan of the tooth is of utmost importance before going on with any particular treatment as the sequence in which the treatment should be done greatly affects the outcome of the treatment.

Keywords: External Bevel Gingivectomy; Biological Width; Splinting; Crown Lengthening; Root Resection

Introduction

Good periodontal health is of utmost importance in maintaining the long-term success of any restoration or prosthetic rehabilitation. Suppose the basic laws of periodontal surgery are not followed, especially in cases of subgingival restorations, then the risk of failure of the restoration increases. The tissue surface in the interproximal area should also be maintained as it can lead to gingival inflammation leading to resorption of bone and loss of tissue attachment. An adequate margin of the restoration is important to maintain good oral

hygiene by the patient, which in turn reduces the incidence of recurring caries. The gingival interface at the restorative margin poses a challenge to the dentist as the health of the periodontium is continuously affected by the existing microbial flora of the region, and during the restorative procedure, it may get affected and worsen the periodontal health, thereby decreasing the longevity of the restoration [1].

In the case of a restorative or prosthetic restoration, the trauma, the aggravation of existing flora, or a combination of both causes the loss of periodontal attachment. Furthermore, the loss of attachment of periodontium also gets affected by the susceptibility of the host, the strain and severity of the bacteria, the efficiency and immunity of the surrounding tissue structure. The morphology, the quality of the margins of the restoration, and the location of the restoration margin also affect the periodontal attachment. According to Glickman's theory, any restoration that is placed in an individual's mouth has a periodontal dimension. If a perfect restoration is placed in a mouth with poor periodontal health or a poor restoration is placed in a mouth with good periodontal health, in both these cases, the longevity of the restoration will be adversely affected. In cases where the periodontal health is not diagnosed or not treated before the restoration is done are bound to fail in the long term. Similarly, cases where the restoration is improper with overhanging margins may cause increased accumulation of plaque and calculus, leading to failure of the restoration as well as periodontal bone loss [2].

The location of the margins of restoration and crowns in relation to the height of the alveolar bone helps in determining the long term success of the restoration, as any margin that affects the competence of the surrounding tissue or immunity of the host will lead to the accumulation of microorganisms that can cause damage to the health of the periodontium. This review article talks in brief about the various considerations of operative dentistry that affect the periodontal health and periodontal factors that affect the margins of the restoration. It further emphasizes various periodontal surgical procedures that help in the longevity of the restorations [1].

Importance of elimination of periodontal diseases prior to the restorative phase

Any periodontal disease should be treated prior to the restorative phase of the patient; it helps in locating the proper margin of the restoration. In case the inflammation of the gingiva is not reduced, and the restoration margins are placed on that, the gingiva shrinks and takes a new position after treatment that can cause an irregular margin of the restoration. During a periodontal disease, the position of the tooth may change due to inadequate bone support; in case the restorative phase is done before the periodontal phase, the tooth migrates later after the periodontal treatment is done, which might cause the occlusal failure of the restoration. In case the tooth is mobile during the restorative phase, it puts a lot of pressure on the mastication and function of the tooth. The various ways in which the restorative material affects the periodontal health is the position of the restoration, the material of the restoration, and the contour, which is followed during the restoration. Plaque retention is an important factor in the failure of the restoration, which can happen in the case of subgingival margins. If subgingival restorations are to be placed, the finish should be smooth, which reduces the chances of accumulation of plaque. Small flaps in the subgingival area can also be raised, which causes a better visual effect, good adaptation, and better access for finishing the restoration. For a good, esthetic restoration, not only the restoration and the restorative material are of utmost importance, but also a healthy periodontium gives a final natural-looking appearance to the restoration [3].

Biological considerations of the periodontium that need to be kept in mind while placing restorations

Biological width

It is defined as the dimension of the soft tissue that is attached to the portion of the tooth, which is coronally placed than the crest of the alveolar bone [4]. Gargiulo, *et al.* conducted a study with 287 teeth and concluded that the dimension of the alveolar crest, attachment of the epithelium, connective tissue attachment, and sulcus depth are all related and proportional to each other. He described the sulcus depth to be around 0.69 mm, connective tissue attachment to be 1.07 mm, which makes the biological width 2.04 mm (Figure 1). [5].

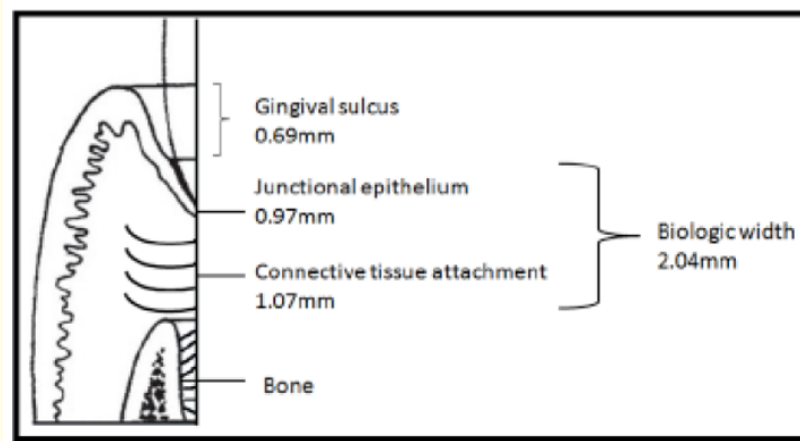


Figure 1: Biological width, which comprises of the dimension of connective tissue and junctional epithelium [5].

The main function of the biological width is to preserve the health of the periodontium by removing the foreign factors that can be injurious to the health of the periodontium. The biological width is not a constant number and varies from tooth to tooth according to their position in the alveolus. A 3 mm dimension between the margin of the restoration and alveolar bone helps in maintaining periodontal health for a period of 4 to 6months. The junctional epithelium, supracrestal connective tissue, and gingival sulcus are all roughly 1mm each [6]. In a study conducted by Nevin., *et al.* [7], they concluded that the biological width of a tooth should be maintained at every point, even while making impressions, and the subgingival extension of any crown should not go beyond 0.5 to 1 mm because it may affect the junctional epithelium. The margins of the restoration and crown, if placed, should not encroach upon the biological width as it causes gingival inflammation followed by loss of periodontal bone support. In a study conducted by Gunay., *et al.* [7] the study 41 patients and compared 116 prepared teeth with 82 normal teeth and concluded that whenever the margin of the restoration was placed in the biological width, it increased the periodontal bleeding index. Whenever a restorative margin has to be placed subgingivally, it is recommended to take the sulcus depth as the reference point. For this, the utmost important step is to maintain gingival health. In case infraclavicular margins are to be placed, the following rules should be followed (Table 1 to 3).

RULE 1	If the probing depth of the sulcus is 1.5mm or less, the margin of the restoration should be placed 0.5mm below the crest.
RULE 2	If the probing depth of the sulcus is greater than 1.5mm margin should be placed at half the distance of sulcus depth below the alveolar crest.
RULE 3	In case the sulcus depth is more than 2mm, then gingivectomy should be done to increase the sulcus depth to 1.5mm

Table 1: Rules to be followed in case restoration infraclavicular margin is placed [5].

Indications	Contraindications
1. The existing length of the crown is inadequate for the retention of the restorations.	1. Cases where the caries is very deep and excess bone removal are required.
2. In cases where the margins have to be placed subgingivally.	2. Teeth in which an inadequate crown root ratio is present.
3. When the existing gingival margins are not esthetic.	3. Teeth in which the chances of furcation involvement are high.
4. Restoration in which the biological width is violated.	4. If the adjacent alveolar bone is getting compromised.

Table 2: Indications and contraindications of crown lengthening [10].

Type	Characteristics	Technique
Type I	Soft tissue present is sufficient, which allows the excision of gingiva without disturbing the biological width.	Gingivectomy or gingivoplasty.
Type II	Soft tissue is sufficient to allow gingival excision without exposure of the alveolar crest, but the biological width is disturbed	Repositioning of the flap is done surgically, followed by osseous recontouring.
Type III	Excision of the gingiva exposes the alveolar crest	A surgical template should be made, which serves as a guide during flap repositioning, which helps in maintaining the bone levels during the surgery. Instead of apical repositioning, the flaps are positioned coronally.
Type IV	Excision of gingiva leads to loss of attached gingiva	Apical repositioning of flaps should be done.

Table 3: Classification of crown lengthening procedures [11].

Periodontal surgeries in operative dentistry

As discussed above, if the sulcus depth is not proper and the margin has to be placed intracervical, then doing a surgical crown lengthening to increase the length of the clinical crown has more advantages compared to the violation of biological width.

Surgical crown lengthening

Increasing the length of the clinical crown is referred to as crown lengthening. This procedure is of high importance in cases where there is a subgingival extension of the caries, fractures that are present sub gingivally, and in cases of chronic gingivitis occurring due to improper placement of restoration margins. Due to the increasing demand for esthetic restorations, the interdisciplinary approach of treatment has become more popular, which includes lengthening of the clinical crown in aesthetic zones [8]. Surgical crown lengthening basically involves recontouring of the gingival tissues around teeth to expose more clinical crowns which are healthy, thus giving a greater number of teeth to work on. Crown lengthening is generally done in cases where a crown must be placed, which provides enough space between the margins of the crown and the bone supporting the tooth. In cases where there is caries or fracture line below the gingival margin of the tooth, crown lengthening is required to do the procedure while maintaining the biological width [9]. The various indications and contraindications of crown lengthening are mentioned in the following table.

Various crown lengthening procedures:

External bevel gingivectomy

The soft tissue is excised like in gingivectomy. They can be used in cases where hyperplasia of gingiva or pseudopockets is present. One more prerequisite for this is the presence of adequate keratinized tissue (Figure 2 and 3).

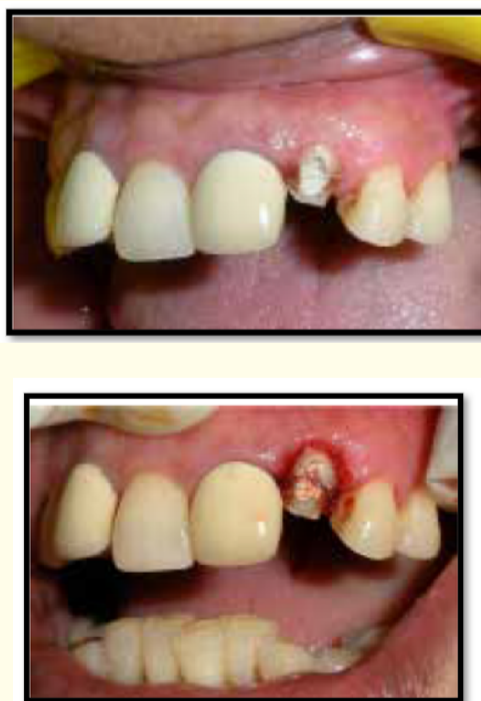

Figure 2: Crown lengthening procedure using external bevel gingivectomy [11].

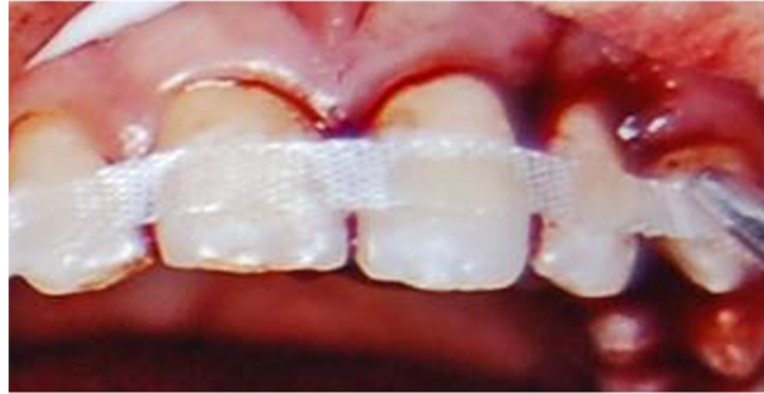

Figure 3: Fiber splinting of teeth done after trauma [16].

Apical repositioning of flaps

This procedure is generally done when the biotype of gingival tissue is thick; it is generally followed by contouring of bone. It helps in increasing the width of the attached gingiva and maintains the attached gingiva [10].

Classification of crown lengthening procedures

The crown lengthening procedures are further classified based on the position of alveolar bone.

Interproximal embrasure correction

The contact between two adjacent teeth mesially and distally is a very important factor in the success of a restoration. To maintain good periodontal health, the contact point of the tooth should be placed either incisively, buccally, or occlusally [12]. A normal bulk of gingival tissue is maintained by proper contact points and spacing between adjacent teeth. Open embrasures can be found in cases where the papilla is insufficient, or contacts are located too high in a coronal direction. To correct this, contact should be moved to the tip of the papilla. In order to do this, during the restorative phase, the margin of the restoration should be taken subgingivally 1.5 mm, and the contact point should be moved towards the papilla. To give a more natural-looking appearance of the teeth, embrasures should be left open as close embrasures give a square-shaped look to the teeth. The contact of the teeth should be equal in length, and papillary height should be managed accordingly. The papillary height of the tooth is determined by three factors, namely the level at which the interproximal bone is present, biological width dimensions, the shape of the gingival embrasure. In a study conducted by Tarnow, *et al.* [13], he concluded that the height of contact and level of papilla fill were connected in a way that the contact being 5 mm from bone, papilla always filled the space and as the height of contact kept increasing the papilla fill kept decreasing. At 6mm, it was 56%, and at 7 mm, just 27% [13].

Splinting

Splinting is generally carried out in teeth with increased mobility, where multiple teeth are combined together to increase the stability of the teeth. Increased mobility is generally seen in cases where there is the loss of periodontal support due to loss of bone, or in cases of trauma, or to increase the stability of pontics by splinting the abutments. Before the splinting procedure is carried out, the underlying disease causing the instability should be diagnosed and treated as persisting periodontal disease may increase the mobility [14]. Once

splinting is done, the occlusal force applied on the teeth is shared by all the teeth that have been splinted together, and hence the number of teeth to be splinted and the kind of splinting material should be chosen accordingly [15].

Root resection

Multi-rooted teeth always impose a more complex treatment plan compared to single-rooted teeth. In cases where furcation is involved in multi-rooted teeth, the most common course of treatment is the extraction of teeth, but the increased demand to save the teeth has given us various options like resection of the root, in which a part of the root of the tooth is removed with or without the crown portion. The various forms of resection of the root are:

1. Root Amputation- in these cases, the one or more root is removed from a multi-rooted tooth.
2. Hemisection- the root along with its crown portion is removed [17].
3. Bisection- a multirooted tooth is split into two, and both the portions are retained individually.

The important factor that should be kept in mind is that the occlusal contact should be maintained properly as improper occlusal contact may convert the normal mastication forces into destructive forces, which may lead to the failure of the reaction procedure [18]. Once the resection is done, restoration of the teeth is an important phase as the embrasure that is formed should be easily cleansable during oral hygiene with an interdental brush [19].

External root resorption

External resorption of the root is generally divided into three categories based on the etiology of the resorption. In cases of cervical root resorption, the case is not diagnosed until there is a co-existing periodontal or pulpal infection [19]. To treat external resorption, the treatment plan focuses on complete removal of the restorative tissues, following the resection of resorbed material, and endodontic treatment, if required, should be done. To remove the resorbed tissue, a surgical periodontal flap should be raised, followed by curettage and restoration of the resorbed area with the help of restorative materials like glass ionomer, composite resin. Although these materials are indicated for filling the resorptive area, due to handling difficulties, they are not currently used. The most successful material used for the restoration of the resorptive area of the root has been suggested as ProRoot MTA [20].

Conclusion

The ultimate goal of any dental treatment is to maintain the natural dentition in its actual form. Any restorative phase should always be preceded by periodontal treatment. For a long term survival of any restoration, the restorative and periodontal phase should always be in harmony. Management of the gingival tissue is of high importance as it decides whether the prosthesis that is fabricated is properly fitting. A preoperative interdisciplinary management plan of the tooth is of utmost importance before going on with any particular treatment as the sequence in which the treatment should be done greatly affects the outcome of the treatment.

Bibliography

1. Patel S. "The inter-relationship between restorative dentistry and periodontology". *Saudi Dental Journal* 11.3 (1999): 124-133.
2. Glickman I. "Clinical Periodontology 8th edition". Philadelphia: WB Saunders Co (1996).
3. Waerhaug J. "The gingival pocket; anatomy, pathology, deepening and elimination". *Odontologisk Tidskrift* 60.1 (1952): 1.

4. Gargiulo AW, *et al.* "Dimensions and relations of the dentogingival junction in humans". *The Journal of Periodontology* 32.3 (1961): 261-267.
5. Puri K, *et al.* "Restorative aspects of periodontal disease: an update part 1". *Dental Update* 41.6 (2014): 545-552.
6. Jorgić-Srdjak K, *et al.* "Periodontal and prosthetic aspect of biological width part I: Violation of biologic width". *Acta stomatologica Croatica* 34.2 (2000): 195-197.
7. Günay H, *et al.* "Placement of the preparation line and periodontal health--a prospective 2-year clinical study". *The International Journal of Periodontics and Restorative Dentistry* 20.2 (2000): 171.
8. Lee EA. "Aesthetic crown lengthening: classification, biologic rationale, and treatment planning considerations". *Practical Procedures and Aesthetic Dentistry* 16.10 (2004): 769-778.
9. Prabhakar Rao K V, *et al.* "Aesthetic Crown Lengthening". *Annals and Essences of Dentistry* 2.4 (2010).
10. Nugala B, *et al.* "Biologic width and its importance in periodontal and restorative dentistry". *Journal of Conservative Dentistry: JCD* 15.1 (2012): 12.
11. Puri N, *et al.* "Restorative aspects of periodontal disease: an update part 2". *Dental Update* 41.7 (2014): 638-652.
12. Ash MM and Nelson SJ. "Wheeler's dental anatomy, physiology, and occlusion [CD] (2003).
13. Tarnow DP, *et al.* "The effect of the distance from the contact point to the crest of bone on the presence or absence of the interproximal dental papilla". *Journal of Periodontology* 63.12 (1992): 995-996.
14. Jamal S, *et al.* "Narrative Review Conventional and contemporary approaches of splinting traumatized teeth: A review article". *Narrative* 70.2 (2020).
15. Spear FM and Cooney JP. "Periodontal-restorative interrelationships. Newman MG, Takei HH, Carranza FA. Carranza's clinical periodontology". 9th edition. by: WB Saunders, Philadelphia (2002): 950.
16. Kahler B, *et al.* "Splinting of teeth following trauma: a review and a new splinting recommendation". *Australian Dental Journal* 61 (2016): 59-73.
17. Bhosale M, *et al.* "Molar Hemisection in Teeth with Advanced Furcation Lesion: A Hope for the Hopeless". *Asian Journal of Dental Sciences* (2020): 9-13.
18. Gonzales JR and Rodekirchen H. "Endodontic and periodontal treatment of an external cervical resorption". *Oral Surgery, Oral Medicine, Oral Pathology, Oral Radiology, and Endodontology* 104.1 (2007): e70-e77.
19. Spear FM. "Interdisciplinary esthetic management of anterior gingival embrasures". *Advanced Esthetics and Interdisciplinary Dentistry* 2 (2006): 20-28.
20. Jebiril A, *et al.* "The Surgical Management of External Cervical Resorption: A Retrospective Observational Study of Treatment Outcomes and Classifications". *Journal of Endodontics* (2020).

Volume 20 Issue 1 January 2021

All rights reserved by Mohamed Hany Ahmad Abd Elghany, *et al.*