

Innovative “IPG-DET Technique” Combined with Autologous CGF with Stem Cells CD34+ for the Rehabilitation of the Posterior Atrophic Maxilla

Vasileios Ntontoulos^{1,2*}, Francesco Inchingolo^{1,2}, Stavros Tsantis³, Eleni Salvaridou^{1,2}, Tasos Kotsavasiliadis^{1,2}, Dritan Gazioni^{1,2}, Panagiotis G Georgakopoulos², Triantafyllio Zafeiri^{1,2}, Ioannis Meletis^{1,2}, Maria Zournatzi^{1,2} and Ioannis P Georgakopoulos^{1,2}

¹Department of Interdisciplinary Medicine, School of Medicine, University of Bari “Aldo Moro”, Bari, Italy

²World Academy of Growth Factors and Stem Cells in Dentistry, Athens, Greece

³Department of Medical Physics, School of Medicine, University of Patras, Rion, Greece

***Corresponding Author:** Vasileios Ntontoulos, Department of Interdisciplinary Medicine, School of Medicine, University of Bari “Aldo Moro”, Bari, Italy and World Academy of Growth Factors and Stem Cells in Dentistry, Athens, Greece.

Received: July 23, 2020; **Published:** August 29, 2020

Abstract

A partially edentulous patient with bilateral atrophic posterior maxilla ranging from 1 to 7 mm residual bone height below the sinus cavity, has been treated performing minimally invasive surgery under a certain new protocol with simultaneous placement of five (5) implants.

Contrast to traditional utilization of Sinus Floor Elevation (Crestal or Lateral approach without perforating the Schneiderian membrane), this innovative protocol - named “IPG-DET Technique” - introduces the sinus membrane intentional perforation as an alternative. The intentional perforation (flapless or not) combined with an autologous biomaterial (CGF-CD34+Matrix), an alloplastic bone grafting material followed by immediate implantation into the sinus has been proven a safe and stable solution with long-term prognosis. A pair of Cone Beam Computed Tomography images taken before and with (8) months post-surgery have shown significant new bone formation around the implants placed with the “IPG-DET Technique”.

The proposed method results simple, safe, less painful and cost-effective solution that may change completely the conventional treatment plan and strategy for the exact position and the procedure used to place implants in the posterior region of the maxilla, especially in cases of severe atrophy and sinus pneumatization.

Keywords: Maxillary Sinus; Bone Augmentation; IPG-DET Technique; Flapless Surgery; Dental Implants; Sinus Membrane Intentional Perforation; Concentrated Growth Factors; CD34- Positive Stem Cells

Abbreviations

SFE: Sinus Floor Elevation; CGF: Concentrated Growth Factors; CD34+: CD34-Positive Stem Cells; LPCGF: Liquid Phase of the Concentrated Growth Factors; CBCT: Cone Beam Computed Tomography; ISQ: Implant Stability Quotient; RFA: Resonance Frequency Analysis

Citation: Vasileios Ntontoulos., *et al.* “Innovative “IPG-DET Technique” Combined with Autologous CGF with Stem Cells CD34+ for the Rehabilitation of the Posterior Atrophic Maxilla”. *EC Dental Science* 19.9 (2020): 119-126.

Introduction

In prosthetic dentistry, the use of dental implants has been established nowadays as the primary treatment option [1] in the majority of partially and/or completely edentate patients [2,3]. However, in several situations of bone resorption after tooth extraction, especially for the compromised but also challenging regions of the anterior and posterior maxilla, the dimensions of the residual crest, usually limit the placement of the implants. In such demanding cases, throughout treatment procedure, hard-soft tissue grafting procedures like guided bone and tissue regeneration (GBR and GTR), bone transplantation, etc. or all of them simultaneously, are necessary in order to achieve adequate implant stability and long-term aesthetic results [4].

Regarding posterior maxilla and its deficiencies, SFE (Sinus Floor Elevation) is the prevailing procedure for over 40 years [5]. However, as a side effect maxillary sinusitis has been reported to occur in 8 - 20% of patients after sinus floor augmentation [6]. The latter along with other complications may be interrelated and divided into intraoperative and postoperative events, such as Schneiderian membrane perforation 23.5 - 41%, wound infections, abscesses, drainage, dehiscence, graft exposure, overfill of the elevated sinus and loss of graft, bleeding and facial haematoma, implant exposure or displacement, oroantral communication, pain, vertigo [7] etc. The high incidence of sinus membrane perforation could be an advantage by means of a novel protocol named “IPG-DET Technique” [8-10] which introduces the immediate placement of implants in the sinus cavity with intentional perforation of the sinus membrane by simultaneously employing concentrated growth factors (CGF with stem cells CD34+) and bone grafting, contrary to SFE procedure. Implants can be placed immediately by utilizing flapless (recommended by authors), or surgical approach. CGF protocol with stem cells CD34+ [11] and platelet-rich plasma (PRP) in orthopaedic and dental bone regeneration surgeries has shown the ability to release several autologous growth factors by means of activated platelets [12].

Throughout this study, five (5) implants were placed by a minimally invasive surgery flapless technique named “IPG-DET Technique” in both sinuses on the same patient. After a 5-month healing period, radiographic (Panoramic X-Ray scans) and clinical evaluation (Implant Stability Quotient - ISQ measurement, by Ostell) have shown excellent implant stability.

Materials and Methods

A 45-years old partially edentulous female patient, with bilateral atrophic posterior maxilla ranging from 1 to 7 mm residual bone height (Figure 1 up), non-smoker, without a medical history, visited the Dentist Education Institute postgraduate center in Athens - Greece, requesting fixed prosthetic rehabilitation.

After patient’s consent, it was decided to place five (5) MultySystem (Italy) implants (2 implants - flapless-delayed 4,2/10 mm at regions #26, #27 on the left side and 3 implants - immediate 3,7/11,5 mm at #15 and 4,2/10 mm at #16, flapless-delayed 4,2/10 mm at region #17 on the right side) in both posterior regions (Figure 1 down), by using the novel minimally invasive protocol IPG-DET Technique.

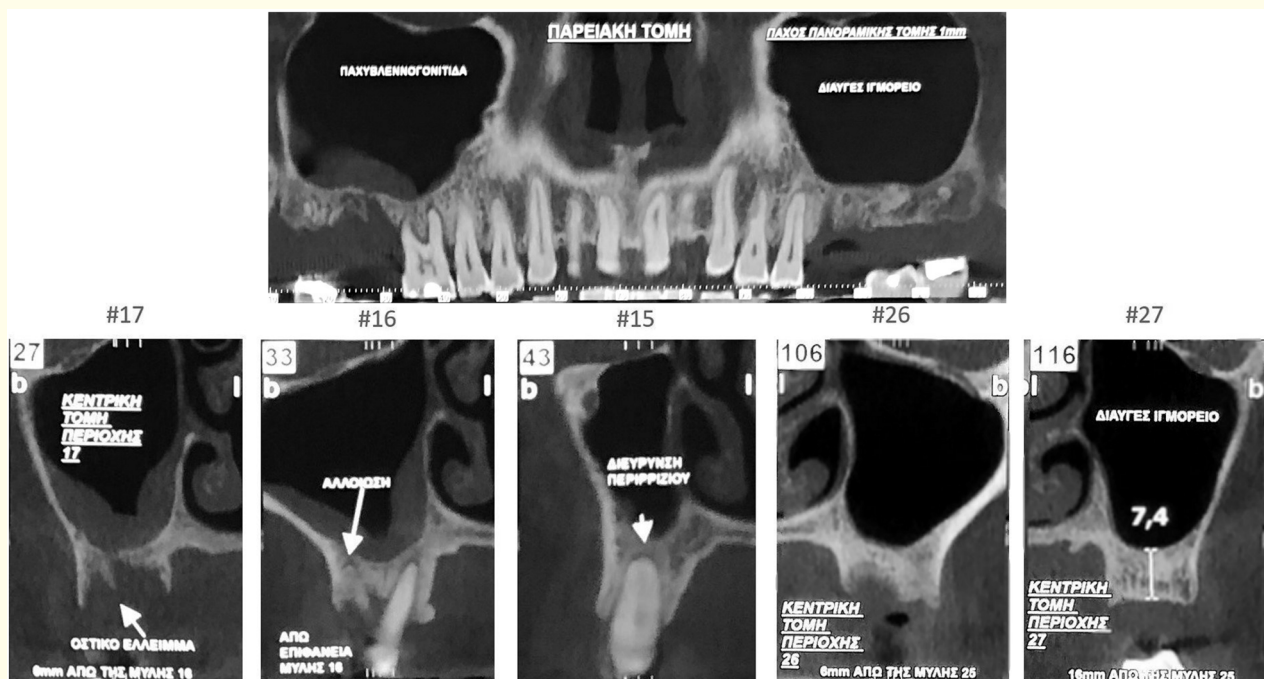


Figure 1: Diagnostic X-ray evaluation before surgery with panoramic view (up) and each single implant position cut (down) of initial CBCT.

At first, blood has been drawn from the patient using eight 9 ml sterile tubes (Figure 2a). These tubes were placed immediately into the cell separation device, Medifuge (Silfradent, Italy) (Figure 2b), according to the CGF protocol [11], for a 13-minute cycle.

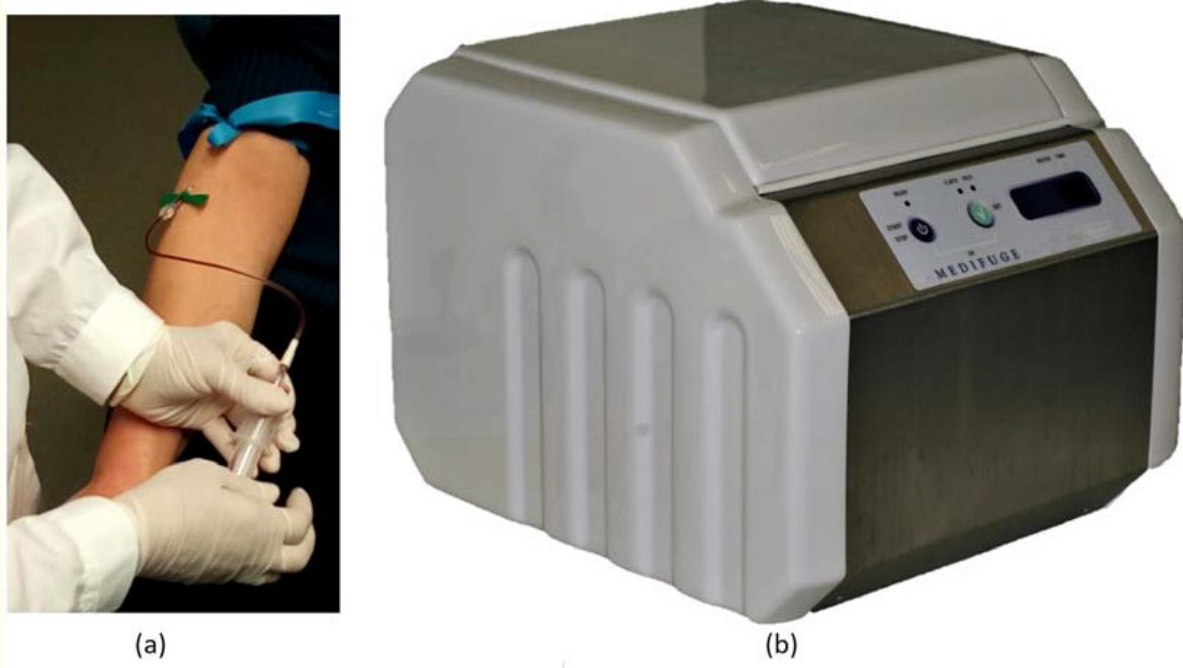


Figure 2: (a) Blood collection and (b) Centrifugation.

At the end of centrifugation (Figure 3a), three blood fractions were formed: (1) the upper platelet poor plasma (PPP) layer; (2) the middle fibrin-rich gel with aggregated platelets and concentrated growth factors (CGF); and (3) the lower red blood cell (RBC) layer [13]. As regards the middle layer throughout contemporary literature there is a distinction between the very large and dense polymerized fibrin buffy coat on top and the liquid phase containing the white blood cells on the bottom of the previous phase [14]. A large number of growth factors and stem cells CD34+ are aggregated in this middle layer between the dense polymerized fibrin buffy coat and the upper 3 - 4 mm of red blood corpuscles mass of the bottom layer (Figure 3b).

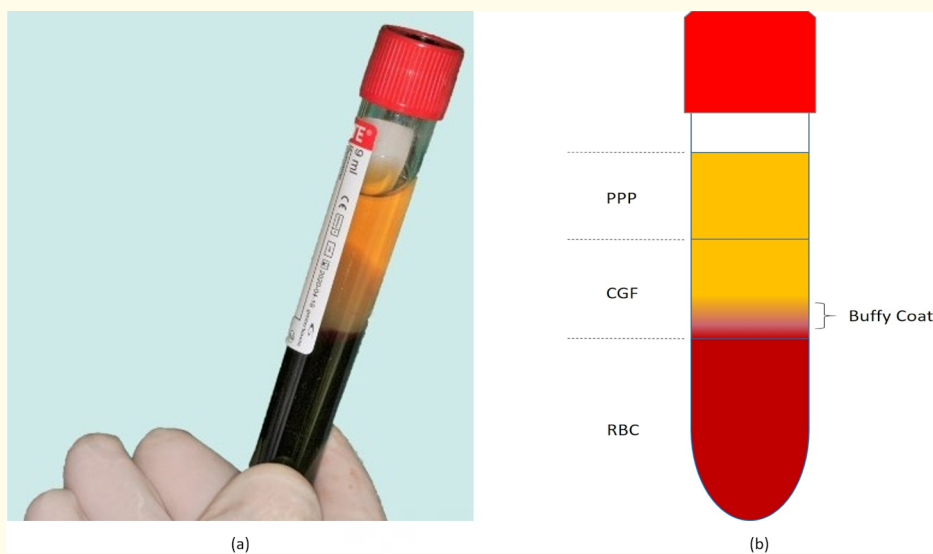


Figure 3: (a) Tubes after centrifugation and (b) Blood fractions PPP - CGF - RBC.

This growth factor-rich segment was appropriate for our purpose and was separated from the rest of the red corpuscles using scissors in order to obtain the CGF-CD34+ matrix” [8-10] (Figure 4a and 4b).




Figure 4: (a) Separation with scissors from RBC layer in order to acquire (b) CGF-CD34+ matrix.

The osteotomy was extended through the full bone height available. Drilling was made with the initial drill (2,1 drill), followed by Duravit bone compactor - expanders with a diameter of 3 and 3,5 (B & B, Italy) until intentional perforation of the sinus membrane. A CGF matrix was inserted through the osteotomy site and membrane perforation into the sinus, using a fibrin injector (Silfradent, Italy). Another CGF matrix (highly concentrated growth factors and stem cells) was then cut into small pieces and mixed with a small quantity of the alloplastic bone grafting material Combioss (0.5 ml, by Silfradent-Italy). This mixture is then placed within the osteotomy site. Before placement of each implant in the osteotomy site, it was first carefully and completely immersed into the LPCGF (liquid phase concentrated growth factors) in order to create a “bio-energetic membrane” around the implant. The LPCGF was prepared by squeezing one CGF matrix using the CGF forceps (Silfradent, Italy) and was collected in a sterilized container for immersion of all implants. The implants were then placed using a hand wrench and the insertion torque value was measured to be between 25 Ncm² and 30 Ncm², both on the right (Figure 5a-5c) and on the left side (Figure 5d-5f).

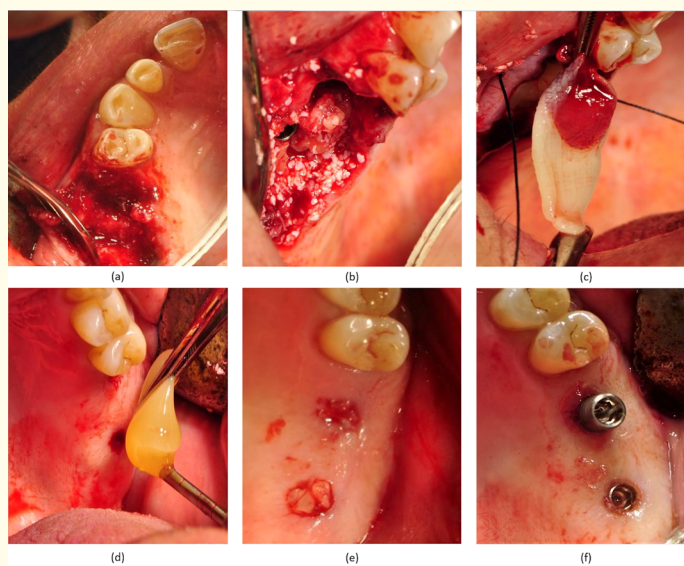


Figure 5: Clinical photos during surgery from right side-surgical approach (a), (b), (c) and left side-flapless approach (d), (e), (f).

Results

Panoramic X-rays immediately after surgery (Figure 6 up), and 5 months post-op implant placement (Figure 6 down), following the proposed clinical protocol, have shown new bone formation around the implants, while full osseointegration of all implants has been revealed during second stage when uncovering and placement of healing abutments.

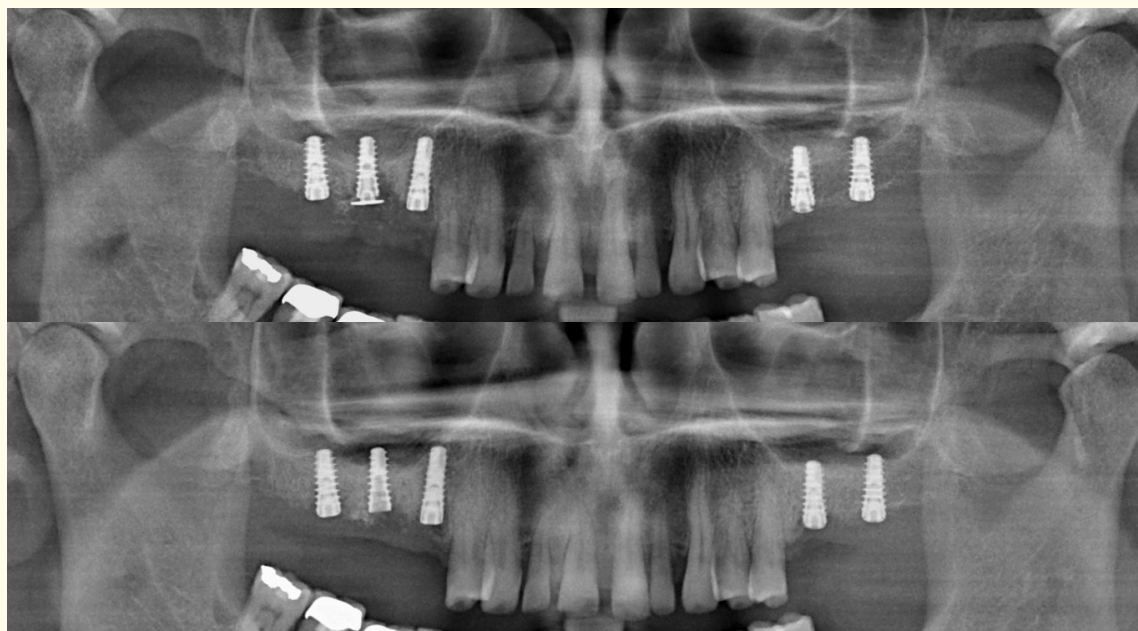


Figure 6: OPG X-rays from (up) the day of surgery and (down) after a five-month healing period showing osseointegration of all 5 implants.

None of the patients’ sinuses presented any complications or infection postoperatively. Immediately after implant placement, the primary stability of each implant was measured by means of Resonance Frequency Analysis (RFA) using the Osstell device [15]. For all five implants placed using the IPG-Dentist Edu technique, the ISQ values ranged between 60 and 69, which shows high primary stability for all implants placed, till final prosthetic rehabilitation, 11 months after implant placement, followed by a CBCT 3d Imaging both in panoramic (Figure 7) and single view for each of all five implants (Figure 8).

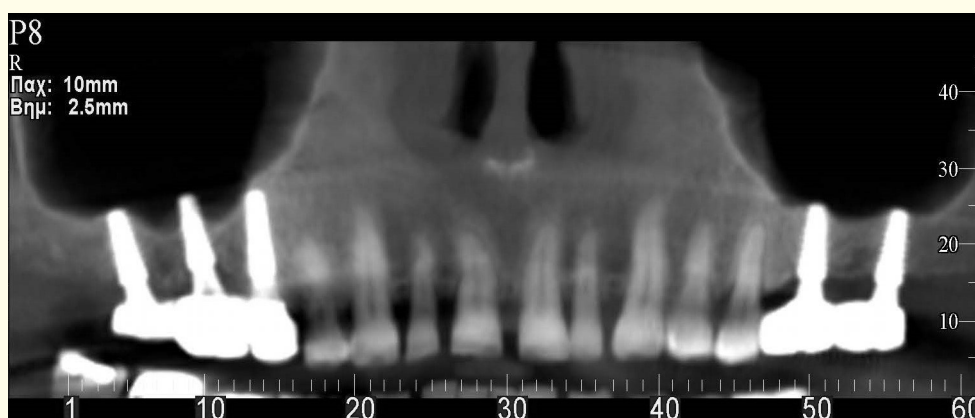


Figure 7: Panoramic view of final CBCT.

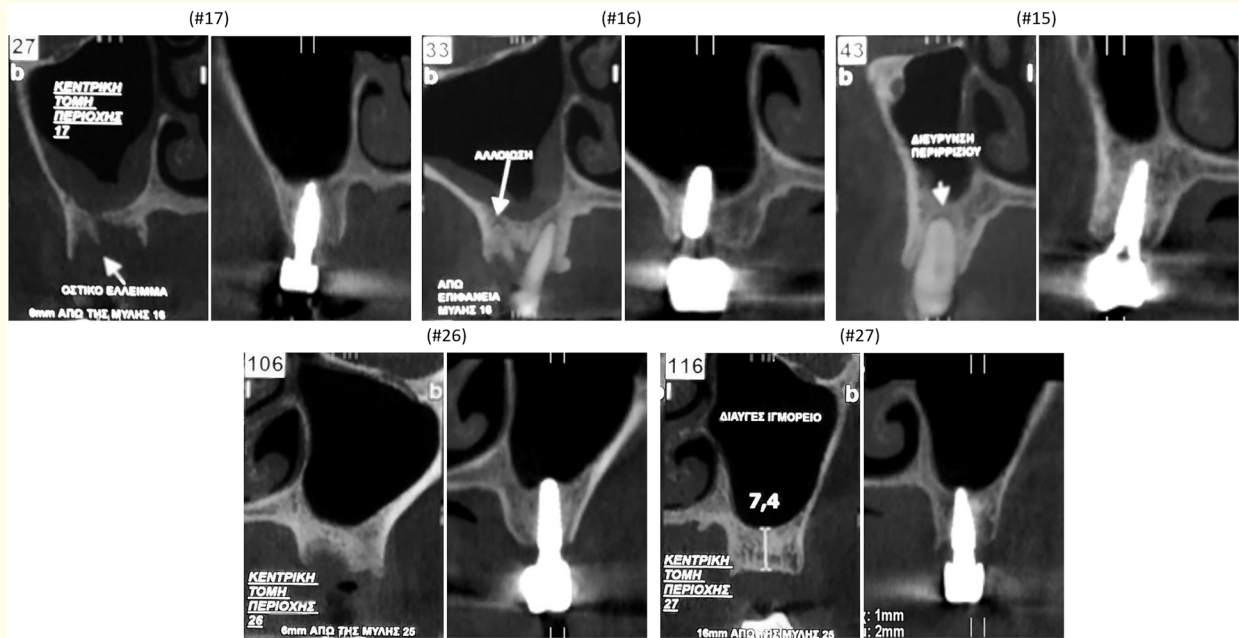


Figure 8: Initial and final CBCT cuts for each position of all 5 implants.

Discussion

Tooth loss consequences are usually the alveolar crest’s volume resorption and reduction in all dimensions (horizontal and vertical). Especially in compromised cases, in order to retrieve the appropriate amount of bone for prosthetic implant rehabilitation, regenerative techniques need to be done, such as GBR, GTR, etc. The aim is to ensure the best possible outcome with regard to functionality, aesthetics and predictability of the final implant-supported prostheses.

The posterior edentulous maxilla is one of the most challenging oral regions for implant rehabilitation. Anatomical features as the maxillary sinus pneumatization [16], low spongy bone’s density class “IV” and/or class “V”, are considered as serious difficulties during surgery etc. The prevailing method for the posterior maxilla, known as SFE-“Sinus Floor Elevation” or SAT-“Sinus Augmentation Technique” (crestal approach-Indirect SAT and lateral approach- Direct SAT) [17], is a very important and demanding surgical procedure depending on operator’s experience, skills and techniques. It is also quite expensive, time-consuming (one or more steps), generally painful and with several other complications. Of course, SFE is a widespread and documented technique of high predictability for over 40 years, with the average survival rate of implants being 92.6% [18], proposed as the only solution for posterior maxilla deficiencies.

The IPG-DET Technique is probably a reliable alternative to SFE, as it involves the use of the autologous bio-material CGFCD34+ Matrix (Concentrated Growth Factors, CD34-Positive Stem Cells found in the CGF at the top 3 mm to 4 mm of the blood aggregate of the tube and CGF matrix) together with bone grafting material into the intentionally perforated sinus membranes in order to allow implant placement in the sinuses atraumatically. The implementation of IPG-DET Technique, after patient’s consent, is based on a specific protocol and prerequisite training for this technique. It has shown complete absence of any post-op complication (e.g. pain, inflammation), probably due to the “like after any trauma” anchorage mechanism of the CGF matrix (containing enabled platelets with pseudo-legs) and its insertion

in the sinus through the intentional perforation combined with also enabled platelets from the membrane hemorrhage. Fibrin clot's high cohesion is due to fibrinogen, factor XIII and thrombin agglutination. The factor XIIIa is activated by thrombin that causes fibrin to clot. The latter provides protection from plasmin degradation resulting in higher fibrin tensile strength and stability [19]. In addition, fibrin promotes fibroblasts and osteoblasts proliferation, uneventful bone graft embodiment and revascularization, delaying at the same time any bacteria infiltration [20]. The presence of CGF matrix around (and above) the “sticky” bone graft surrounding the implant fixture into the sinus cavity, provides stability and cohesion to this “block” by excluding any displacement possibility.

As it can be observed on cone-beam computed tomography images (Figure 8) in all five (5) implant positions, before and after IPG-DET protocol, a “new” sinus floor has been reconstructed due to bone development bilaterally and above implants with an apparent increase of alveolar crest bone volume.

Prior to new bone formation from the graft after a period of 6 - 8 months, a new sinus membrane will slowly cover this block, while the old one will be slowly disintegrated, and very often certain previous sinus pathology cannot be detected anymore (Figure 8 #17, #16). Further studies with inclusion of a bigger number of patients and longer documentation periods are in process in order to establish the long-term implant stability and to quantify the new bone formation into the sinus cavity.

Conclusion

The use of minimally invasive IPG-DET Technique as an innovative protocol towards implant treatment for the posterior maxilla deficiencies can provide a reliable alternative to the well-established SFE procedure, which nevertheless presents drawbacks and complications.

Conflict of Interest

None.

Bibliography

1. Buser, *et al.* “Modern implant dentistry based on osseointegration: 50 years of progress, current trends and open questions”. *Periodontology 2000* 73 (2017): 7-21.
2. Feine JS, *et al.* “The McGill consensus statement on overdentures. Mandibular two-implant overdentures as first choice standard of care for edentulous patients. Montreal, Quebec, May 24-25”. *The International Journal of Oral and Maxillofacial Implants* 17.4 (2002): 601-602.
3. Thomason JM, *et al.* “Mandibular two implant-supported overdentures as the first choice standard of care for edentulous patients-the York Consensus Statement”. *British Dental Journal* 207 (2009): 185-186.
4. Buser D, *et al.* “Optimizing esthetics for implant restorations in the anterior maxilla: anatomic and surgical considerations”. *The International Journal of Oral and Maxillofacial Implants* 19 (2004): 43-61.
5. Boyne P and James RA. “Grafting of the maxillary sinus floor with autogenous marrow and bone”. *Journal of Oral and Maxillofacial Surgery* 17 (1980): 113-116.
6. Eun Seok Jang, *et al.* “A Case of Maxillary Sinusitis after Sinus Floor Augmentation”. *Korean J Otorhinolaryngol-Head and Neck Surgery* 53 (2010): 310-312.
7. Paul Fugazzotto, *et al.* “Complications When Augmenting the Posterior Maxilla”. *Dental Clinics of North America* 59 (2015): 101-126.

8. Ioannis Georgakopoulos, *et al.* “A Case-Study of Seven Dental Implants Placed in the Maxillary Sinus with Intentional Schneiderian Membrane Perforation”. *The Journal of Implant and Advanced Clinical Dentistry* 6.1 (2014): 9-19.
9. Georgakopoulos PI, *et al.* “IPG-DET Minimal Invasive Sinus Implant Placement and Grafting without Sinus Floor Elevation - The Evolution of New Age Concepts”. *Dentistry* 6 (2016): 375.
10. Panagiotis I Georgakopoulos, *et al.* “The IPG-DET Technique: Innovative Approach of Implant Placement and Grafting in the Sinus”. *Dental News* 26.1 (2019): 12-19.
11. Sacco L Lecture. In: International Academy of Implant Prosthesis and Osteoconnection (2006).
12. G Intini. “The use of platelet-rich plasma in bone reconstruction therapy”. *Biomaterials* 30 (2009): 4956- 4966.
13. LF Rodella, *et al.* “Growth Factors, CD34 Positive Cells, and Fibrin Network Analysis in Concentrated Growth Factors Fraction”. *Microscopy Research and Technique* 74.8 (2011): 772-777.
14. Sohn DS, *et al.* “Bone regeneration in the maxillary sinus using an autologous fibrin-rich block with concentrated growth factors alone”. *Implant Dentistry* 20.5 (2011): 389-395.
15. Sennerby L and Meredith N. “Implant stability measurements using resonance frequency analysis: biological and biomechanical aspects and clinical implications”. *Periodontology 2000* 47 (2008): 51-66.
16. Sudhakiran Kalavagunta and KTV Reddy. “Extensive maxillary sinus pneumatization”. *Rhinology* 41 (2003): 113-117.
17. SM Balaji. “Direct v/s Indirect sinus lift in maxillary dental implants”. *Annals of Maxillofacial Surgery* 3.2 (2013): 148-149.
18. Stephen S Wallace and Stuart J Froum. “Effect of Maxillary Sinus Augmentation on the Survival of Endosseous Dental Implants. A Systematic Review”. *Annals of Periodontology* 8 (2003): 328-343.
19. Bernardi S, *et al.* “Histological characterization of Sacco’s concentrated growth factors membrane”. *International Journal of Morphology* 35.1 (2017): 114-119.
20. Tayapongsak P, *et al.* “Autologous fibrin adhesive in mandibular reconstruction with particulate cancellous bone and marrow”. *Journal of Oral and Maxillofacial Surgery* 52.2 (1994): 161-165.

Volume 19 Issue 9 September 2020

© All rights reserved by Vasileios Ntontoulos, *et al.*