

A Simple Innovative Technique for Fabrication of a 3-D Cast Guided Surgical Template for Dental Implant Placement Using Conventional Radiographic Techniques

Swapnil B Shankargouda^{1*}, Preena Sidhu², Harini KS³, Smitha Sharan⁴, Sounyala Rayannavar⁵, Sonica Miyyapuram⁶

¹Senior Lecturer, Department of Prosthodontics and Crown and Bridge, KLE Academy of Higher Education and Research's Vishwanath Katti Institute of Dental Sciences, Belagavi, Karnataka, India

²Senior Lecturer, Faculty of Medicine and Health, International Medical University, Kuala Lumpur, Malaysia

³Assistant Professor, Department of Oral Maxillofacial Rehabilitation, Qassim Private Dental College, Mustaqbul University, Buraidah, Saudi Arabia

⁴Reader, Department of Prosthodontics and Crown and Bridge, Dayananda Sagar College of Dental Sciences, Bangalore, Karnataka, India

⁵Reader, Department of Prosthodontics and Crown and Bridge, KLE Academy of Higher Education and Research's Vishwanath Katti Institute of Dental Sciences, Belagavi, Karnataka, India

⁶Undergraduate, KLE Academy of Higher Education and Research's Vishwanath Katti Institute of Dental Sciences, Belagavi, Karnataka, India

***Corresponding Author:** Swapnil B Shankargouda, Senior Lecturer, Department of Prosthodontics and Crown and Bridge, KLE Academy of Higher Education and Research's Vishwanath Katti Institute of Dental Sciences, Belagavi, Karnataka, India.

Received: May 15, 2020; **Published:** May 27, 2020

DOI: 10.31080/ecde.2020.19.01445

Abstract

In order to determine the correct three dimensional position of the dental implant, three axes should be considered separately, namely mesiodistal plane, buccolingual plane and the length of the implant from the top of the implant to the apex from the prosthetic table. To determine and confirm the planned position of the implant sites, radiographic techniques using intraoral periapical radiograph and occlusal radiograph can be used, which can be equivalent to the accuracy and efficacy of a computer-guided implant placement using 3D planning software. Thus, a 3-D cast-based guided implant surgery with confirmation using conventional radiographic techniques allows for the precise placement of dental implants.

Keywords: Dental Implants; Presurgical Planning; Intraoral Radiography; Guided Surgery

Introduction

Meticulous planning and careful surgical procedures are of prime importance for placing optimally aligned dental implants to achieve a bone anchored osseointegrated implant [1]. Prosthetic failures may occur due to misaligned implants, particularly in replacement with multiple implants. Surgical templates have been used to aid in placement of prosthetically driven implants worldwide. Different types of surgical template fabrication techniques are available in the literature [2]. Primarily, acrylic resins along with or without vacuum-formed matrix have been used for the fabrication of the radiographic/surgical template for implant placement [3,4]. The commonly used radiographic techniques such as intraoral periapical and panoramic radiography are easily accessible but due to its inability to record the buccolingual cross section of the bone and image distortion, it is not used routinely. Instead the width of the residual alveolar ridge can

Citation: Swapnil B Shankargouda., et al. "A Simple Innovative Technique for Fabrication of a 3-D Cast Guided Surgical Template for Dental Implant Placement Using Conventional Radiographic Techniques". *EC Dental Science* 19.6 (2020): 112-119.

be determined using ridge mapping/bone mapping [5-7]. So, the present study describes a simple technique for 3 dimensional implant placement and confirmation using conventional radiographic technique and surgical template.

Procedure

1. Make a diagnostic cast in type III dental stone and duplicate the cast to receive 2 sets of cast for radiographic template fabrication and bone mapping.
2. Evaluate the mesiodistal space, occlusal plane and interocclusal space of the proposed implant site and fabricate a diagnostic radiographic stent using autopolymerizing acrylic resin covering the proposed edentulous implant site with a 5 mm metal bearing in place.
3. Make a panoramic radiograph with the stent worn by the patient to confirm the proposed implant position and to measure the magnification quotient of the radiograph to determine the exact apicocoronal position of the implant, as shown in figure 1.
4. Intraoral bone mapping of the proposed implant site is done using ridge mapping callipers/needle with stoppers by penetrating it through the soft tissues. The mucosal thickness is measured and data is recorded.
5. The duplicate cast is prepared for die pin placement and die retrieval for bone mapping using dual die pins placed adjacent to edentulous region of the proposed implant site. Die cutting is done in the middle of the edentulous region of the proposed implant site and sectioned perpendicular to the ridge and a second cut two teeth away, for retrieval of the dies anterior and posterior to the proposed implant site, as shown in figure 2 and observed for ridge thickness.
6. The soft tissue measurements recorded from the bone mapping of the proposed implant site in the patient's mouth are transferred onto the retrieved die of the cast to delineate the available bone.
7. Ridge midline is marked occlusally and buccolingually over the sectioned cast, as shown in figure 3.
8. Secure the sectioned die on the surveyor to determine the angulation of the desired implant. The paralleling tool is secured on the surveyor arm such that it coincides with the pencil marked midline buccolingually by tilting the cast, as shown in figure 4.
9. After determining the tilt and the desired angulation, tripodding of the cast is done to maintain the same tilt and a hole is drilled using the milling machine into the secured sectioned segments, thus determining the final angulation for the desired implant placement in a mesiodistal and buccolingual direction, as shown in figure 5.
10. A 2 mm metal pin with a metal sleeve is placed into the drill hole to provide a channel for the initial osteotomy and a hard surgical splint is fabricated using clear acrylic resin, as shown in figure 6.
11. The surgical template is worn by the patient firmly onto the tissues and intraoral periapical radiograph and occlusal radiograph of the desired site is made to confirm the mesiodistal positioning, as shown in figure 7 and buccolingual positioning of proposed implant in figure 8.
12. On successful placement of the implant using the surgical template, verification of the 3-dimensional placement of the implant can be done using the periapical radiograph and occlusal radiograph.

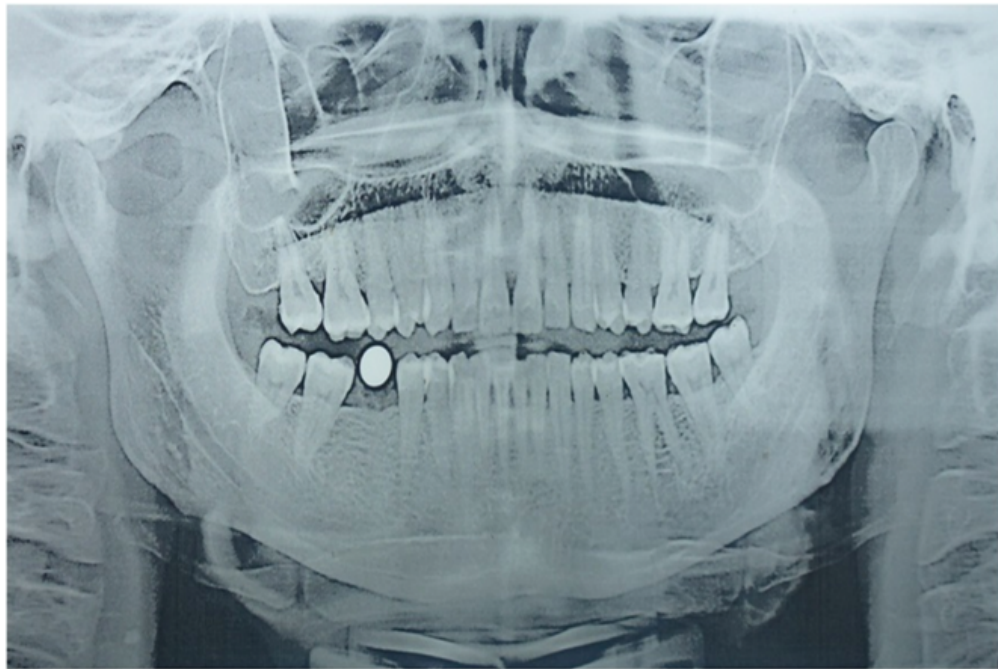


Figure 1: Panoramic radiograph showing metal bearing in proposed implant site.

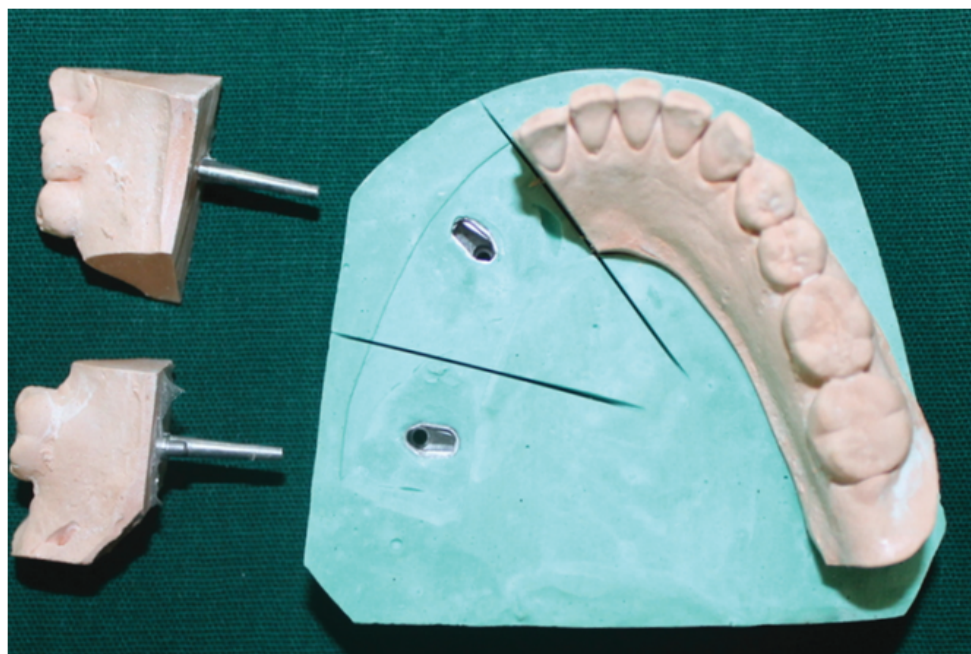


Figure 2: Retrieval of individual dies to study the ridge thickness after die cutting of the proposed implant site.

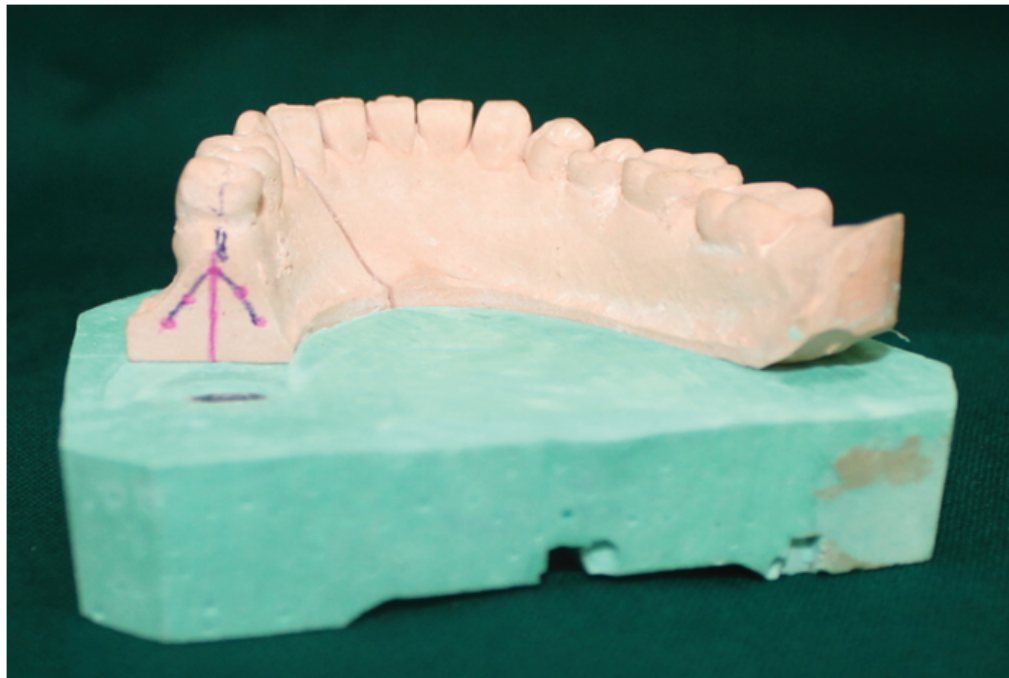


Figure 3: Ridge midline marked occlusally and buccolingually onto the sectioned die.




Figure 4: Milling machine used to drill hole in the proposed implant site at the predetermined angulation on the sectioned die.

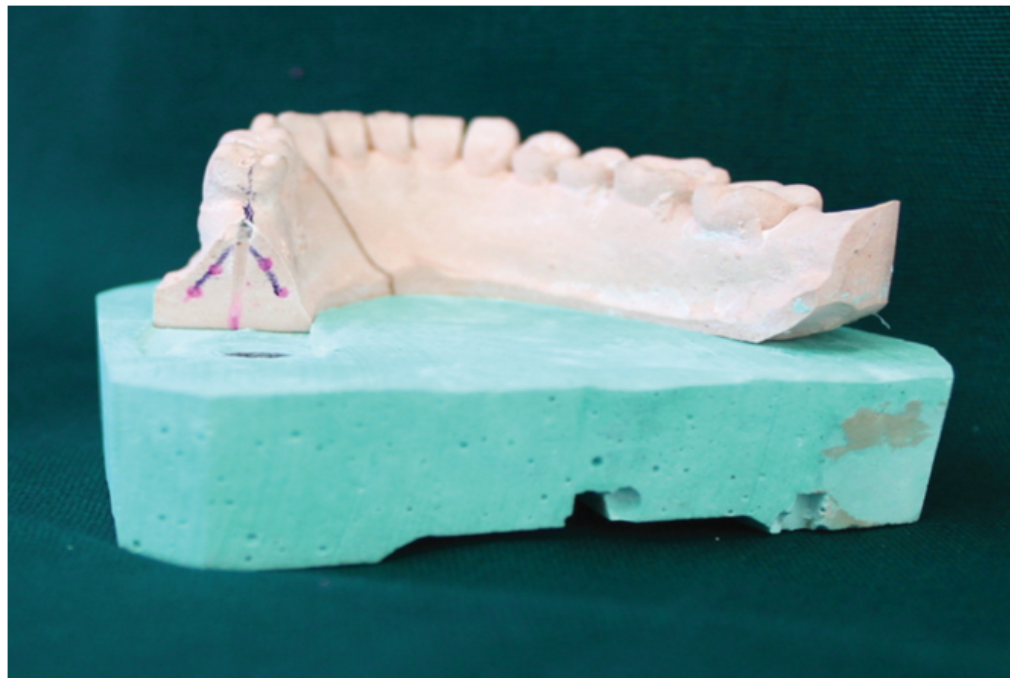


Figure 5: Sectioned die showing drill hole of the final angulation for the proposed implant.

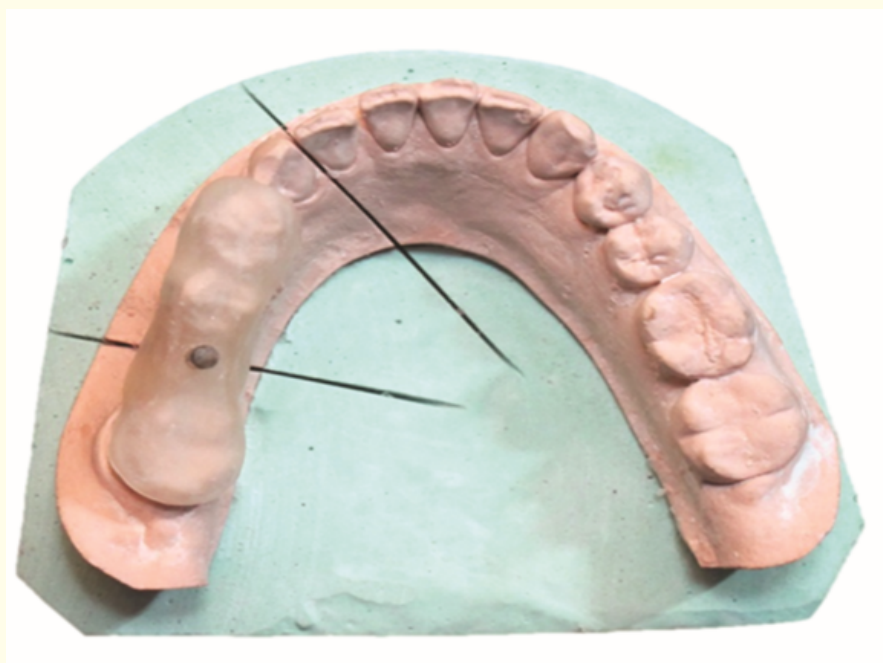


Figure 6: 2 mm metal pin showing buccolingual and mesiodistal orientation of the proposed implant.

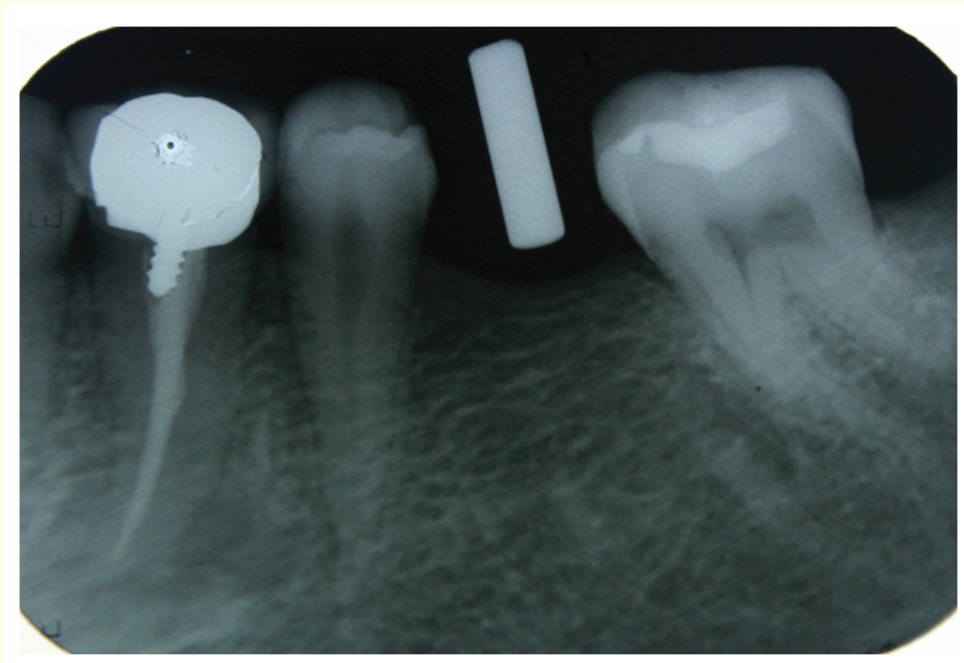


Figure 7: Intraoral periapical radiograph showing mesiodistal position of the proposed implant placement in the patient's mouth.

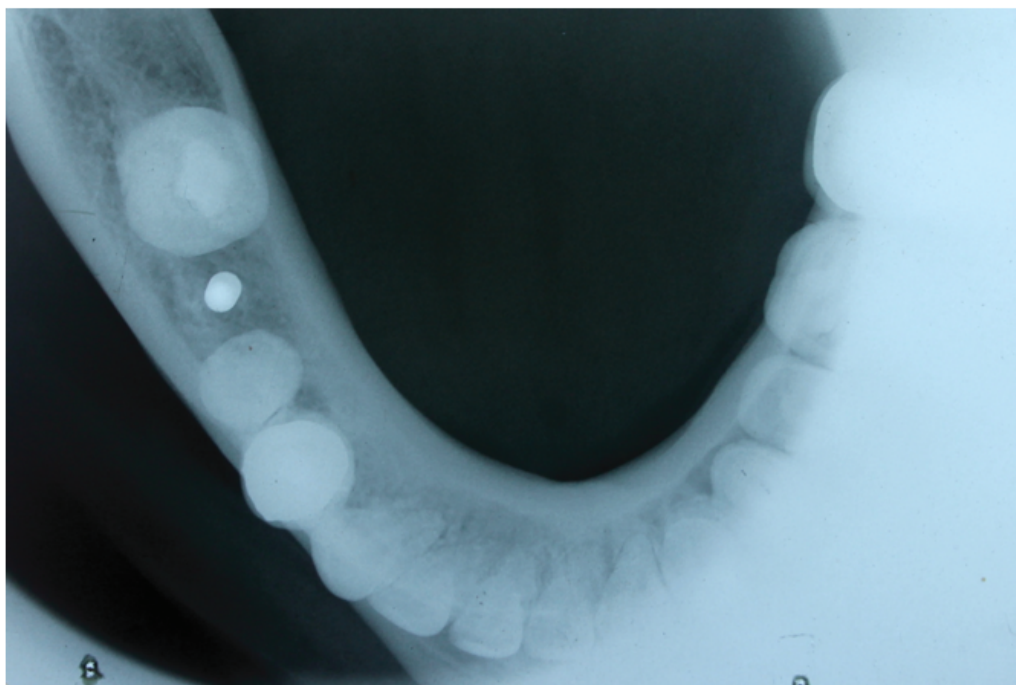


Figure 8: Occlusal radiograph showing buccolingual position of the proposed implant placement in the patient's mouth.

Discussion

This article describes a simple innovative technique for fabrication of a 3 dimensional cast guided surgical stent using conventional radiographic techniques and bone mapping that can be used for flap/flapless implant surgery.

Advantages of the present technique:

- Uses conventional diagnostic and radiographic technique.
- No special equipment required, so cost effective.
- Simple to fabricate and avoids over exposure to radiation.
- Can be used to fabricate surgical stents for completely edentulous arches.
- A series of measurements of the proposed implant site can be made prior to reflection of a mucoperiosteal flap.

Limitations of the present technique:

- Technique sensitive procedure and can be used efficiently for unilateral cases than bilateral cases.
- Requires advanced tomographic imaging for completely edentulous cases.
- Overestimation/underestimation of the mucosal thickness during bone mapping, especially in the maxillary posterior and palatal mucosa due to the varying mucosal thickness and thin cortical plates.

Clinical relevance

Scientific rationale for study

In this digital era, various digital technologies and techniques like computed tomography, cone beam computed tomography etc. are used for dental implant placement. However, its high cost and feasibility, necessitates for a more simple, cost effective and easily available technique, which provides nearly similar results.

Principal findings

The present technique is convenient and reliable for assessing suitability of potential implant sites, using conventional radiographic and diagnostic techniques, although CBCT, CT, 3DCT etc remain the gold standard.

Practical implications

The technique described in the article can be used in conventional flapless cast guided implant surgery that is minimally invasive.

Conclusion

Although the technique used in this article is simple and effective in cases of partially edentulous cases, further research and modification has to be carried out to the technique for effective use in completely edentulous cases and use of better flexible materials can be used to fabricate the surgical template to further simplify the procedure.

Conflict of Interest

None.

Bibliography

1. Basten CH and Kois JC. "The use of barium sulphate for implant templates". *Journal of Prosthetic Dentistry* 76.4 (1996): 451-454.
2. Meitner SW and Tallents RH. "Surgical templates for prosthetically guided implant placement". *Journal of Prosthetic Dentistry* 92.6 (2004): 569-574.
3. Shotwell JL, *et al.* "Implant surgical guide fabrication for partially edentulous patients". *Journal of Prosthetic Dentistry* 93.3 (2005): 294-297.
4. Allen F and Smith DG. "An assessment of the accuracy of ridge-mapping in planning implant therapy for the anterior maxilla". *Clinical Oral Implants Research* 11.1 (2000): 34-38.
5. Becker CM and Kaiser DA. "Surgical guide for dental implant placement". *Journal of Prosthetic Dentistry* 83.2 (2000): 248-251.
6. Perumal P, *et al.* "Abridged Technique for Precise Implant Angulation". *Journal of Clinical and Diagnostic Research* 9.12 (2015): ZD09-ZD11.
7. Stumpel LJ. "Cast-based guided implant placement: a novel technique". *Journal of Prosthetic Dentistry* 100.1 (2008): 61-69.

Volume 19 Issue 6 June 2020

©All rights reserved by Swapnil B Shankargouda., *et al.*