

## **A Review of Direct Pulp Capping: New Treatment Approaches and Modalities**

**Nilotpol Kashyap\***

*Professor and HOD, Department of Pedodontics and Preventive Dentistry, Chitwan Medical College, School of Dentistry, Bharatpur, Nepal*

**\*Corresponding Author:** Nilotpol Kashyap, Professor and HOD, Department of Pedodontics and Preventive Dentistry, Chitwan Medical College, School of Dentistry, Bharatpur, Nepal.

**Received:** December 05, 2019; **Published:** January 29, 2020

### **Abstract**

Direct Pulp Capping has been defined by Kopel as the placement of a medicament or non-medicated material on a pulp that has been exposed in course of excavating the last portions of deep dentinal caries or as a result of trauma. While DPC can be performed in both primary or permanent teeth, generally the procedure is considered controversial in case of the use of calcium hydroxide which can cause internal resorption of primary teeth. Due to the availability of newer materials in modern times other than calcium hydroxide the concept of DPC in primary teeth is changing. This article takes a look at the concept, procedure and controversies surrounding DPC and the newer materials available for performing the procedure.

**Keywords:** *Direct Pulp Capping (DPC); Calcium Hydroxide; Primary Teeth*

### **Introduction**

Direct Pulp Capping or DPC has been defined by Kopel (1992) as the placement of a medicament or non-medicated material on a pulp that has been exposed in course of excavating the last portions of deep dentinal caries or as a result of trauma [1].

### **Direct pulp capping in primary teeth**

According to the AAPD guideline (1991), DPC is performed in a primary tooth when a pinpoint exposure of the pulp is encountered during cavity preparation or following a traumatic injury, a biocompatible radiopaque base such as MTA or Calcium hydroxide may be placed in contact with the exposed pulp tissue [2]. The tooth is then restored with a material that seals the tooth from micro leakage.

### **Rationale of direct pulp capping in primary teeth**

To encourage the formation of a dentin bridge at the point of pulpal exposure with preservation of pulpal health and vitality.

### **Indication of direct pulp capping in primary teeth**

The procedure is indicated in primary tooth with a normal pulp following a small mechanical or traumatic exposure when condition for a favourable response is optimal.

### **Contraindications of direct pulp capping in primary teeth**

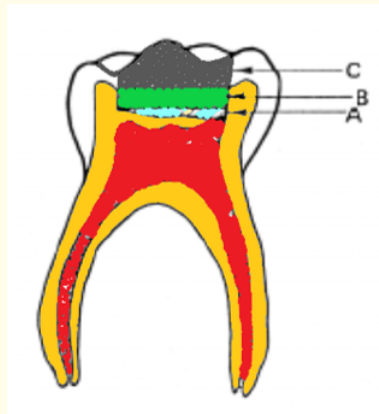
Direct Pulp Capping of a carious pulp exposure in a primary tooth is not recommended.

### **Objectives of direct pulp capping teeth in primary teeth**

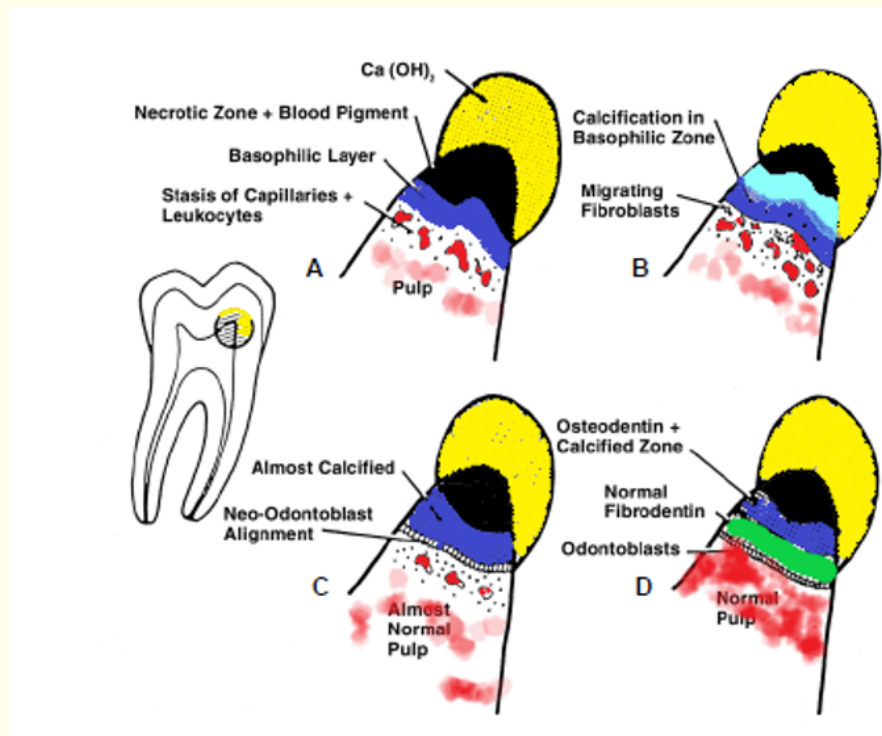
- The tooth's vitality should be maintained.

- No post treatment signs and symptoms such as sensitivity, pain, and swelling should be evident.
- Pulp healing and reparative dentin formation should result.
- There should be no radiographic signs of pathologic external or progressive internal root resorption or furcation/apical radiolucency.
- There should be no harm to succedaneous tooth.

**Procedure of direct pulp capping in primary teeth (Figure 1 and 2)**



**Figure 1:** Showing direct pulp capping (A) medicament applied for direct pulp capping, (B) base and (C) restorative material.



**Figure 2:** Showing mechanism of action of direct pulp capping procedure.

According to HD Rodd, the technique of DPC in primary teeth is as follows [3]:

- The tooth is anesthetized.
- Optimal isolation with rubber dam is done.
- Gentle application of cotton pledget soaked in water/normal saline to control any pulpal haemorrhage.
- Application of hard setting calcium hydroxide or MTA over the exposure site.
- Definitive restoration to achieve external coronal seal is done ideally with an adhesive restoration or preformed crown.

### Controversies of direct pulp capping in primary teeth

According to Monty S, Duggal and Hani Nazzal, direct pulp capping should not be considered in primary teeth where removal of all caries has resulted in pulp exposure the reason is that it has been shown that inflammation of the pulp in primary teeth precedes the exposure of pulp [4]. Due to the wide dentinal tubules in primary molars, bacteria penetrate the pulp before it is clinically exposed. Inflammation is usually too extensive for healing to occur with pulp capping and inflamed pulp needs to be removed before restoring the tooth. The only situation where pulp capping should be considered in primary teeth is where pulp exposure is traumatic and not due to caries.

Direct pulp capping for primary teeth is one of the most controversial treatment in pulp therapy. Calcium hydroxide is not recommended routinely for primary teeth because it creates a zone of chronic inflammation under the dentinal bridge and causes the undifferentiated mesenchyme cells to differentiate into osteoclasts, which cause internal resorption and creates a porous (tunnelling effect) dentinal bridge, which in turn creates a pathway for micro leakage. Nowadays due to the advent of newer biocompatible materials such as MTA, BMP etc., researchers have seen that the prognosis of DPC is getting better. Recent research reveals that DPC with MTA have a success rate of 95% - 100%.

Nina Milcheva (2016) presented a protocol where direct pulp capping was done using MTA in primary teeth with large carious lesion without any history of spontaneous pain [5].

### Treatment considerations while performing DPC in primary teeth

**Case selection:** The most important criteria for a successful DPC is case selection. The etiology of the exposure whether cariogenic, iatrogenic, traumatic, etc. plays an important role in prognosis. Seltzer and Bender (1973) proposed that DPC should only be done in cases where pulp exposure was due to mechanical or traumatic reasons. As a carious exposure will invariably result in microbial contamination and exposure of the pulp [6]. The AAPD guidelines (2014) on pulp therapy for primary teeth also proposed that DPC should be done in primary teeth with pinpoint exposure of the pulp due to iatrogenic and traumatic insults and not in a primary tooth exposed by caries.

However, other researchers like Nina Milcheva (2016) suggests that DPC can be done to treat any teeth with minimal or no signs of pulpal inflammation [5].

**Size of the pulp exposure:** Studies have shown and provided guidelines that only a pinpoint exposure (less than 1 mm) of the pulp can be capped as it prevents ingress of bacteria. Researchers also suggested that limiting width of the exposure to less than 1 mm is mandatory as availability of odontoblast like cells remain limited and larger exposure cause greater debris impaction [7].

However, some authors have pointed that intentionally widening the pinpoint exposure resulted in removal of the inflamed pulp remnants as well as carious dentin which may be inadvertently pushed into the pulp chamber. Thus, it can be concluded that the size of the

pulp exposure is immaterial as long as an infallible capping procedure is undertaken. DPC should not be intended in case of pulp exposure on the axial wall as pulp tissue coronal to the axial exposure could not benefit from the therapeutic properties of the capping materials.

**Debridement:** Care should be taken while excavating carious dentin near the exposure site. Only peripheral mass of carious dentin should be excavated and never at the exposure site. If excavation is carried out too close to the exposure site, it may result in carious dentin chips in to the pulp chamber which might lead to pulpal inflammation and treatment failure.

**Haemorrhage and clotting:** Success of DPC procedure is also determined by the quality of the haemorrhage from the exposure site. If the bleeding is uncontrollable, it is a sign of irreversible pulpitis and endodontic therapy is needed. The presence of purulent discharge or absence of any bleeding indicates pulpal necrosis.

DPC should be undertaken only when bleeding from the exposure site is bright red in colour and can be controlled using a moist cotton pellet. Various solutions can be used to soak the cotton pellet such as chlorhexidine, sodium hypochlorite, hydrogen peroxide, ferrous sulphate, calcium hydroxide solutions and octenidine. Histological studies have shown that saline and calcium hydroxide solutions are the least cytotoxic.

Preventing clot formation is also one of the most important factor in the prognosis of DPC therapy. Clot formation is followed by haemolysis of erythrocytes which provide substrate for the bacterial proliferation and in turn hinders pulp healing. Tertiary dentinogenesis occurs when there is tight contact between the pulp and the capping material.

**Bacterial contamination:** An aseptic environment is needed for a good treatment outcome. Researchers have found that it is bacterial contamination which hinders tertiary dentinogenesis. They have also concluded that microleakage and bacterial contamination rather than toxicity of the capping material are responsible for pulpal inflammation. Hence an optimal coronal seal is needed to prevent microleakage and bacterial contamination after direct pulp capping.

### Clinical protocol (Given by Nina Milcheva, Rossitza Kabaktchieva, Natalia Guteva: 2016) for DPC with MTA in primary teeth [5]

1. Indications: reversible pulpitis.
2. Diagnostic criteria:
  - Subjective:
    - Primary tooth with large carious lesion.
    - No history of past or present spontaneous/night pain.
    - Possible provoked pain by chewing which goes away after removal of the irritant.
  - Objective:
    - Visually a primary tooth with large carious lesion.
    - No visually observed communication with the pulp.
    - No pathological mobility or pain by percussion.
    - No swallow, redness, sinus tract or abscess in the surrounding soft tissues.

- Radiographic criteria: Periapical or Bitewing X-ray
  - Deep Carious lesion close to the pulp horn or it may seem that there is no dentin barrier
  - Lack of pathological resorption in fur cal and apical regions
  - Lack of pathological external or internal root resorption
  - Physiological resorption no more than 1/3 of the normal root length
- 3. Direct pulp capping “step by step”
  - Local anaesthesia.
  - Isolation (rubber dam).
  - Excavation of the infected/carious dentin from the cavity walls, especially dentin-enamel junction with round bur/ spoon excavator till reaching healthy dentin- it lights up in green with caries detector; when cleaning the pulp wall before reaching the moment to control the excavation process with caries detector the pulp is opened; the anaesthesia allows us to have a good control on cleaning the infected dentin which is obligatory for applying direct pulp capping method.
  - Pulp exposure (till 1 mm in diameter) is cleaned with physiological solution.
  - Control of bleeding should be done in 1 - 2 minutes.
  - Pulp exposure is covered with MTA.
  - The pulp capping material (MTA) is covered with glass ionomer cement.
  - The cavity is finished with aesthetic restoration.
- 4. Follow up period:
  - Control check-ups are scheduled for 6 months, 1 year and 2 years after treatment.
  - Clinical criteria for success:
    - Lack of pain.
    - Lack of fractures of the obturation or secondary caries around the edges.
    - Lack of swelling, redness, fistula or abscess of the surrounding soft tissues.
    - Lack of pathological mobility of the tooth.
  - Radiographic criteria for success:

- Presence of formed reparative dentin (calcifying fibrous bridge) on the side of the communication with the pulp (if there is no evidence for formed tertiary dentin the case is not classified as a failure).
- Normally continuing physiological root resorption.
- Lack of pathological external or internal root resorption.
- Lack of pathological changes in furcal or periapical regions.

### Direct pulp capping in permanent tooth

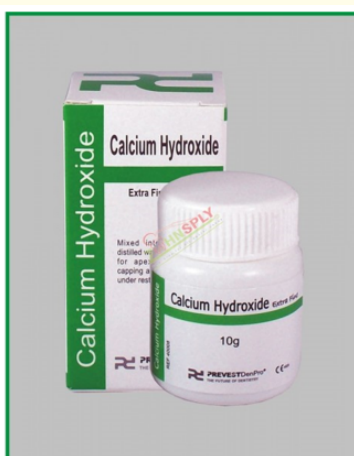The rationale, indications, contraindications and objectives of DPC in permanent teeth are same as that of primary teeth.

### Techniques of direct pulp capping in permanent teeth

- Tooth is anesthetized and isolated with rubber dam.
- Caries is excavated with a spoon excavator or a slow rotary handpiece.
- If there is an exposure while removing caries, further excavation is avoided.
- The exposure site is irrigated with normal saline or chlorhexidine.
- Bleeding is arrested by applying light pressure with a cotton pellet moistened with normal saline.
- The pulp capping material is applied on the exposed pulp with application of minimal pressure.
- A temporary restoration is placed over the capping material.
- A final restoration is done after determining the success of pulp capping by radiographic evidence of dentinal bridge formation and lack of pain or minimal inflammatory response.

### Materials used for direct pulp capping

#### Calcium hydroxide (Figure 3) [8]

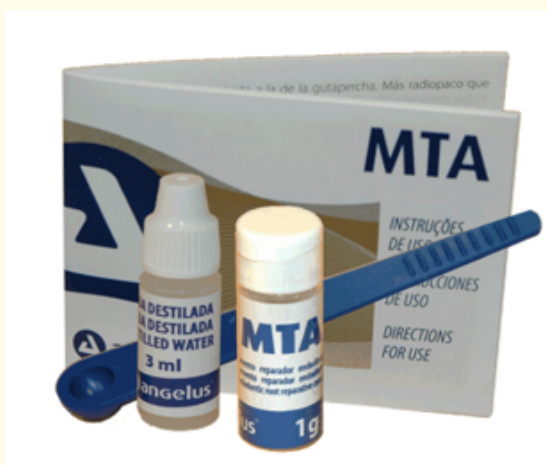

**Figure 3:** Calcium hydroxide.

Calcium hydroxide has been regarded as the “gold standard” for pulp capping. In 1930 Herman showed that calcium hydroxide induces the formation of new dentin when placed in contact with human pulp tissue. Estrela, *et al.* (1998) have demonstrated the antibacterial activities of calcium hydroxide, which include the ability to hydrolyse bacterial cell wall, neutralize bacterial endotoxin and diminish anaerobic organism via CO<sub>2</sub> absorption. Several studies have shown the success of calcium hydroxide capping in primary teeth and reported 100% success rate. Kopel had stated that the success of conventional calcium hydroxide capping can be enhanced by disinfecting the exposure site using antiseptic solutions.

Despite all its benefits calcium hydroxide has got many shortcomings when used as direct pulp capping materials. One of its major disadvantages is internal resorption. In case of deciduous teeth even before the actual time for exfoliation, there is an inherent predilection for the formation of odontoclast. The pre-existing propensity for transformation could be influenced and hastened by the placement of calcium hydroxide probably through its high alkalinity. It is very likely that the high alkaline pH of calcium hydroxide could trigger existing pre-odontoblast (stromal undifferentiated mesenchymal cells) to transform into odontoclast which causes internal resorption. Several studies have also shown that the dentinal bridge formed after calcium hydroxide pulp capping showed tunnel defects which can result in ingress the bacteria into the pulp space, thus causing further pulpal inflammation. Due to the introduction of newer material the use of calcium hydroxide for direct pulp capping has been almost discontinued.

### Mineral trioxide aggregate (MTA) (Figure 4)



**Figure 4:** MTA.

As a member of hydraulic calcium silicate cements MTA was introduced by Lee, *et al.* and patented by Torabinejad in 1995 [9]. It is composed of tricalcium silicate, bismuth oxide, tetra calcium alumina ferrite and calcium sulphates dehydrate. When MTA is mixed with water a colloidal gel with a pH of 12.5 similar to that of calcium hydroxide. MTA in contact with pulp tissue promotes dentinal bridge formation. In a study done by R Caicedo (2008), the author conclude that the responses of pulps in primary teeth to MTA pulpotomies and capping were favourable and that MTA can be used as Direct Pulp Capping material [10]. The disadvantages of MTA are its long setting time and its price.

### Biodentine (Figure 5) [11]



**Figure 5:** Biodentine.

Biodentine (Septodont Ltd., Saint Maur des Fausses, France) is a new tricalcium silicate ( $\text{CaSiO}_3$ ) based inorganic restorative commercial cement and advertised as “Bioactive dentin substitute”. Biodentine is a powder-liquid system where the powder is composed of tricalcium silicate, calcium carbonate, zirconium oxide, calcium oxide, dicalcium silicate, and iron oxide. The liquid is a solution of a hydro-soluble polymer with calcium chloride. Biodentine has better handling and physical properties than MTA. In studies done by Shayegan in primary pig teeth, Biodentine was found to be a suitable material for pulpotomy and DPC.

**Calcium enriched mixture (CEM) (Figure 6) [12]**



**Figure 6:** CEM.



CEM cement was introduced as an endodontic filling material the major component of the cement are calcium oxide, sulphur trioxide, phosphorous peroxide and silicon dioxide. CEM cements are biocompatible and the physical properties of the cement such as flow and setting in an aqueous environment are favourable. It has antibacterial activity and it also induces hydroxyapatite formation. Ghajari MF, *et al.* 2010 in their study found no significant difference between CEM and MTA in direct pulp capping success rate. They also found there was no internal resorption in primary teeth capped with CEM.

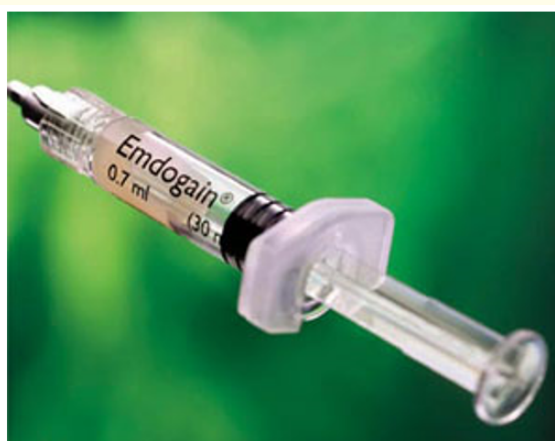**Nanohydroxyapatite (NHA) (Figure 7) [13]**



**Figure 7: NHA.**

Hydroxyapatite has already been used in bone grafts in orthopaedic and dental applications due to its structural similarity to bone and teeth. Recently a fully synthetic nanocrystalline hydroxyapatite (NHA) paste containing approximately 65% water and 35 and apatite particles has been introduced. The advantage of this material is its close contact with surrounding tissue and the presence of high number of molecules on its surface due to its nanocrystalline structure. The biocompatibility of NHA, combined with its structural similarity to teeth allows NHA to stimulate odontoblast thus promoting the formation of dentinal bridge. Shayegan (2010) in a study found NHA to be biocompatible and observed that it provoked mild inflammatory reaction in pulp tissue when used in pulpotomies and pulp capping. Haghghoo R, *et al.* (2015) in a randomized trial comparing the histological effects of CEM and NHA cements when used as pulp capping material found CEM to be superior to NHA in rate of tertiary dentin formation and also in pulpal inflammation.

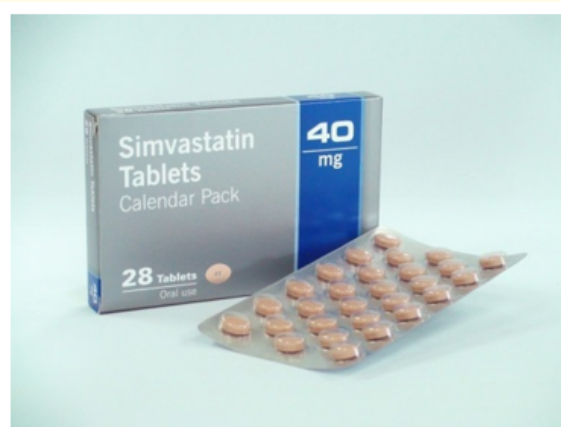**Enamel matrix derivative (EMD) (Figure 8) [14]**



**Figure 8: EMD.**

EMD (Emdogain) is an extract derived from porcine foetal tooth material and mainly consist of amelogenins, a class of protein known to induce proliferation of PDL cells. The ability of EMD to facilitate the regenerative process is well established. EMD by means of which amelogenins and amelin rich fraction has the potential to induce a process that seems to imitate normal dentinogenesis. It influences odontoblasts and endothelial cells of the pulpal capillary vessels to create a calcified barrier over the exposure site when used as a direct pulp capping material. Olsson H (2005) reported EMD to fare better than calcium hydroxide when used as a pulp capping material and it also had superior dentinal bridge formation capacity.

### Simvastatin (3Mixtatin) (Figure 9) [15]



**Figure 9:** Simvastatin.

Statins are structural analogs of HMG-CoA- (3-hydroxyl-3-methylglutaryl-CoenzymeA). These drugs are the first line for hyperlipidemia. Statin has multiple functions, including anti inflammation, induction of angiogenesis and bone formation. Simvastatin has anabolic effects on bone metabolism they promote mineralization in non-mineralizing osteoblasts through induction of BMP-2 and osteocalcin.

### Conclusion

3Mixstatin is a combination of 3Mix antibiotic paste with Simvastatin this mix provides the necessary requisites for regeneration and repair of pulp, which includes antibacterial properties from the antibiotic paste and anti-inflammatory/angiogenic properties of simvastatin. Aminabadi NS (2016) concluded in his study that although the material promoted pulp healing and hard tissue formation, it did so at a lower rate than calcium hydroxide.

### Bibliography

1. Kopel HM. "Considerations for the direct pulp capping procedure in primary teeth: a review of the literature". *ASDC Journal of Dentistry for Children* 59.2 (1992): 141-149.
2. American Academy of Pediatric Dentistry. "Guideline on pulp therapy for primary and immature permanent teeth". *Pediatric Dentistry* 37.6 (2015): 244-252.
3. Rodd HD., et al. "UK National Clinical guidelines in pediatric dentistry". *International Journal of Paediatric Dentistry* 16 (2006): 15-23.

4. Monty S, Duggal, Hani Nazzal.
5. Milcheva N., *et al.* "Direct pulp capping in treatment of reversible pulpitis in primary teeth- Clinical protocol". *Journal of IMAB* 22.4 (2016): 1348-1351.
6. Seltzer Bender IB. "Pulp capping and pulpotomy". In: Seltzer S, Bender IB, editors. *The dental pulp*. 3<sup>rd</sup> Ed. Philadelphia: JB. Lippincott Company (1984): 281-302.
7. Sujlana A and Pannu PK. "Direct pulp capping: A treatment option in primary teeth?" *Pediatric Dental Journal* 27 (2016): 1-7.
8. Estrella C., *et al.* "In-vitro determinations of direct antimicrobial effect of calcium hydroxide". *Journal of Endodontics* 24.1 (1998): 15-17.
9. Torabinejad M., *et al.* "Cytotoxicity of four root end filling materials". *Journal of Endodontics* 21.10 (1995): 489-492.
10. Caidedo R., *et al.* "Clinical, radiographic and histological analysis of the effects of Mineral Trioxide Aggregate in direct pulp capping and pulpotomies in primary teeth". *Australian Dental Journal* 51.4 (2006): 297-305.
11. Shayegan A., *et al.* "Biodentin used as a pulp-capping material in primary pig teeth". *Pediatric Dentistry* 34.7 (2013): e202-e208.
12. Ghajari MF, *et al.* "Direct pulp-capping with calcium enriched mixture in primary molar teeth: a randomized clinical trial". *Iranian Endodontic Journal* 5.1 (2010): 27-30.
13. Haghgoo R., *et al.* "Nano-hydroxyapatite and a calcium enriched cement for pulp capping of sound primary teeth: a randomized clinical trial". *Iranian Endodontic Journal* 102 (2015): 107-111.
14. Davies JR., *et al.* "Dental pulp capping: effect of Emdogain gel on experimental exposed human pulps". *International Endodontic Journal* 38.3 (2005): 189-194.
15. Aminabadi NS., *et al.* "Simvastatin versus calcium hydroxide direct pulp capping of human primary molars: a randomized clinical trial". *Journal of Dental Research, Dental Clinics, Dental Prospects* 7.1 (2013): 8-14.

**Volume 19 Issue 2 February 2020**

**© All rights reserved by Nilotpol Kashyap.**